

Effect Of Prolonged Administration Of Aqueous And Methanol Leaf Extracts Of Vitex Doniana And Bombax Buonopense On The Activities Of Liver Enzymes Of Albino Rats.

Nweke, Odinachi Lynda

Department Of Medical Biochemistry, Ebonyi State University, Abakaliki

Abstract

Samples of *Vitex doniana* and *Bombax buonopense* leaf were collected from Abakaliki metropolis. The edible portion were washed, dried, ground into powder and fed Albino rats for 21 days at different concentration ranging from 100, 200, 400 and 800mg/kg body weight of the Albino rats. Thereafter, the level of liver enzymes: AST, ALP, ALT and 5'-Nucleotidase were measured using standard procedures and histological analysis of the hepatic tissue was also conducted. From the analysis the administration of the aqueous and methanol leaf extracts of *Vitex doniana* and *Bombax buonopense* at 100, 200, 400 and 800 mg/kg bodyweight to albino rats decreased the activities of AST, ALP, ALT and 5'-Nucleotidase enzymes and the decrease was dose dependent. Also, from the histological analysis of the hepatic tissue showed that the liver architecture is normal with hepatocytes radiating from the central vein. The overall features were consistent with normal hepatic architecture except at 800 mg/kg body which showed little difference: There were congestion of blood vessels and distortion of hepatic architecture respectively as the concentration of the extract increase. The result indicate that this plant leave is safe for human consumption especially on the rural dwellers who use them as a source of nutrient and as anti-anemic herbs, but precaution has to be taken by the traditional herbalist not to recommend the high concentration for prolong period of time as this can result in congestion of blood vessel thereby preventing the free flow of blood in the system.

Keywords: *Vitex doniana*, *Bombax buonopense*, Liver enzymes, Histological studies.

Date of Submission: 27-05-2024

Date of Acceptance: 07-06-2024

I. Introduction

Plants play a vital role in maintaining the human health through the production of foods which provide nutrients for the body as well as medicinal purposes. Medicinal plants are defined as plants that contain substances useful for therapeutic purposes. It also serves as a precursor for the synthesis of useful drugs (Chisom *et al*, 2014). It is a common knowledge that there is a dearth of nutritive foods in most developing countries of the world. Most people in these countries die prematurely from lack of good medicinal care and those who escape death are usually faced with problem of hunger and starvation. This ugly scenario can be partially reversed if good food is consumed. Fruits and vegetables form important part of human diet.

Vitex doniana belongs to the family of *Verbanaceae*. It is the most abundant and widespread of the genus occurring in savannah regions. It is a deciduous forest tree of coastal woodland, riverine and lowland forests tree and deciduous woodland, extending as high as upland grassland. It is a medium sized deciduous tree, 8-18m high, with a heavy rounded crown and a clear bole up to 5m³. The flowers are small, blue or violet, 3-12cm in diameter, only a few being open at a time. The fruits are oblong, about 3cm long. Green when young, turning purplish-black on ripening and with a starchy black pulp. It tests good when consumed. Each fruit contains 1 hard, conical seed, 1.5-2cm long, 1-1.2cm wide. This indigenous plant plays a vital role in the livelihoods of many rural communities in Eastern Africa, especially those living in the drylands. Plants of genus *Vitex* from the *Verbanaceae* are trees or shrubs occurring in tropical and subtropical regions. In dryland like Kenya, they occur in Western, central, and coastal regions (Beentje,1994). Phytochemical reports on *Vitex* species, indicate that they are rich sources of ketosteroids, iridoids, terpenoids and flavonoid glycosides (Ono *et al.*, 2000). These plants have a wide range of biological activities. Among them in the management of menstrual disorders (Pearlster and Steiner, 2008), induction of uterine contraction (Ladeji *et al.*,2005) anti-inflammatory and analgesic activities of *Vitex doniana* (Iwueke *et al.*, 2006). Abdulrahma *et al.*, (2010) reported that *Vitex doniana* extract improved haematological parameters and so can be used to treat anaemia.

Bombax buonopense is a large tropical tree that grows up to 40 meters in height with large buttress roots that can spread 6 meters down (Mann *et al.*, 2003). The individual leaf has entire margin and quite large, measuring from 8 to 23cm in length and 3 to 7cm in width with the undersides of the leaf being conical buds which contains many seeds that are 5 to 6mm in length, all of which have a cotton-like fiber covering (Beentje and Sara 2003). *Bombax buonopense* is called 'Akpu' in Igbo, 'Ogbolo' in Yoruba and soon. Different part of these plants is used for different purposes (Dubost and Gabon 1984). Hot decoction of the dried stem bark of the plant is taken orally for the treatment of malaria (Asase and Oppong 2009). The bark is used to treat chest pain (Madge 1998). Decoction of the leaves is used to manage stomach ulcers and burns. Aqueous extract of the is used to treat diarrhea and dysentery. (Irvine 1998) The immature fruits are prepared as an emollient for skin, decoction of the young leaves is used as a warm bath for fibril children. The grounded bark is taken by pregnant women to increase lactation, also the extract from the bark is drunk or applied on the head for dizziness. The gum resin from the bark is pulverized, mixed with oil and used to manage skin diseases (Abdu and Echeme 2006). Report by Abdu and Echeme 2006, indicated that its deep green leaves and deep yellow fruits provide high amount of ascorbic acid, carotene and micro minerals which play a vital role in nutrient metabolism and slowing down of degenerative diseases such as cancer and heart diseases. Its flowers having bright red to pink color attract birds and insects which contribute to pollination of the plant. Chisom *et al* (2014) discovered that various parts of this plant contain appreciable amount of nutrients such as carbohydrates, proteins, calcium, magnesium, zinc as well as antinutrients such as oxalates, phytate and cyanide in minute quantity. This present study is to investigate the activity of liver enzymes and also to carry out the histological studies on the liver in prolonged administration of the aqueous and methanol leaf extracts of *Vitex doniana* and *Bombax buonopense* on Albino rats at different concentration.

II. Materials And Methods

The biological materials used for the study were leaves of *Vitex donaina*, *Bombax buonopense* and albino rats. The leaves of *Vitex donaina* and *Bombax buonopense* were collected in Ikwo L.G.A of Ebonyi State and were identified and authenticated by a botanist in the department of Applied Biology, Ebonyi State University, Abakaliki. A total of 300 adult male albino rats were purchased from the Department of Animal science, University of Nigeria Nsukka and used for the study.

Preparation of *Bombax Buonopense* and *Vitex Doniana* Leaves.

Fresh leaves of *Vitex doniana* and *Bombax buonopense* were collected, washed and dried at ambient temperature. After drying, the leaves were pulverized using manual grinder. The powdered leaves were stored in refrigerator in well labeled, air tight container prior to use.

Preparation of Extracts

The extracts from Leaves of *Vitex doniana* and *Bombax buonopense* were obtained using the following procedures: first, 500g of powdered sample were soaked in 1500 ml of extracting solvent in conical flask. The contents of the flask were shaken and the top was covered with aluminum foil and kept at room temperature for 48hrs after which the extracts were obtained by filtering using a sieve cloth. The extracts were then concentrated using rotary evaporator and kept in sealed containers and refrigerated until required (James *et al.*, 2010).

Acute Toxicity Study

Acute toxicity study of *Vitex doniana* and *Bombax buonopense* aqueous and methanol leaf extracts were done according to the method of Lorke (1983). The method involves two phases; the first phase was done using 102 male rats and they were randomly assigned to five experimental groups 1, 2, 3, 4 and 5. Group 1 with 6 rats received the normal saline (vehicle), rat feed and served as control while groups 2 and 3 received aqueous leaf extracts of *Vitex doniana* and *Bombax buonopense* respectively. Groups 4 and 5 received methanol leaf extracts of *Vitex doniana* and *Bombax buonopense* respectively. Groups 2, 3, 4 and 5 were separately sub-grouped into four groups with 6 rats each. The sub-groups were given single oral aqueous and methanol leaf extracts of *Vitex doniana* and *Bombax buonopense* at 200, 400, 800 and 1600 mg/kg body weight respectively. All the animals were allowed free access to food and water and observed over a period of 24 hours for signs of acute toxicity. In phase two, 96 rats were used and higher concentrations of the extracts were administered per kilo gram body weight of rats. The rats were grouped as in phase 1 above into groups 6, 7, 8 and 9. Groups 6 and 7 received aqueous leaf extracts of *Vitex doniana* and *Bombax buonopense* while groups 8 and 9 received methanol leaf extract of *Vitex doniana* and *Bombax buonopense*. These groups were sub-grouped into 4 groups with 6 rats each. The sub-groups were given single dose of aqueous and methanols leaves extracts of *Vitex doniana* and *Bombax buonopense* orally at 2000, 2500, 3000 and 3500 mg/kg body weight respectively and were watched again for 24hrs.

Sub-Acute Toxicity Study

In this study 102 male albino rats were used. The rats were randomly assigned to five experimental groups A, B, C, D and E. Group A with 6 rats received only normal saline, rat feed and served as normal control, while B and C received aqueous leaf extract of *Vitex doniana* and *Bombax buonopense* respectively. Group D and E received methanol leaf extracts of *Vitex doniana* and *Bombax buonopense* respectively. Groups B, C, D and E were separately sub-grouped into four groups with 6 rats in each group. The sub-groups were given a single oral dose of aqueous and methanol leaf extracts of *Vitex doniana* and *Bombax buonopense* at the concentrations of 100, 200, 400 and 800 mg/kg body weights respectively for 21 days. After which liver enzymes were measured.

Biochemical Analysis

After the treatment period, the rats were allowed to fast for 24hours and then anaesthetized using mild anesthesia (chloroform) and dissected. After, dissection blood was drawn directly from the heart using syringe (cardiac puncture). The blood specimens were stored in anti-coagulant free bottles. The liver and kidney were quickly excised and washed with cold physiological saline to remove blood and adhering tissues and then preserved in 10 % formol acetic acid for histological analysis. The blood specimens were centrifuged at 3000 rpm for 10 mins to separate the serum from the red cells and stored in specimen bottles until used for analysis.

Determination of Liver Enzymes;

The method of Reitman and Frankel (1957) was used to determine the aspartate transaminase and Alanine transaminase activities. The method of King and Armstrong (1934) was used to determine ALP Activity. The method of Raymond and David (1980) was used to determine 5'- nucleotidase.

Histological Examination of Tissue

Histological analysis of Liver was done using the method of Ansah *et al.*, (2009) by a pathologist Dr. B.A.F. Ngwu in Federal University Teaching Hospital, Abakaliki.

Statistical Analysis

Results were expressed as mean \pm standard deviations (S.D) where applicable. The data were subjected to one-way analysis of variance (ANOVA), followed by the Dunca's test for individual comparisons using SPSS software and $p < 0.05$ was regarded as significant (Sokal and Rholf, 1969).

III. Results And Discussion

The administration of the aqueous and methanol leaf extracts of *Vitex doniana* and *Bombax buonopense* at 100, 200, 400 and 800 mg/kg bodyweight to albino rats decreased the activities of AST, ALP, ALT and 5'-Nucleotidase enzymes and the decrease was dose dependent. In figure 1, all the rats administered aqueous and methanol leaf extract *Bombax buonopense* and *Vitex doniana* showed significant ($p < 0.05$) decrease in the activities of AST. Figure 2, showed that the administration of the two leaf extracts significantly ($p < 0.05$) decreased in the activities of ALT in all the rats. In figure 3, administration of the two leaves extract showed significant ($p < 0.05$) decrease in the activities ALP. In figure 4, aqueous leaf extracts of *Vitex doniana* and *Bombax buonopense* at 100mg/kg did not show significant ($p < 0.5$) decrease in the activities of 5'-Nucleotidase. The data were represented as mean \pm S.D (n=6). Bars are the mean values, and (*) are signs of Significant difference at ($p < 0.05$) in comparison with the control.

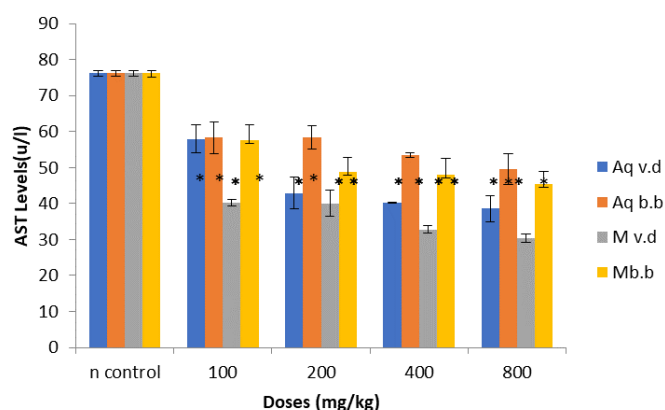


Figure 1: Ast Level In Albino Rats Administered With Aqueous, Methanol Extracts Of *Vitex Doniana* And *Bombax Buonopense* Leaf.

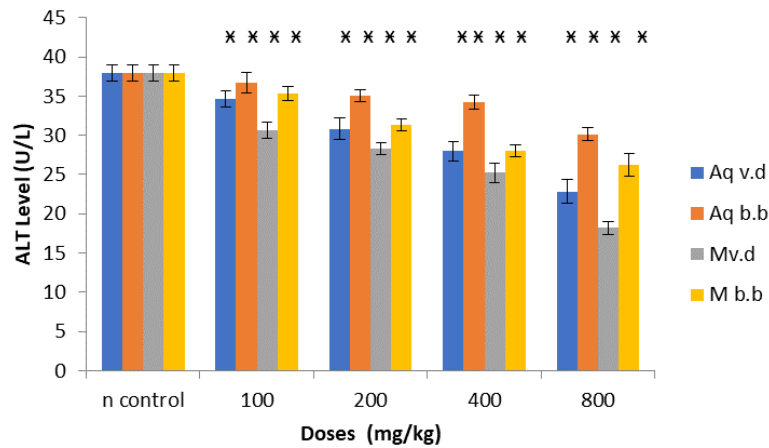


Figure 2: Alt Level In Albino Rats Administered With Aqueous, Methanol Extracts Of *Vitex Doniana* And *Bombax Buonopense* Leaf.

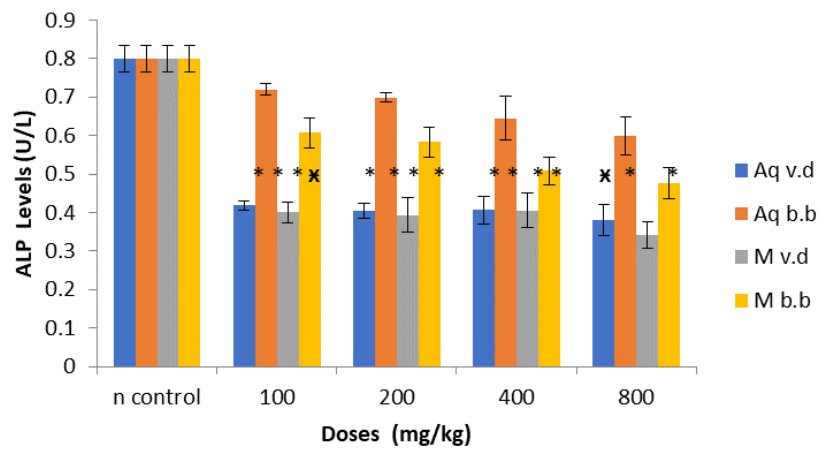


Figure 3: Alp Level In Albino Rats Administered With Aqueous, Methanol Extracts Of *Vitex Doniana* And *Bombax Buonopense* Leaf.

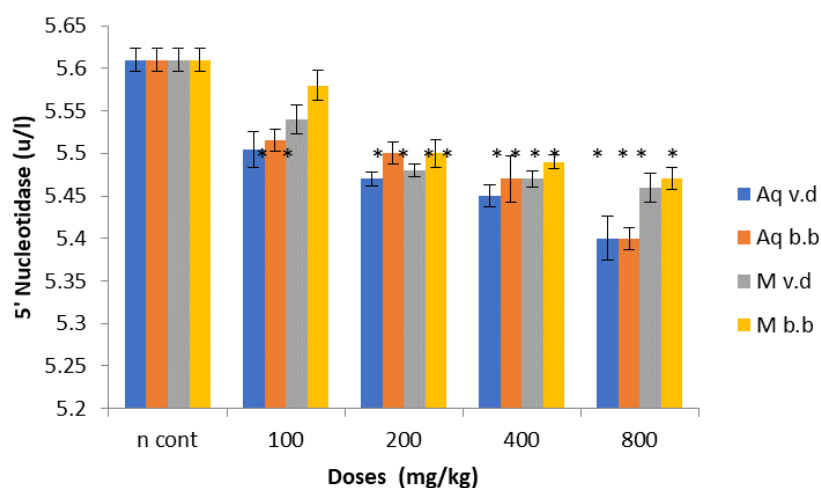
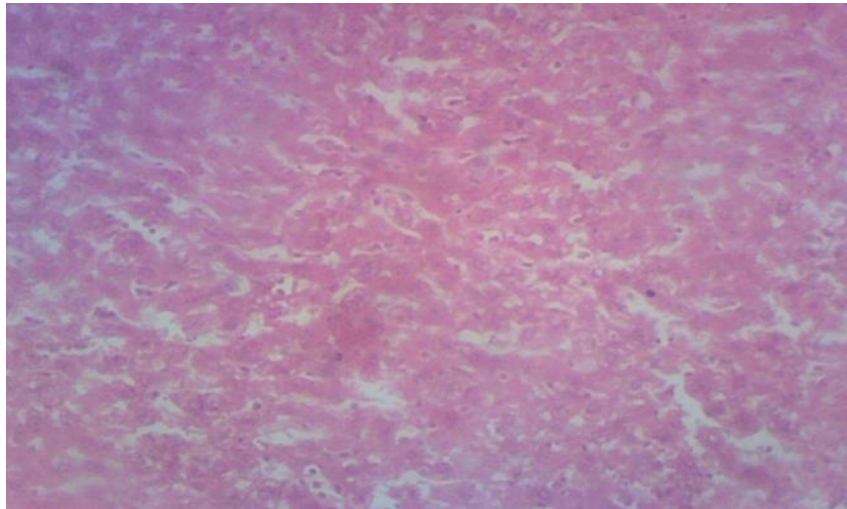


Figure 4: 5'- Nucleotidase Level In Albino Rats Administered With Aqueous, Methanol Extracts Of *Vitex Doniana* And *Bombax Buonopense* Leaf.

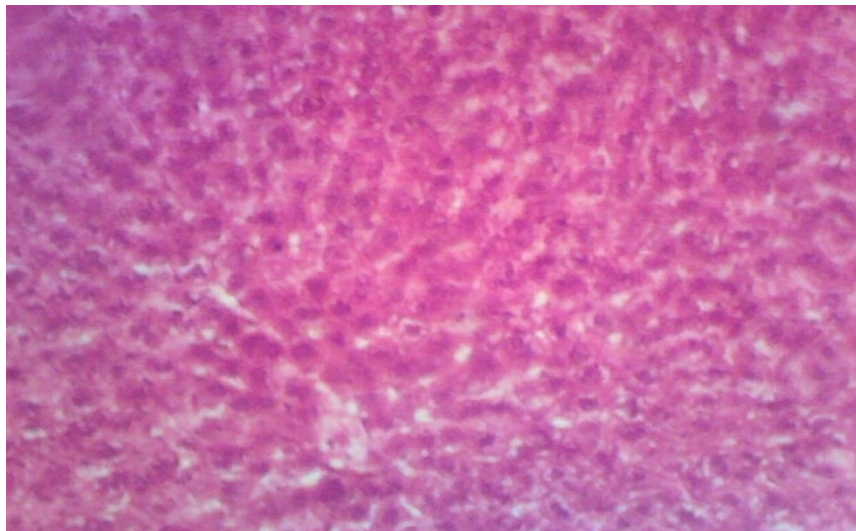
Photomicrograph of Liver tissue in Albino Rats that was Administered with Aqueous and Methanol Leaf Extracts of *Vitex doniana* and *Bombax buonopense*.

Histological analysis of albino rat's liver administered with aqueous and methanol extracts of *Vitex doniana* and *Bombax buonopense* leaves at 100, 200, 400 and 800 mg/kg doses (plate 1-17). Plates 1 and 18 were photomicrographs of liver collected from the rats treated with the extracts. The result showed that the liver architecture is normal with hepatocytes radiating from the central vein. The overall features were consistent with normal hepatic architecture. Plates 2-17 were photomicrograph of liver from the rats that received different doses of aqueous and methanol extracts of *Vitex doniana* and *Bombax buonopense* leaf extracts at 100, 200, 400 and 800 mg/kg bodyweight doses. They have normal hepatic architecture. Plates 5 and 9 were photomicrograph of liver administered with aqueous and methanol extracts of *Vitex doniana* at 800 mg/kg body respectively which showed little difference: There were congestion of blood vessels and distortion of hepatic architecture respectively as the concentration of the extract increase.



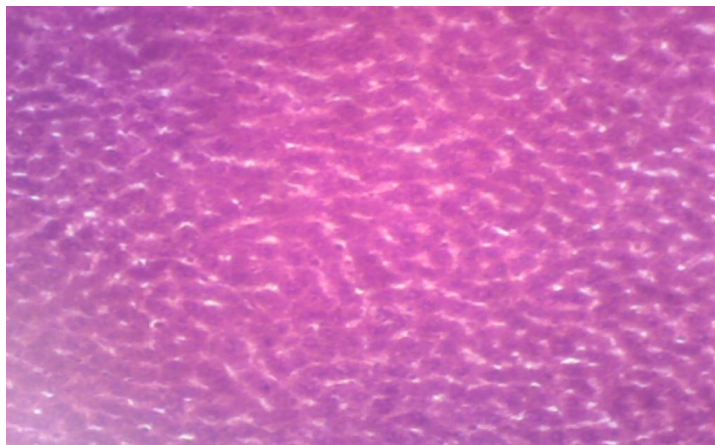
Magnification : X₁₅₀

Plate1: Photomicrograph Of Liver Of Albino Rats Used As Control Without Any Extract Administration Stained With H/E Showed Normal Hepatic Architecture (NHA).



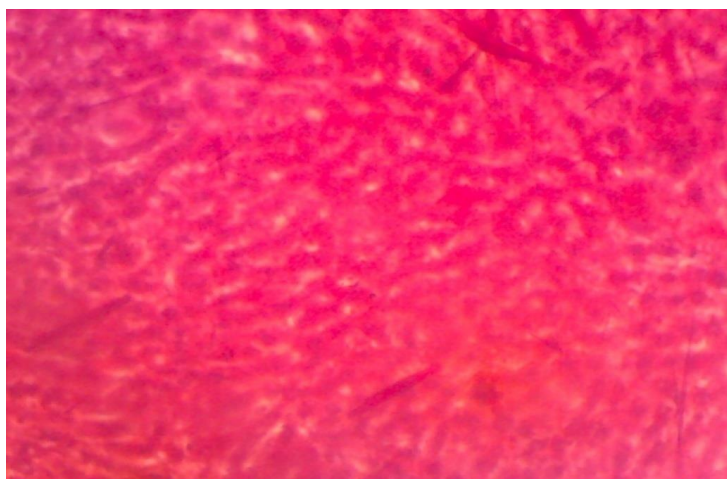
Magnification : X₁₀₀

Plate 2: Photomicrograph Of Rats Liver That Received 100 Mg/Kg Of Aqueous Leaf Extract Of *Vitex Doniana* Stained With H/E Showed Well Perfused Hepatic Architecture(WPHA).



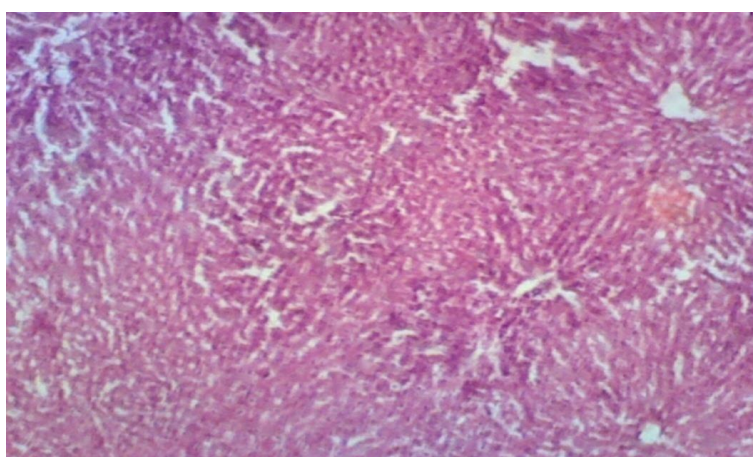
Magnification : X₆₀

Plate 3: Photomicrograph Of Rat Liver That Received 200 Mg/Kg Of Aqueous Leaf Extract Of *Vitex Doniana* Stained With H/E Showed Well Perfused Normal Hepatic Architecture.



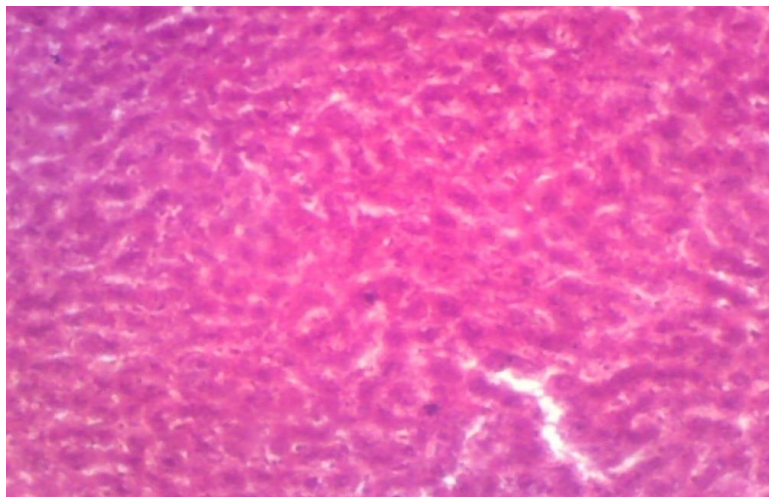
Magnification : X₆₀

Plate 4: Photomicrograph Of Rat Liver That Received 400 Mg/Kg Of Aqueous Leaf Extract Of *Vitex Doniana* Stained With H/E Showed Well Perfused Hepatic Architecture (WPHA).



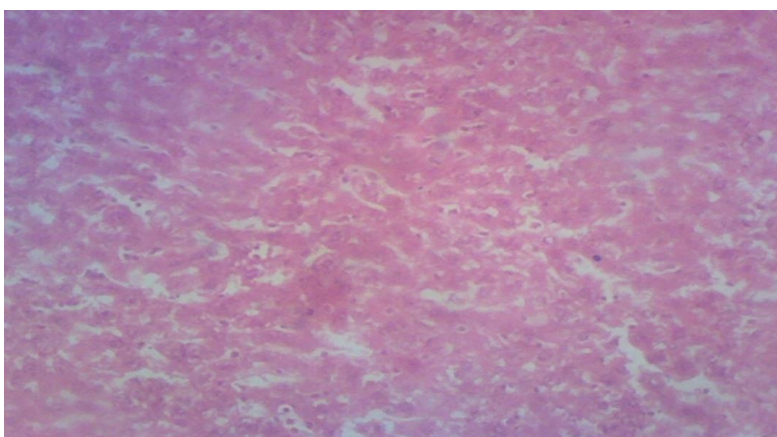
Magnification : X₁₅₀

Plate 5: Photomicrograph Of Rat Liver That Received 800 Mg/Kg Of Aqueous Leaf Extract Of *Vitex Doniana* Stained With H/E Showed Normal Hepatic Cell (NHC), Conjestion Of Blood Vessel (CBV).



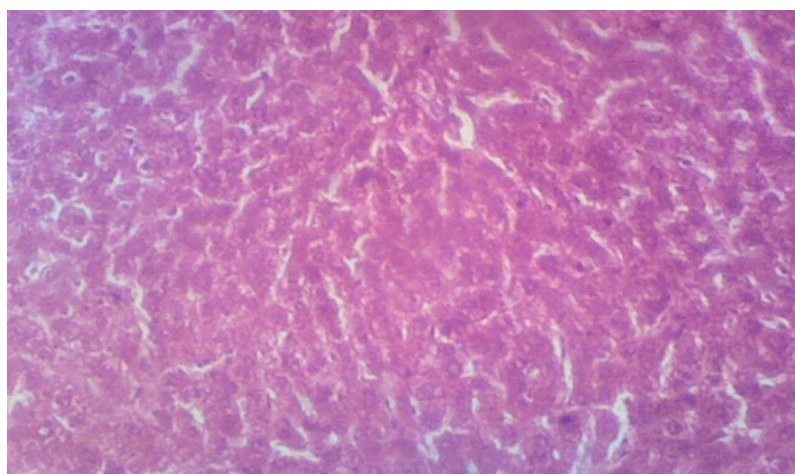
Magnification : X₁₅₀

Plate 6: Photomicrograph Of Rat Liver That Received 100 Mg/Kg Of Methanol Leaf Extract Of *Vitex Doniana* Stained With H/E Showed Normal Hepatic Architecture



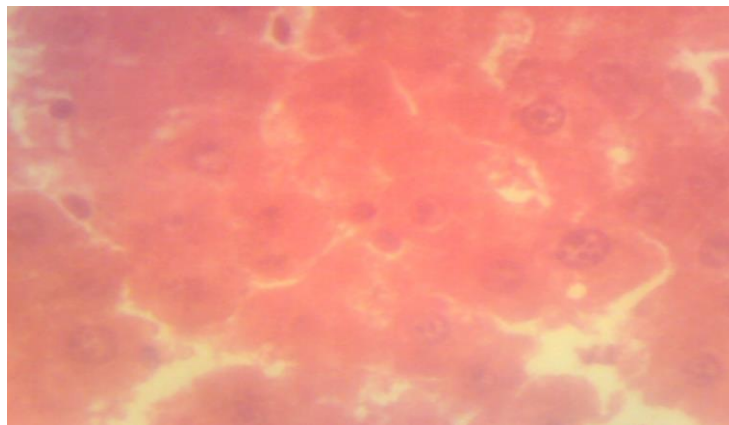
Magnification : X₁₅₀

Plate 7: Photomicrograph Of Rat Liver That Received 200 Mg/Kg Of Methanol Leaf Extract Of *Vitex Doniana* Stained With H/E Showed Normal Hepatic Architecture (NHA).



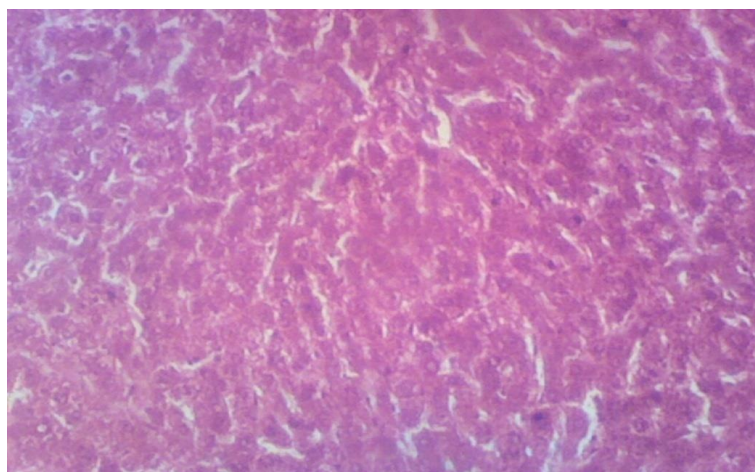
Magnification : X₁₅₀

Plate 8: Photomicrograph Of Rat Liver That Received 400 Mg/Kg Of Methanol Leaf Extract Of *Vitex Doniana* Stained With H/E Showed Normal Well Perfused Hepatic Architecture.



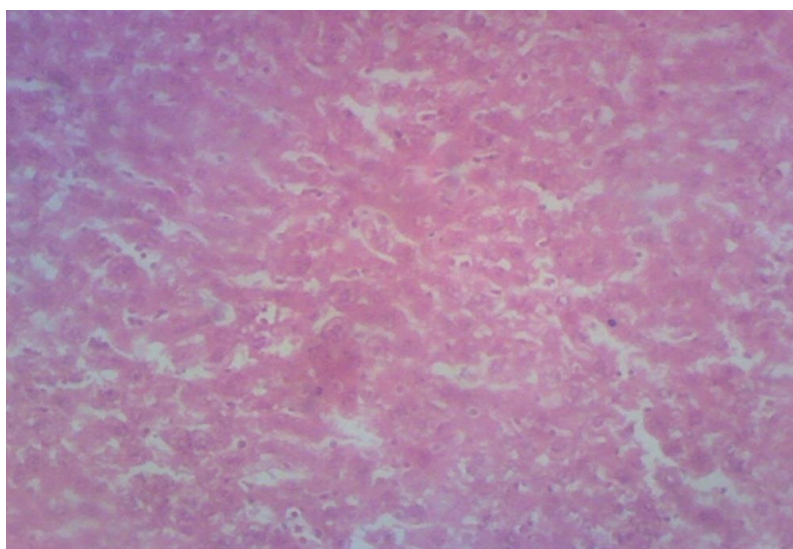
Magnification : X₆₀₀

Plate 9: Photomicrograph Of Rat Liver That Received 800 Mg/Kg Of Methanol Leaf Extract Of *Vitex Doniana* Stained With H/E Showed Distortion Of Hepatic Architecture (DHA).



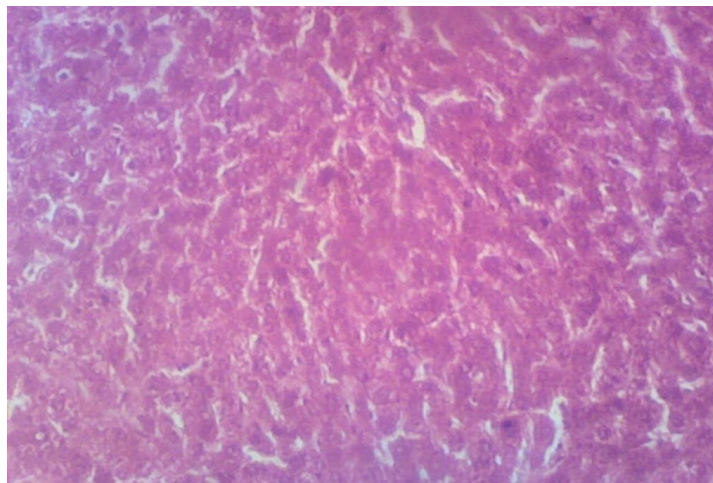
Magnification : X₁₅₀

Plate 10: Photomicrograph Of Rat Liver That Received 100 Mg/Kg Of Aqueous Leaf Extract Of *Bombax Buonopense* Stained With H/E Showed Normal Hepatic Architecture.



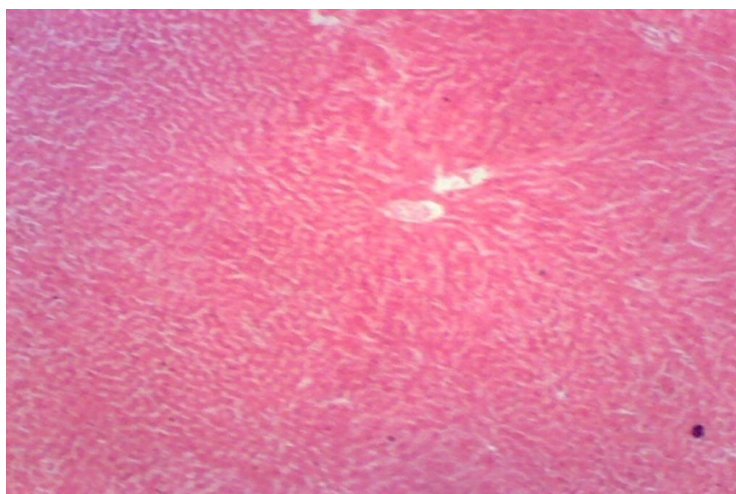
Magnification : X₁₅₀

Plate 11: Photomicrograph Of Rat Liver That Received 200 Mg/Kg Of Aqueous Leaf Extract Of *Bombax Buonopense* Stained With H/E Showed Normal Hepatic Architecture (NHA).



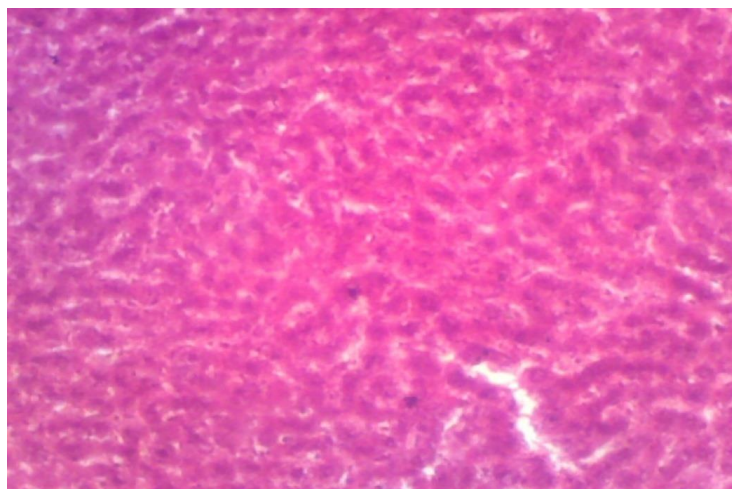
Magnification : X₁₅₀

Plate 12: Photomicrograph Of Liver That Received 400 Mg/Kg Of Aqueous Leaf Extract Of *Bombax Buonopense* Stained With H/E Showed Normal Hepatic Architecture.



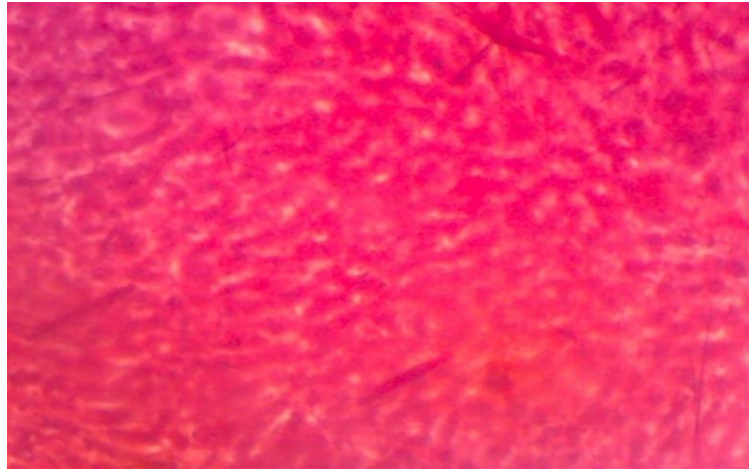
Magnification : X₁₅₀

Plate 13: Photomicrograph Of Rat Liver That Received 800 Mg/Kg Of Aqueous Leaf Extract Of *Bombax Buonopense* Stained With H/E Showed Well Perfused Normal Hepatic Architecture.



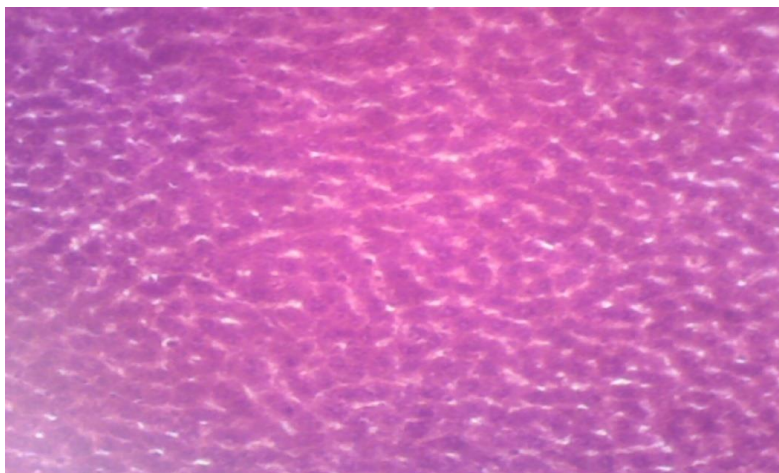
Magnification : X₁₅₀

Plate 14: Photomicrograph Of Liver Administered With 100 Mg/Kg Of Methanol Leaf Extract Of *Bombax Buonopense* Stained With H/E Showed Well Perfused Hepatic Architecture And Normal Liver Architecture.



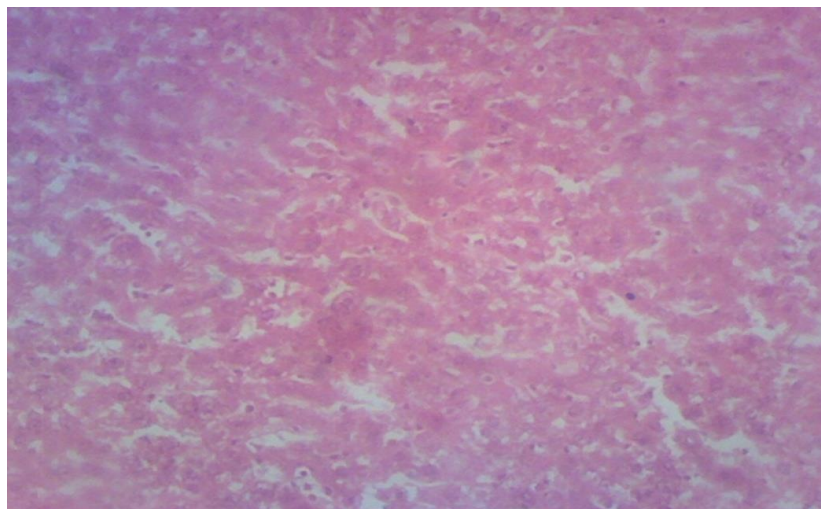
Magnification : X₆₀

Plate 15: Photomicrograph Of Rat Liver Administered With 200 Mg/Kg Of Methanol Leaf Extract Of *Bombax Buonopense* Stained With H/E Showed Well Perfused Hepatic Architeture (WPHA).



Magnification : X₆₀

Plate 16: Photomicrograph Of Rat Liver Administered With 400 Mg/Kg Of Methanol Leaf Extracts Of *Bombax Buonopense* Stained With H/E Showed Well Perfused Normal Hepatic Architeture.



Magnification : X₁₅₀

Plate 17: Photomicrograph Of Rat Liver Administered With 800 Mg/Kg Of Methanol Leaf Extract Of *Bombax Buonopense* Stained With H/E Showed Normal Hepatic Architeture (NHA).

LD₅₀ Determination

From the result obtained so far, we observed that at 1600 mg/kg body weight leaf extract of *Vitex doniana* and *Bombax buonopense* respectively, they are safe for medicinal use and consumption. However, at higher concentrations 2000, 2500, 3000 and 3500 mg/kg of the two plant extracts, mortality was recorded within 24hrs of extract administration. At 2000 mg/kg, 3 rats died in each of the aqueous and methanol leaf extracts of *Vitex doniana* administration respectively and above this concentration the entire animal died within 24hrs of extract administration except in aqueous *Vitex doniana* where 5 rats died in 2500 mg/kg body weight of the extracts. At 3000 mg/kg, 2 and 3 rats died in each of aqueous and methanol extract of *Bombax buonopense* respectively and above this concentration all the rats died within 24 hrs. Therefore, LD₅₀ for *Vitex doniana* is 1,789 mg/kg and *Bombax buonopense* is 2,449 mg/kg. This showed that LD₅₀ for *Bombax buonopense* was higher than that of *Vitex doniana*. And these values are high when compared to 980 mg/kg obtained in water root bark extract of *Vitex doniana* sweet as reported by Abdulrahman *et al.*, 2010. There was no adverse effect in all the groups with the different concentrations of extracts used. There was no death and behavioural changes recorded during the course of the experiment in all treated groups as compared to control group. The rate of food and water intake of the rats given 100, 200, 400 and 800 mg/kg doses of *Vitex doniana* and *Bombax buonopense* aqueous and methanol leaf extracts decreased with increase in concentration when compared to the control group. Ngwuluka (2012) reported that *Bombax buonopense* is not toxic even at higher concentration of 3000mg/kg.

Liver Enzymes

In the cause of administration of this extract for 21 days at 100, 200, 400 and 800 mg/kg doses The liver enzymes AST, ALT, ALP and 5' Nucleotidase activities decreased with increase in administration of the extract.

Histological Study

The results of histological analysis of rat's liver administered with aqueous and methanol extracts of *Vitex doniana* and *Bombax buonopense* at 100, 200, 400 and 800mg/kg doses showed normal architectures of liver. (Plate 1-34). The well perfused hepatic architecture architectures seen at lower concentration may be an indication that the extract could be useful for treatment of anaemia, hence the justification for its use by natives, and also explains the high use of *Vitex doniana* as anti-anaemic plant.

IV. Conclusion

From the study, the administration of the aqueous and methanol leaf extracts of *Vitex doniana* and *Bombax buonopense* at 100, 200, 400 and 800 mg/kg bodyweight to albino rats decreased the activities of AST, ALP, ALT and 5'-Nucleotidase enzymes and the decrease was dose dependent. Histological examination of Liver tissue showed normal hepatic architecture but photomicrograph of liver administered with 800 mg/kg body of the *Vitex doniana* extracts showed little difference: there were congestion of blood vessels and distortion of hepatic architecture respectively as the concentration of the extract increase. The result indicate that this plant leave is safe for human consumption especially on the rural dwellers who use them as a source of nutrient and as anti-anemic herbs, but precaution has to be taken by the traditional herbalist not to recommend the high concentration for prolong period of time as this can result in congestion of blood vessel thereby preventing the free flow of blood in the system. These leaf extracts can result to tumor growth and other complication especially when used on healthy tissue at high concentration for long time (Abdulrahma *et al.*, 2010). Therefore, caution has to be taken when using the extracts especially at high doses for long period.

References

- [1] Abdu K And Echeme J.O (2006). Phytochemical And Antimicrobial Screening Of The Ethanoic Extract Of Leaves Of Anogeissus Leiocarpus. *Best* 3:162-164.
- [2] Abdulrahman, F. I., Akan, J. C., Sodipo, O. A. And Onyeyili, P. A. (2010). Effect Of Aqueous Root-Bark Extract Of Vitex Doniana Sweet On Haematological Parameters In Rats. *Journal Of American Science*, 6(12):8-12.
- [3] Ansah, E., Oppong, E And Duwiejua, M. (2009). Toxicity Study On Alchornea Cardifolia; *Journal Of Natural Health*, 2 (1): 19-24.
- [4] Asase A. Oppong-Mensah G (2009). Traditional Antimalarial Phytotherapy Remedies In Herbal Markets In Southern Ghana. *Journal Ethnopharmacol* 126:492-499.
- [5] Beentje, H.J.,1994. Kenya Tress, Shrubs And Lianas. 1st Edition, National Museums Of Kenya, Kenya, Pp:1-722.
- [6] Beentje H, Sara S (2001). Plant System And Phytochemical For The Understanding Of African Biodiversity, *Systematic And Geography Of Plants* 71:284-286
- [7] Dubost G, Gabon J (1984). Comparison Of Diets Of Frugivorous Mammals 65:298-316
- [8] King, E. J. And Armstrong, A. R. (1934). Determination Of Serum And Bile Phosphate Activity. *Cannadia Medical Association Journal* 31: 56-63
- [9] Iwueke, A.V., O.F.C. Nwodo And C.O. Okoli,2006. Evaluation Of The Anti-Inflammatory And Analgesic Activities Of Vitex Doniana Leaves. *Afr. J. Biotech*, 5:1929-1935