

A case of Stickler syndrome with neonatal-onset arthropathy

Sucharita Datta, MD¹, Saumyen De, MD², Anand Prasad³, Ujjal Mondal⁴,
Rahul Majumdar, MD⁵

¹ Associate Professor, ² Assistant Professor, ^{3,4} Post Graduate Trainee, ⁵ RMO Cum Clinical Tutor, Department of Pediatrics, Nilratan Sircar Medical College, West Bengal University of Health Sciences, India

Abstract: Stickler syndrome is a rare genetic connective tissue disorder (incidence 1 in 7500 births) related to mutations in the collagen genes. One out of 4 patients with Stickler syndrome has a Pierre Robin sequence-detected at birth by a combination of retrognathia, micrognathia, cleft palate and retroglossoptosis. Ocular abnormalities, craniofacial anomalies, bone and joint symptoms and hearing loss are the main manifestations of Stickler syndrome. Early onset osteoarthritis with a prevalence of 15% before 20 years of age and 75% after 50 years of age presents with a variety of features including metaphyseal-epiphyseal dysplasia with broadening and stiffness of joints, pronated feet and moderate arachnodactyly – all of which were present in the 40 day old male infant that we are reporting. The unusual occurrence of arthropathy involving bilateral knee and shoulder joints with stiffness and broadening of affected joints detected so early in life, has not been reported so far to the best of our knowledge. This baby also presented with megalocornea and glaucoma together with other phenotypic abnormalities specific for Stickler syndrome. The early recognition of arthropathy and ophthalmopathy in the neonatal period in association with features of Pierre Robin sequence helped us to make the diagnosis of Stickler syndrome by 45 days of age. The idea of reporting this case is not only to make the pediatrician aware about the probability of diagnosis of Stickler syndrome in a newborn with Pierre Robin sequence as also to stress the need for regular follow up by an ophthalmologist and a test of hearing soon after birth and audiograms at diagnosis and at regular follow-ups. Regular monitoring from early infancy and through the teens for the above-mentioned problems with prompt interventions will go a long way in improving the quality of life in children with Stickler syndrome.

Keywords: Glaucoma, Megalocornea, Osteoarthritis, Pierre Robin sequence, Stickler syndrome

I. INTRODUCTION

Stickler syndrome is a group of rare genetic diseases characterized by early onset osteoarthritis, joint hypermobility, craniofacial birth defects, early myopia with a high risk of retinal detachment and visual loss and hearing abnormalities. All forms of Stickler syndrome are due to mutations in the collagen genes : Type I due to mutation in COL2A1 gene, Type II involving the COL11A1 gene and Type III involving the COL11A2 gene are dominant mutations^{1,2}, while a fourth mutation in the COL9A1 is transmitted on an autosomal recessive basis³. Gunnar B Stickler, a pediatrician at the Mayo Clinic, Rochester, MN first described the findings of a 12 year old boy who had marked bony prominences about the joints and visual impairment under the name “ hereditary progressive arthro-ophthalmopathy” in the Mayo Clinic proceedings in June 1965. The boy’s mother was blind. Since 1980, the term “Stickler syndrome” has been used to designate the condition⁴.

II. CASE REPORT

A 40 day-old male baby weighing 2.5 Kg was brought to us with the chief complaints of severe difficulty in feeding since birth and progressive swelling of the knee joints and ankle joints on both sides (Fig: 1). The baby was a product of second degree consanguineous marriage and was delivered by caesarean section at full-term after a prolonged labour with premature rupture of membranes. The birth weight was 3.1 kg. Perinatal history revealed that the baby was asphyxiated at birth and did not have a lusty cry even after resuscitation. The newborn had to be cared for in the neonatal intensive care unit upto 37 days of age. Following discharge, the baby was admitted in our inpatient ward 3 days later with feeding difficulty and multiple joint swellings. The baby was totally on formula feeds. This was the first issue of the parents and there was no history of similar or any other congenital problems in any other member of the family. Social smile and neck-holding did not develop till 3 months of age.

On examination, the baby showed evidence of failure to thrive with a decrement of 600 gms over 40 days from his birth weight. Supine length was normal (51 cm) with a US:LS ratio of 1.7:1 (normal body proportions).The head circumference was 36 cm and the chest circumference (29 cm) was much less than the head circumference. The arm span was 41.5 cm ruling out long limbs. However all the fingers of both the hands and toes of both feet were long and slender suggestive of moderate arachnodactyly (Fig:1 & 5). Both feet were pronated with a calcaneovagus deformity. Rounded prominent swellings were evident around both knee joints as

well as shoulder joints (Fig:1). There was restriction of movement of the affected joints with obvious tenderness on movement.

The facies was abnormal with prominent eyes, a flat hypoplastic mid-face with a depressed nasal bridge, hypoplastic nose with anteverted nares and long philtrum with micrognathia/retrognathia (Fig:3) . Additional features such as retroglossoptosis due to fore- shortened oral cavity and a round cleft of soft palate confirmed the diagnosis of Pierre Robin sequence (Fig:2).

The blood counts, liver and renal function tests, the serum uric acid and electrolyte studies were within normal limits.

Skeletal X-rays revealed broadening of the metaphyseal-epiphyseal areas at the shoulder joint and knee joint regions resembling a dumbbell appearance of both the femora (Fig:4).

An echocardiography revealed a small ostium secundum type of atrial septal defect. Rest of the findings were normal.

Ophthalmologic consultations were sought for corneal diameter measurement, tonometry and fundoscopy. The corneal diameter in the horizontal plane was 13 mm and in the vertical plane was 12 mm (both>normal). The intraocular pressure in the right eye was 22.4 mm Hg on 3 successive examinations at 7-10 days interval while that in the left eye was around approximately 24.4 mm, Hg suggestive of raised intraocular pressure and glaucoma.

Management and care were mainly directed to facilitate feeding. The mother was cautioned to feed the baby only in the upright position in her lap so as to prevent aspiration of milk through the cleft palate and also to avoid the potential risk of otitis media and irreversible conductive deafness in the long run. An elongated and slender nipple fitted to a feeding device was advised for feeding milk, keeping in mind the small oral cavity and shortened palate. The parents were advised to get the baby periodically monitored for orthopedic, eye, and hearing problems and given genetic counselling regarding risk of recurrence.

III. FIGURES

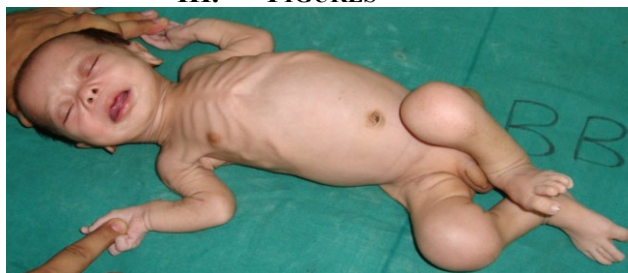

Fig:1: Stickler syndrome with neonatal-onset osteoarthropathy with large prominent knee joints

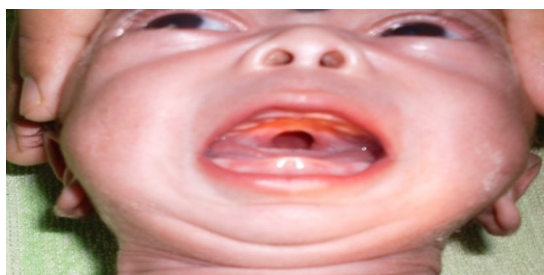


Fig:2: Partial cleft palate involving posterior hard and soft palate

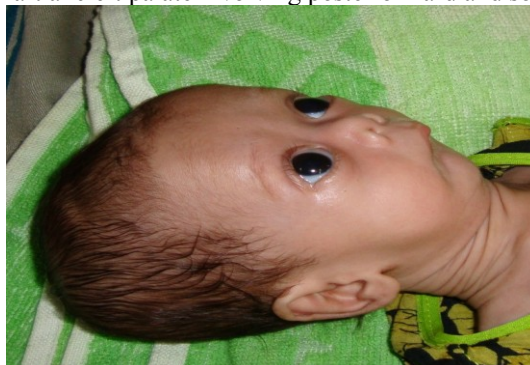

Fig:3: Large prominent eyes with depressed nasal bridge, malar hypoplasia, micro-retrognathia, anteverted nostrils

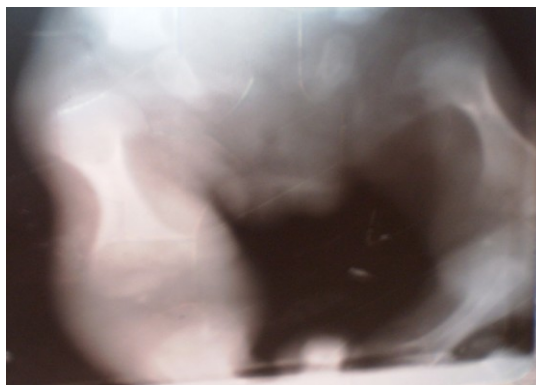


Fig:4: Metaphyseal widening of both femora

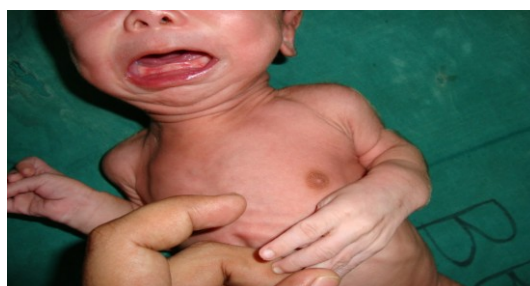

Fig:5: Hands showing moderate arachnodactyly

IV. Discussion

Stickler syndrome may be revealed at birth (25% of cases) by a combination of cleft palate, retrognathia and micrognathia, known as Pierre Robin sequence , which may cause neonatal respiratory problems ⁵. This baby too suffered from asphyxia at birth with difficulty in resuscitation and an eventful perinatal period necessitating neonatal intensive care upto 37 days of age. Additionally there were feeding difficulties. When prenatal sonograms show the complete Pierre Robin sequence , appropriate care should be planned at delivery. In some patients, tracheostomy is required at birth to bypass the airway obstruction. It is estimated that 10-30% of the patients with Pierre Robin sequence present Stickler syndrome^{6,7,8}. Again cleft palate presentation in patients with Stickler syndrome needs to be differentiated from isolated cleft palate. Currently, the diagnosis of Stickler syndrome is based on clinical signs.

According to the diagnostic criteria for Stickler syndrome by Rose et al (2005) ⁹, the scoring system includes four major parameters (2 points each): cleft palate, abnormalities of vitreous architecture, retinal abnormalities and sensorineural hearing loss. Minor parameters (1 point each) are the flat face, musculoskeletal changes and family history of Stickler syndrome . A score of ≥ 5 , including the presence of at least one major sign is considered diagnostic of the Stickler syndrome ⁹. Stickler syndrome shows large clinical variability and there needs to be a redefined set of diagnostic criteria for Stickler syndrome to allow for better diagnosis. Presently the diagnosis of Stickler syndrome requires the presence of at least one of the important phenotypical features and two of the minor phenotypical features.

Our patient had cleft palate as part of the spectrum of Pierre Robin sequence. The baby showed normal fundoscopic findings with optic disc, macula, entire fundus and vitreous within normal limits. However other than vitreoretinal abnormalities, cataracts and glaucoma are also evidence of severe ocular disease ¹⁰. Our patient with large prominent eyes had markedly raised intraocular pressure in both eyes(> double the normal value) on 3 successive tonometric measurements indicating glaucoma. Bilateral megalocornea was also documented. Hearing tests were not feasible within the period of hospital stay. However the startle response could not be elicited with a sufficiently loud sound stimulus. The baby showed typical craniofacial features such as shallow supraorbital ridges, a flat hypoplastic midface with a depressed nasal bridge, hypoplastic nose with anteverted nares, long philtrum and micrognathia. Markedly prominent knee joints and shoulder joints with dumbbell-shaped femora on radiography were present. There was no definite case of Stickler syndrome in the family. But the mother showed a tiny triangular cleft along the inferior margin of the upper lip. She also had large prominent eyes without any ocular problem.

In contrast to mitral valve prolapse evident on echocardiography in Stickler syndrome patients, reported in 25-45% of cases ^{11,12}, our patient on echocardiographic examination revealed a small ostium secundum type of ASD with all other parameters normal. Cardiac defects are a minor feature of Stickler syndrome.

Genetic tests are not routinely available because of their high cost, complexity and high number of genes involved. Therefore a correct initial diagnosis is essential so that further investigations can be objectively carried out. COL11A1 mutations are the commonest accounting for 75% of cases of Stickler syndrome (Type I) with Type I membranous vitreous abnormalities and normal to slight hearing impairment¹³. COL11A1 is tested in patients with Type II ‘beaded vitreous phenotype’ and early onset sensorineural hearing loss. Craniofacial abnormalities in Stickler syndrome Types I & II are restricted to cleft palate only while Type III exhibits cleft palate as part of the Pierre Robin sequence¹⁴. Types I & II are characterized by mild degenerative changes in the joints with joint hypermobility, while type III is marked by early onset osteoarthritis¹⁵ (15% prevalence before 20 years of age⁵). Accordingly COL11A2 may be tested in patients with craniofacial defects, joint symptoms and hearing loss but no vitreous abnormalities⁵.

Irrespective of methods used in genetic testing, mutations are identified in only 50% of patients with Stickler syndrome⁵. Keeping in view the common associations between the clinical and genetic profile, this 40 day-old infant with a Pierre Robin sequence (including cleft palate), neonatal onset osteoarthritis and joint stiffness, pronated feet, marfanoid habitus of both the hands (and feet) and absence of vitreoretinal abnormalities, probably had clinical features suggestive of type III Stickler syndrome due to mutation in the COL11A2 gene. Our baby however showed other features of severe ocular disease such as large prominent eyes with megalocornea and glaucoma¹¹.

The diagnosis of Stickler syndrome is often missed or made late. Early diagnosis is nevertheless crucial to anticipate the osteoarticular complications, prevent or limit visual loss, providing hearing aids at the earliest, screen family members, optimize neonatal management and offer genetic counselling to provide definitive ‘recurrence counselling’ for families (50% in Stickler syndrome vs 2.3% in isolated cleft palate)¹⁶.

REFERENCES.

- [1] Snead MP, Yates JR. Clinical and molecular genetics of Stickler syndrome. *J Med Genet* 1999;36:353–9
- [2] Robin NH, Tarvin Moran R, Warman M. Stickler syndrome. In: Gene Reviews. NCBI Bookshelf funded by the NIH. University of Washington, Seattle; 2005 (www.ncbi.nlm.nih.gov).
- [3] Van Camp G, Snoeckx RL, Hilgert N, et al. A new autosomal recessive form of Stickler syndrome is caused by a mutation in the COL9A1 gene. *Am J Hum Genet* 2006;79:449–57.
- [4] Stickler GB, Belau PG, Farrell FJ, et al. Hereditary progressive arthropathy. *Mayo Clinic Proc* 1965;40:433–55.
- [5] Couchouron T, Masson C. Early-onset progressive osteoarthritis with hereditary progressive ophthalmopathy or Stickler syndrome. *Joint Bone Spine* 2011;78(1):45e9.
- [6] Soulier M, Sigaudy S, Chau C, Philip N. Prenatal diagnosis of Pierre Robin sequence as part of Stickler syndrome. *Prenat Diagn* 2002;22:567e8.
- [7] Evans AK, Rahbar R, Rogers GF, Mulliken JB, Volk MS. Robin sequence: a retrospective review of 115 patients. *Int J Pediatr Otorhinolaryngol* 2006;70:973e80.
- [8] Elzen APM, Semmekrot BA, Bongers EMHF, Huygen PLM, Marres HAM. Diagnosis and treatment of the Pierre Robin sequence: results of a retrospective clinical study and review of the literature. *Eur J Pediatr* 2001;160:47e53.
- [9] Rose PS, Levy HP, Liberfarb RM, et al. Stickler syndrome: clinical characteristics and diagnostic criteria. *Am J Med Genet* 2005;9999:1e9.
- [10] Stickler GB, Hughes W, Houchin P. Clinical features of hereditary progressive arthro-ophthalmopathy (Stickler syndrome): a survey. *Genet. Med.* 2001; 3: 192–6.
- [11] Lee KH, Hayward P. Retrospective review of Stickler syndrome patients with cleft palate 1997-2004. *ANZ J Surg* 2008; 78: 764-766.
- [12] Liberfarb RM, Goldblatt A. Prevalence of mitral-valve prolapsed in the Stickler syndrome. *Am. J. Med. Genet.* 1986; 24:387–92.
- [13] Freddi S, Savarirayan R, Bateman JF. Molecular diagnostic of Stickler syndrome: a COL2A1 stop codon mutation screening strategy that is not compromised by mutant mRNA instability. *Am J Med Genet* 2000;28:398–406.
- [14] Rose PS, Ahn NU, Levy HP, et al. The hip in Stickler syndrome. *J Pediatr Orthop* 2001;21:657e63.
- [15] Li K, Thorne C. Adult presentation of Stickler syndrome type III. *Clin Rheumatol* 2010;29:795e7.
- [16] Kronwith SD, Quinn G, McDonald DM et al. Stickler’s syndrome in the Cleft Palate Clinic. *J. Pediatr. Ophthalmol. Strabismus* 1990; 27: 265–7.