

## A comparative study of fine needle aspiration cytology, trucut biopsy and histopathological examination in breast lumps

Dr.S.Sujith Kumar.M.S.<sup>1</sup>, Dr. R.Diana Grace .M.D.,<sup>2</sup>  
Dr.K. Dhinesh Babu. M.S.<sup>3</sup>, Dr.M.Bhaskar.M.S.<sup>4</sup>

<sup>1</sup>Associate professor , Dept of General Surgery, Karpagavinayaga Institute of Medical Sciences &Research centre, Kanchipuram Dt , TamilNadu.

<sup>2</sup>Assistant professor , Dept of Paediatrics, Govtvellore medical college & Hospital, Vellore , TamilNadu.

<sup>3</sup>Assistant professor ,Dept of General Surgery, Karpagavinayaga Institute of Medical Sciences &Research centre, Kanchipuram Dt , TamilNadu.

<sup>4</sup>Professor&HOD ,Dept of General Surgery, Karpagavinayaga Institute of Medical Sciences &Research centre, Kanchipuram Dt , TamilNadu.

---

### Abstract:

**Aims:** To compare the results of Fine needle aspiration cytology ( FNAC) and trucut needle biopsy (TCNB) in breast lumps with histopathological examination in Karpagavinayaga Institute of Medical Sciences & Research Centre , Tamilnadu.

**Design:** Prospective study

**Materials &Methods:** In this study , 65 patients having breast lumps were subjected to FNAC & TCNB as outpatients during the period from august 2014 to February 2015 were compared with tissue diagnosis. Variables like age , marital status , duration ,size , menstrual status & site were analysed using statistical analytical tests.

**Results:** FNAC gave the correct diagnosis in 89 % while TCNB gave correct diagnosis in 91 %.

**Conclusion:** This study showed almost equal detection rates by FNAC (89%) and TCNB (91%) when comparing with histopathological examination . This study concludes if FNAC gives diagnosis one can go and proceed with surgery. But, if FNAC is negative then plan for TCNB.

---

### I. Introduction

A lump in the breast whether benign or malignant results in anxiety for the patient and her family and the surgeon. Histological tissue diagnosis is a universally accepted means of definitive diagnosis. FNAC is gaining wide acceptance as it gives a rapid diagnosis and can be carried out in out patients services .

The trucut needle is a very handy instrument and it is almost replacing the incision or excision biopsy in the breast lump , as it can be carried out in outpatient services with minimal trauma.

In this study 65 patients having breast lumps , were subjected to FNAC &TCNB as outpatients and followed by operative treatment with a histological diagnosis , which were compared with tissue diagnosis(HPE). Aims of this study is to compare the results of FNAC and TCNB in breast lumps with HPE. Variables used in this study are age , menstrual status, marital status , site , size and duration of lump.

### II. Materials &Methods

Sixtyfive patients presenting to surgical department outpatient , were subjected to FNAC & TCNB . All the patients underwent surgery depending upon the report of the two methods and finally all the reports of the techniques were matched with histological report of the excised specimen.

#### FNAC – Materials :

Equipmentsrequired to do FNAC are needle (23 G, 0.6 -1mm external diameter & 2.5 to 5 cm long), 10 – 20 mm disposable syringe ,Cameco syringe pistol, gloves ,microscopic glass slide , fixative ( isopropyl alcohol) ,alcohol sponges , sterile gauze pads and sterile containers.[ Fig.1]

#### FNAC – Methods:

FNAC procedure explained cleanly to the patient and informed consent should be obtained . Prepare the area with the sterile swabs .Needle is inserted in to the lesion and aspiration done with multiple passes without taking the needle out . Then the aspirated material put in the glass slide and then smeared. Isopropyl alcohol is used as a fixative. Complications of FNAC are haematoma ,infection and dissemination of tumour.

**TCNB – Materials :**

Disposable trucut needle 16 G or 18 G which can be used for about 5 to 6 case . In this study , 18 gauge disposable trucut needle used. For local anaesthesia , 2ml disposable syringe, gloves and 2% xylocaine solution are needed.[Fig .2]

**TCNB – Methods:**

The palpable lesion is fixed and skin is cleaned and then local anaesthetic is infiltrated .The needle is inserted and as soon as the lump is reached , the needle is advanced . Once the inner needle is inside the mass the outer needle is pushed and the whole trucut withdrawn. The material inside the stilllet is taken and sent for HPE.

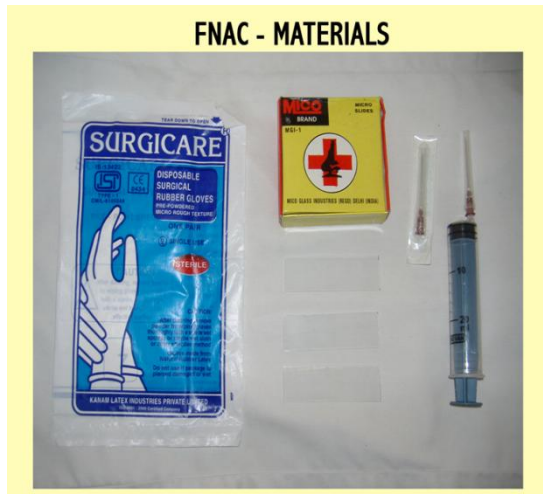

Fig.1 FNAC materials

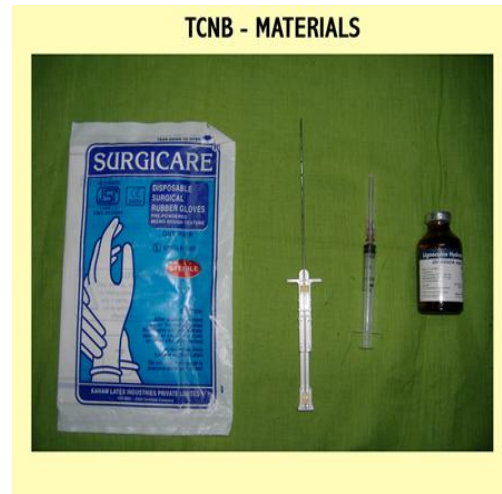

Fig.2 TCNB materials

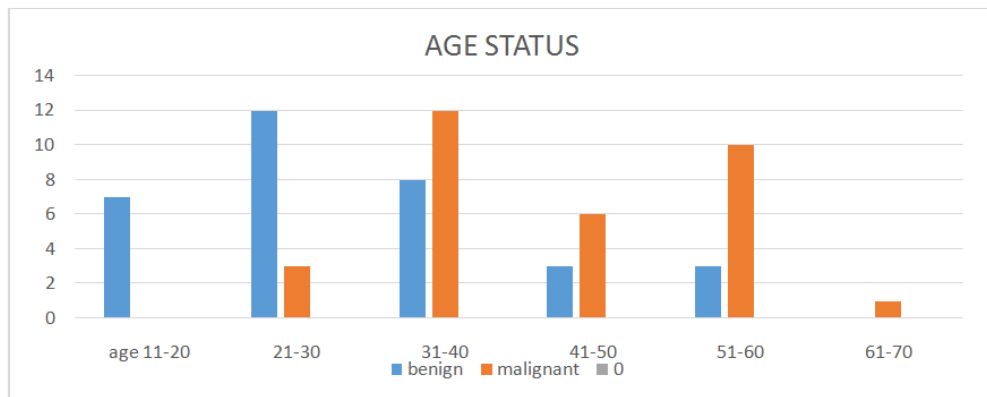


Fig .3 . Bar chart showing age status

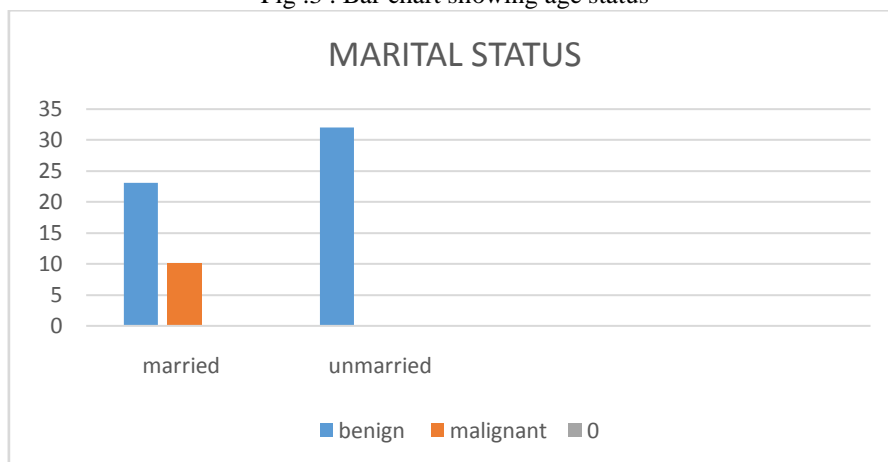


Fig.4. Bar chart showing marital status

### **III. Results**

Total number of patients in this study was 65. Out of a total 65 breast lump aspirations, final diagnosis was benign in 33 breast lumps and malignant in 32 breast lumps. Analysis of results was done in benign and malignant disease separately.

Out of 33 cases with benign breast 23 (56%) were married [fig 3]. Maximum incidence in this group was in the third decade (36%) [fig 3]. Whereas, in 32 malignant breast lumps all were married (100%) peak age incidence was in fourth decade (37%) [fig 4]. In duration of lump, among the benign breast lesions, peak group was less than 3 months (19 cases out of 33) and peak incidence of malignant lesions falls in the group for 4 – 6 months. Maximum incidence of benign and malignant breast lesions were in upper inner quadrant. Maximum incidence of benign and malignant breast lumps were 3-5 cm in size.

FNAC gave the correct diagnosis in 89%, while in 6 cases the result was false negative and in 1 case no opinion could be made. The sensitivity of FNAC is 90% and specificity is 100%. The positive predictive value is 100% while negative predictive value is 90%. In 1 patient, Unsatisfactory smear obtained, which was not taken for analysis. Overall accuracy of FNAC is 98% and that of is 97%.

TCNB gave the correct diagnosis in 91%, 2 false negative cases with 4 cases the biopsy was inadequate to give any diagnosis. The sensitivity and specificity of TCNB was 96% and 100% respectively. Similarly positive and negative predictive value was 100% and 96% respectively. In 4 cases, inadequate material obtained.

### **IV. Discussion:**

All agree on the necessity for prompt diagnosis of any breast lump. Hence workers all over the world are in search of a method which can give an early as well as accurate diagnosis. The incision or excision biopsy is a well accepted diagnostic method for breast lump, but both procedures are traumatic and require operation theatre facilities. In recent years, much of emphasis is laid on FNAC. Trucut needle is a simplified needle and needle biopsy can be performed in outpatient services.

FNAC is used extensively in the diagnosis of any lump. The high rate of false negative diagnosis and seedling of the cells along the needle track were the reasons that thought. Martin and Ellis introduced the technique in 1934, it is not well accepted. The visit of tumour dissemination has been shown to be more in surgical biopsy as compared to FNAC. The false negative result in carcinoma of the breast is 0-10%. The present study had the same false negative rate. The correct diagnosis by FNAC can be achieved in 80-95% cases<sup>1</sup>. In the present series the correct diagnosis by FNAC in 89% cases. There are many advantages of FNAC as it saves hospital admission, saves preliminary biopsy, saves frozen section and the patient known beforehand the type of operation.

TCNB<sup>2</sup> is safe and simple technique. The patients acceptance is high and apart from mild bruising no complication has been encountered. On positive diagnosis of malignancy by TCNB<sup>3</sup>, a definitive surgery can be planned as no false positive results are reported by this techniques. In the present study, there were 2 false negative cases and in 4 cases the biopsy material inadequate to give any diagnosis.

Both the techniques have their own advantages and draw backs. FNAC<sup>4</sup> is the most simple techniques and does not require any special instrument and the result can be obtained in a few hours time. The result of FNAC<sup>5</sup> should be correlated with clinical impression. TCNB is a histological diagnosis while FNAC is a cytological diagnosis where one has to report on few cells. TCNB<sup>6</sup> is comparatively more traumatic than FNAC as it may sometime bruise the breast.

### **V. Conclusion**

This study has helped to correlate cytological report, trucut needle biopsy and histopathology. The results of this study showed almost equal detection rates by FNAC (89%) and trucut biopsy (91%) when comparing with histopathological examination. Trucut biopsy, however was able to give a histological diagnosis and results correlated 100% with the final histology. However, in the setting of an outpatient clinic, we would like to recommend the use of FNAC for the diagnosis of suspicious breast lumps. With the results we would be able to advise the patient and recommend further treatment. However there is need for an excision biopsy to obtain a definitive histology before proceeding to definitive surgery as more have been cases of false positive results for FNAC.

Considering both techniques, it can be concluded that if FNAC<sup>8</sup> can find a diagnosis one can go ahead with a definitive operation. But, if in a clinically suspected case, FNAC is negative then one should then one should go for further investigation. In this concern the TCNB is ideal for getting the histological report. Even if TCNB report comes out to be negative, one should proceed with excisional or incisional biopsy and according to histopathological report, patient can be planned for further surgery.

### References

- [1]. Berner A , Davidson B , Sigstam E, Risbey B . FNAC Vs Core biopsy in diagnosis of breast lesions . *Diagn.Cytopathol.*2003 Dec ;29(6):344-8
- [2]. Poole GH, Willsher PC , Pinder SE, Robertson JF, Elston CW, Blamey RW Diagnosis of breast cancer with core biopsy and FNAC . *AustNZ J surg* 1996 Sep ;66(9):592-4
- [3]. Ballo MS ,Sneige N , can core needle biopsy replace fine needle aspiration cytology in the diagnosis of palpable breast carcinoma ? *Cancer* 1996;78: 773-7
- [4]. Dennison G , Anand R, Makar SH, Pain JA , A prospective study of role of FNAC and core biopsy in diagnosis of breast carcinoma. *Breast J.* 2003 Nov- Dec;9(6):491-3
- [5]. Homesh PG , ISSA MA, El – Sofiani HA . The Diagnostic accuracy of FNAC Vs core needle biopsy for palpable breast lump . *Saudi Med J* 2005 Jan ;26(1);42-6
- [6]. Westened PJ , Sever AR, Beckman-Devolder HJ , Liem SJ . A comparison of aspiration cytology and core needle biopsy in the evolution of breast lesions . *Cancer* 2001 Apr25 ;93(2);146-52
- [7]. NS Yong , KH Chia , WT Poh, CY Wong . Comparison of trucut with FNAC in diagnosis of breast carcinoma, *SMJ* 1999 Vol 40 (09)
- [8]. Shabot MM, Goldberg IM , Schick P, Nieberg R, Pilch YH . Aspiration cytology is superior to trucut needle biopsy in establishing the diagnosis of clinically suspicious breast masses. *Annals of Surgery* 1982, 196(2):122-126