

Fetal Harlequin Ichthyosis – A Case Report

Sunita Nayak¹, Suren Prasad Dash², Muktikanta Khatua³

¹Tutor, Department of Anatomy, SCB Medical College, Cuttack, Odisha, India

²Consultant Radiologist, Sahara Diagnostics, Courtpeta Square, Berhampur, Odisha, India

³Assistant Surgeon, District Headquarter Hospital, Koraput, Odisha, India

Abstract: Ichthyosis refers to a relatively uncommon group of skin disorders characterized by the presence of excessive amounts of dry surface scales. Autosomal recessive congenital ichthyosis (ARCI) encompasses several forms of nonsyndromic ichthyosis. Although most neonates with ARCI are collodion babies, the clinical presentation and severity of ARCI may vary significantly, ranging from harlequin ichthyosis, the most severe and often fatal form, to lamellar ichthyosis (LI) and (nonbullous) congenital ichthyosiform erythroderma (CIE). This is a case report of congenital (Harlequin) ichthyosis which is also called harlequin fetus, a lethal keratinising disorder. An externally thickened keratin layer of skin and diffuse plate like scales characterize it. Prenatal sonographic diagnosis has been described, with 2D findings of a persistently open mouth, echogenic amniotic fluid and fixed flexion deformity of the extremities. The 3D sonographic features have been described showing the morphological appearance typical of harlequin fetus, namely the open mouth with thick lips. The most definitive prenatal sonographic diagnosis of this condition is by 3D, which may not be done routinely without a suspicious 2D feature. In this case report, we suggest that the appearance of facial profile is the most easily seen and earliest 2D feature of this condition. We also reveal that the description of some of the 2D features described earlier is to be modified. 3D and 4D ultrasonography helped to diagnose this very rare condition.

Keywords: Distal contracture, Harlequin Ichthyosis, Keratinizing disorder.

I. Introduction

Ichthyosis is a heterogeneous family of at least 28, generalized, mostly genetic skin disorders. All types of ichthyosis have dry, thickened, scaly or flaky skin. In many types there is cracked skin, which is said to resemble the scales on a fish. The severity of symptoms can vary enormously, from the mildest, most common, type such as ichthyosis vulgaris which may be mistaken for normal dry skin up to life-threatening conditions such as harlequin type ichthyosis. Ichthyosis vulgaris accounts for more than 95% of cases.

Congenital ichthyosis, also called harlequin fetus is a lethal autosomal recessive disorder resulting from a keratinising disorder. An externally thickened keratin layer of skin and diffuse plate like scales characterizes it [1, 2]. Prenatal sonographic diagnosis has been described, with 2D findings of a persistently open mouth, echogenic amniotic fluid and fixed flexion deformity of the extremities [2-6]. The 3D sonographic features have been described showing the morphological appearance typical of harlequin fetus, namely the open mouth with thick lips [2, 6, and 7]. Here, we describe the sonographic appearance of face and flexion of toes on a case of harlequin ichthyosis.

II. Case Presentation

A 25-year-old woman, gravida 2 and para 1, abortion 1 was referred for a routine sonography at 29 weeks of gestation. Her first child was a preterm dead male baby. She was normal. Menstrual cycle: regular 3-4/28-30 days. On examination: Average body built with weight- 56 kgs. Pulse Rate- 89/min; Respiration rate- 44/min, Pallor +, Pedal edema- not present. Heart and chest- NAD. Per abdomen: height of uterus- 30 weeks; Cephalic presentation. Liquor not increased. Foetal movement- Felt. Her second pregnancy on sonography was 29 weeks. On investigation: Hb% -11.3mg/dl. FBS: 88mg/dl. VDRL- Non reactive, Blood group: 'O'+ve, Urine R/M- NAD. She was advised sonography for routine checkup which revealed the fetal biometry:

B.P.D	7.09cm	28 weeks	3 days
H.C	25.96cm	28 weeks	2 days
A.C	24.74cm	29 weeks	0 days
F.L	5.69cm	29 weeks	6 days

Gestational age corresponded to 28 weeks 06 days. Weight = 01 kg 344 gms +/- 200 gms. The amniotic fluid was echogenic, Amniotic fluid index was 16.01 cm. Placenta: anterior, high up with grade-II maturation. The feet of the fetus were abnormal. All the toes were hyperflexed and fixed in the same position. The fetal facial features of congenital ichthyosis were not recognizable clearly in 2D except facial profile defect. The facial profile defect assessed in sonography: facial anomalies include bilateral ectropion (complete eversion of

the eyelids with occlusion of the eyes) as shown in Fig. 1, eclabion (eversion of the lips) as shown in Fig. 2, absence of external ears and nasal hypoplasia. Both nostrils openings present anteriorly instead of inferiorly. Persistently fixed open mouth, Mandible Hypoplastic and flattened with flat facial profile, echogenic amniotic fluid, fixed flexion of the extremities, polyhydramnios, short digits, flat nose, thick lips, bilateral club feet, aplasia of the ears, shriveled hands that did not open and subnormal fetal movements. The 3D features are: very large open mouth with thick lips, flat nose and Mottled, breeched skin at face and limbs (Fig. 3). The foot to leg angle was normal. The feet showed fixed hyperflexion of the toes, corroborating the sonographic appearance. The movements of fetal limbs were seen. The fetal hands were clenched and opening of the fingers had not been recorded. No other anomaly detected.

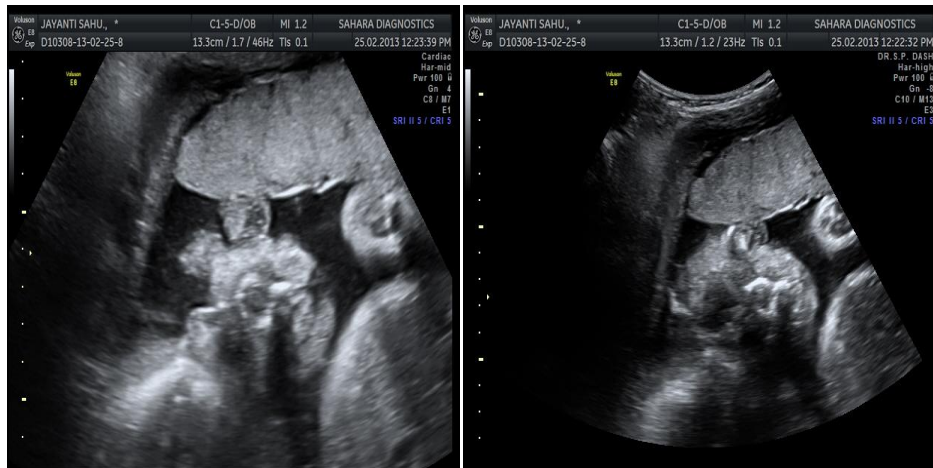


Fig. 1: Ultrasonographic findings (2D) - eversion of eyelids (ectropion) with occlusion of eyelids.

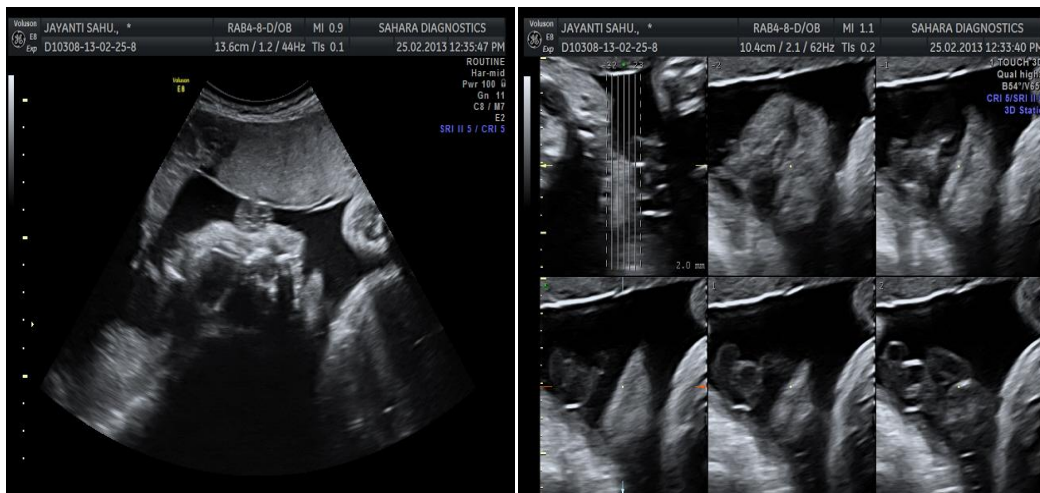


Fig. 2: Ultrasonographic findings (2D) and TUI (Tomographic Ultrasound Imaging) fixed opened wide mouth with eversion of lips (eclabion)

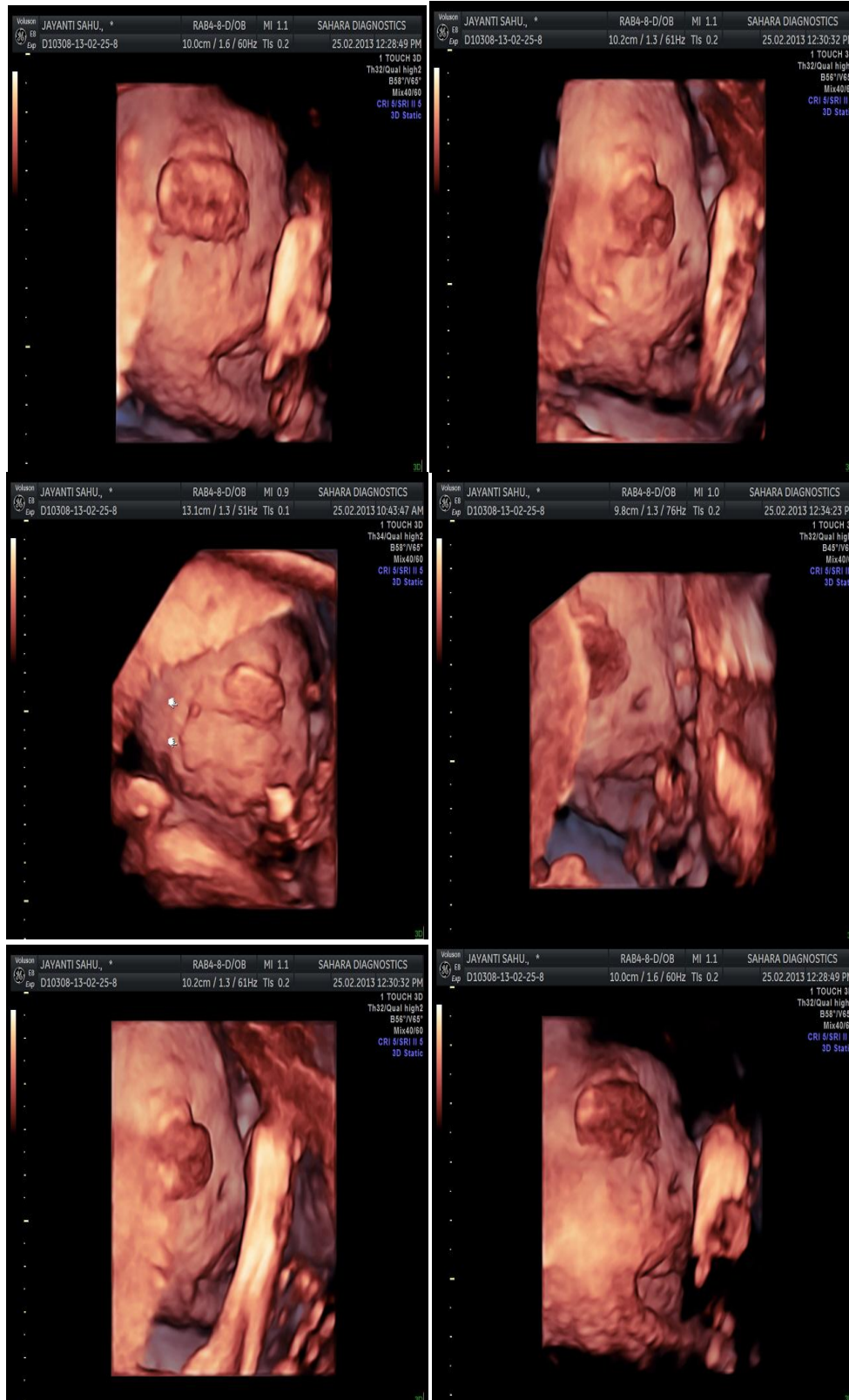


Fig. 3 showing 3D Face of the same fetus: very large open mouth with thick lips, flat nose, ectropion of eye lids and breeched skin at face (marked as hand).

The pregnancy was terminated after taking the patient's consent and proper counseling. The newborn showed classical features of congenital (Harlequin) ichthyosis (Fig.4). The condition of the patient was stable after abortion and she was discharged after proper advice.

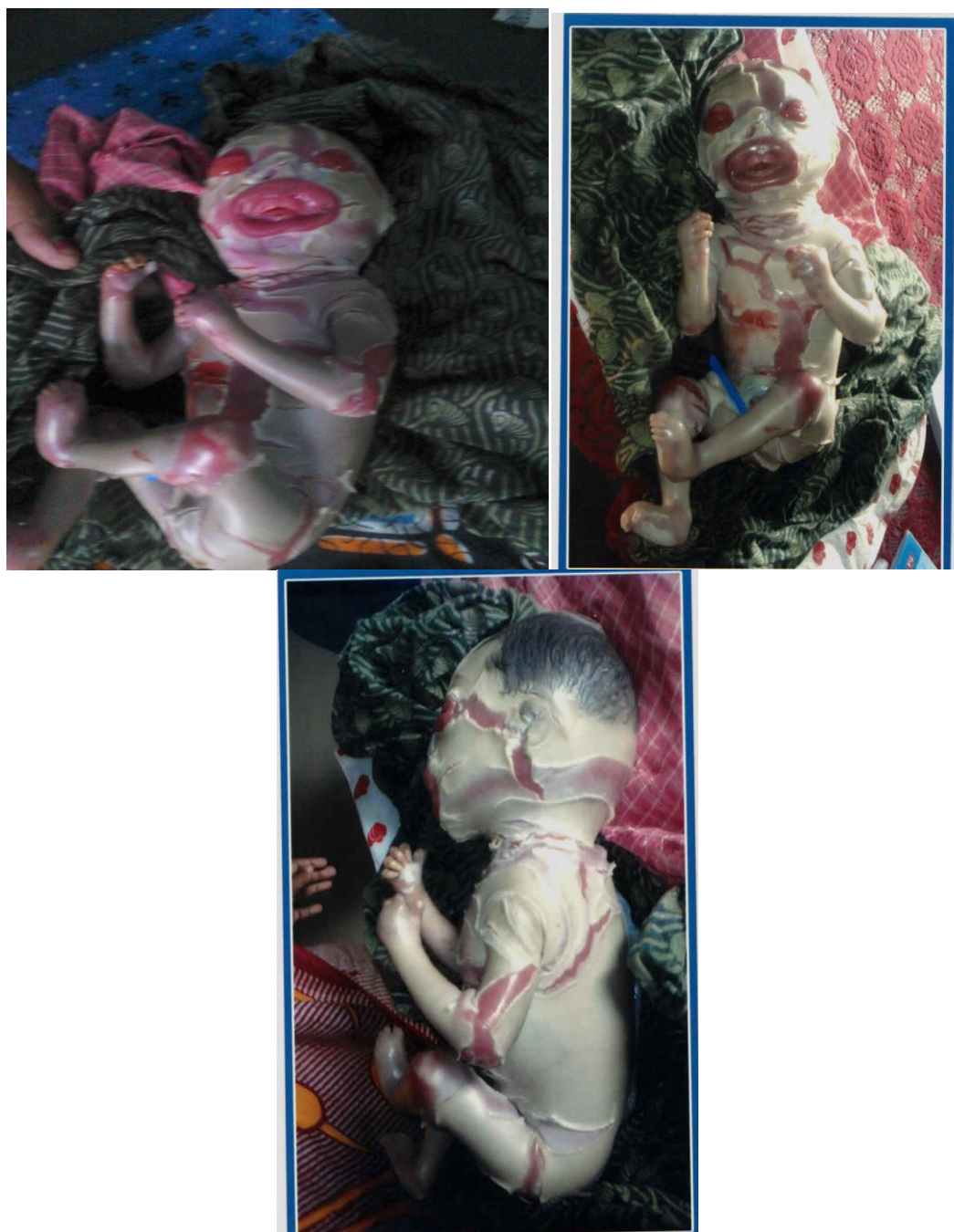

Fig. 4: Post delivery (follow up photographs)

III. Discussion

Congenital (harlequin) ichthyosis is a rare and devastating disorder. The appearance of the neonate can be shocking to parents and health care providers. Hence a prenatal diagnosis may help prepare them. Reverend Hart gave the first description of congenital ichthyosis in 1750. At birth the affected infant has a characteristic appearance of thick, whitish, armor-like skin, criss-crossed by deep red grooves often producing diamond-shaped forms resembling a harlequin costume [8, 9]. Facial anomalies include bilateral ectropion (complete eversion of the eyelids with occlusion of the eyes), eclabion (eversion of the lips), absence of external ears and nasal hypoplasia. The limbs are short and contained in a rigid sheath with hypoplastic fingers, toes and nails. Globally, the newborn appears to be encased in a tight, parchment-like membrane, which allows little movement

and holds the limbs in a semi flexed position. The mouth remains permanently open and the infant is unable to suckle properly. Despite specialized treatment, death generally occurs within the first weeks of life due to skin infection. With close monitoring of the skin and eyes and treatment with vitamin A [10], survival has been prolonged, in one case until 22 months [11] in another until 3 years [12] and in another until 9 years [10], although the histology in this case was doubtful and perhaps indicative of a different type of ichthyosis.

In the human fetus, cornification of the skin begins between 14 and 16 weeks gestation. Under light microscopy, skin biopsies from harlequin fetuses show hyperkeratosis with hypertrophy of the horny layers measuring up to 10 times the normal thickness. Congenital ichthyosis is an autosomal hereditary disorder affecting both males and females. Recessive transmission is generally accepted [13-15] although certain teams have suggested a dominant component [16]. Parents who have already had an affected child have a 25 % risk of recurrence in each pregnancy [13].

The first case of antenatal diagnosis was reported in 1983 [17]. Fetoscopy was used to obtain a skin biopsy in a consanguineous pregnancy (first cousins) with a history of two previously affected infants. Diagnosis by skin biopsy can be established at 20-22 weeks gestation, although recently, diagnosis was achieved at 17 weeks gestation using electron microscopy of pillous follicles, whose cornification occurs a few weeks before that of the epidermis [18].

Prenatal 2D sonographic features of this condition have been described [2-7]. The features included a persistently fixed open mouth, echogenic amniotic fluid, fixed flexion of the extremities, polyhydramnios, short digits, flat nose, bilateral club feet, aplasia of the ears, shriveled hands that did not open, flat face profile, thick lips and subnormal fetal movements. A definite diagnosis was not offered based on these features. Recently, 3D features of this condition have been described in 4 fetuses: three in unsuspected cases and one in second pregnancy of the mother who had an affected fetus earlier, the latter being one of the three unsuspected cases previously described. A definite diagnosis was offered in all these 4 fetuses leading to termination of fetuses at 30 [7], 32 [6], 30 [2] and 25 [2] weeks. The 3D features described by these authors are very large open mouth with thick lips, flat nose and mottled skin. Of these 4 fetuses, 3 were described by same group of authors [2-7]. The earliest sonographic diagnosis by 3D was at 22 weeks [2], made in the follow up of a second pregnancy after a first pregnancy with the same condition. In this case a scan was done at regular intervals of 15 days from early pregnancy. In unsuspected pregnancy the earliest diagnosis was by 3D at 30 weeks [2-7]. The 3D was done after suspicious features were seen on 2D. Bongain, et al [2] have concluded that when there are suggestive features on 2D ultrasound, 3D ultrasound should be done to confirm the diagnosis.

Of the 2D features the most described feature was the flat face, which was also the earliest feature described in the fetus at 22 weeks, which was followed up at regular intervals from early gestation. In unsuspected fetuses the same feature was picked up only at or after 30 weeks. Another feature described is fixed open mouth. A more specific description of this feature is, everted thick lips, resulting in a large open mouth, the lips failing to appose. However, the opening and closing movements of the lower jaw are present as seen in the newborn harlequin baby described here. Again, regarding the extremities, fixed deformities and subnormal movements are both described. Since limb movements are present in the newborn described here and the skin anomaly is less pronounced in the terminated fetus at 25 weeks, it could be concluded that good movements of the fetus are present in early pregnancy. So it is clear that the only useful 2D feature is a flat facial profile.

The 2D features of the feet described in earlier reports were short toes at 28 weeks 06 days. We noted the same appearance in the published pictures of the fetuses, which were prematurely delivered at 28 weeks 06 days but were not described by the authors of these articles. This feature of the toes has not been described in any other condition so far. Hence, the fixed extremity, hyperflexed toes seems to be the earliest and easily recognizable 2D feature of this condition of congenital (harlequin) ichthyosis.

IV. Conclusion

The 3D sonography is the most definitive method of prenatal diagnosis of congenital (harlequin) ichthyosis. But there has to be a suggestive 2D feature, which will recommend a 3D examination. As per review of the available literature, the only useful 2D feature of this condition is a flat facial profile, which is difficult to recognize and is picked up only very late in gestation, unless it is suspected because of a previous sibling affected by the same condition. The feature of fixed extremity, hyperflexed toes, described in this article, is the earliest, definitive and easily detectable 2D feature of congenital ichthyosis. This feature is more significant since it can be seen even in pregnancies with negative history.

References

- [1]. Akiyama M. The pathogenesis of severe congenital ichthyosis of the neonate. *J Dermatol Sci* 1999; 21:96-104.
- [2]. Bongain A, Benoit B, Ejnes L, Lambert JC and Gillet JY. Harlequin fetus: three-dimensional sonographic findings and new diagnostic approach. *Ultrasound Obstet Gynecol* 2002; 20:82-85.
- [3]. Meizner I. Prenatal ultrasonic features in a rare case of congenital ichthyosis (harlequin fetus). *J Clin Ultrasound* 1992; 20:132–134.
- [4]. Watson WJ, Mabee LM Jr. Prenatal diagnosis of severe congenital ichthyosis (harlequin fetus) by ultrasonography. *J Ultrasound Med* 1995; 14:241–243.
- [5]. Montague E, Fox R, Mann R. Intra-amniotic debris identified at ultrasound scanning: a feature of congenital ichthyosis. *Ultrasound Obstet Gynecol* 1997; 9:350–351.
- [6]. Nidhi V, Burton R, Smith-Levitin M. Three-dimensional Sonographic Findings in Congenital (Harlequin) Ichthyosis. *J Ultrasound Med* 22:737– 739, 2003.
- [7]. Benoit B. Three-dimensional ultrasonography of congenital ichthyosis. *Ultrasound Obstet Gynecol* 1999; 13:380.
- [8]. Plocoste V, Bonneau D, Deshayes M, De Giacomoni P, Kibler MP, Berthier M, Magnin G. Le syndrome du bébé arlequin. *J Gynecol Obstet Biol Reprod* 1992; 21:247–50.
- [9]. Kouskoukis C, Minas A, Tousimis D. Ichthyosis congenital fetalis. *Int J Dermatol* 1982; 21:347–8.
- [10]. Roberts LJ. Long term survival of a harlequin fetus. *J Am Acad Dermatol* 1989; 21:335-9.
- [11]. Prasad RS, Pejaver RK, Hassan A, Al Dusari S, Wooldridge MA. Management and follow up of harlequin siblings. *Br J Dermatol* 1994; 130:650-3.
- [12]. Lawyor F. Harlequin baby: inheritance and prognosis. *Br J Dermatol* 1987; 117:528.
- [13]. Bottani A. On the inheritance of harlequin ichthyosis. *Prenat Diagn* 1994; 14:1099.
- [14]. Williams ML, Elias PM. Genetically transmitted generalised disorders of cornification: the ichthyoses. *Dermatol Clin* 1987; 5:155-78.
- [15]. Unamuno P, Pierola JM, Fernandez E, Roman C, Velasco JA. Harlequin fetus in four siblings. *Br J Dermatol* 1987; 116:569-72.
- [16]. Suzumori K, Kanzaki T. Prenatal diagnosis of harlequin ichthyosis by fetal skin biopsy: report of two cases. *Prenat Diagn* 1991; 11:451-7.
- [17]. Blanchet-Bardon C, Dumez Y, Labbé F, Lutzner MA, Puissant A, Henrion R, Bernheim A. Prenatal diagnosis of herlequin fetus. *Lancet* 1983; 8316:132.
- [18]. Akiyama M, Suzumori K, Shimizu H. Prenatal diagnosis of harlequin ichthyosis by the examination of keratinized hair canal and amniotic fluid cells at 19 weeks' estimated pregnancy. *Prenat Diagn* 1999; 19:167-71.