

A Comparative Study of Functional Outcome of Fracture Neck Femur Treated With Cemented Bipolar and Bipolar With Bone Graft

Dr.Eknath.D. Pawar (M.S. Ortho)¹, Dr. Sandeep .S. Chaudhary (M.S. Ortho) ,²
Dr.Gajanan.M. Kathar(M.S. Ortho)³ Dr.Ganesh .M.Nalge (M.S. Ortho),⁴

Associate Professor , Government Medical College ,Aurangabad.

3rd year Resident in Orthopaedics, Government Medical College , Aurangabad

Assitant Professor, Government Medical College , Aurangabad.

2nd year Resident in Orthopaedics, Government Medical College , Aurangabad

Abstract: Whether to cement the hemiarthroplasty in fracture neck femur is a matter of debate . Though cementing gives good initial fix it has the risk of bone intraoperative hypotension .On the other hand uncemented implants are associated with periprosthetic fractures and are expensive . Femoral head can be use as source of autologous bone graft to fill the medullary cavity of femur .50 patients of fracture neck femur were randomly distributed into 2 groups of 25 each . In group A we did bipolar with bone graft while in Group B we did cemented bipolar.At the end of one year, in the Bone Graft group 3 patients (12%) had excellent results; 17 patients (68%) had good results; 4 patients (16%) had fair results and 1 patient(4%)had poor result; whereas in the cemented group 4 patients (16%) had excellent results; 19 patients (76%) had good results; 2 patients (8%) had fair results. There was no statistically significant difference in the functional outcome between cemented bipolar and bipolar with bone graft.

Keywords: Bipolar hemiarthroplasty, bone graft, cemented.

I. Introduction

The number of femoral neck fractures increases as age advances. Surgery is the mainstay of treatment for displaced femoral neck fractures, hemiarthroplasty being a common operation in elderly patients. Hemiarthroplasty could be cemented or uncemented. Whether to cement the hemiarthroplasty or not is a perennial argument¹. Cementation of the prosthesis achieves good initial fix in an osteoporotic bone, however arthroplasty using a cemented implant may be associated with increased mortality compared with an arthroplasty using an uncemented implant, as it has the risk of bone marrow and fat embolization with resulting intraoperative hypotension and increased incidence of deep vein thrombosis².

An uncemented implant may be associated with complications such as stress shielding and a higher risk of periprosthetic fracture. While using an uncemented implant bone grafting of the femoral canal can be done by using the autologous cancellous bone graft of the head of femur .This is cost effective method of making the implant press fit without introducing foreign material.Though many uses of bone graft have been studied ,its use in primary hemiarthroplasty has never been studied.Autologous bone graft have the least chance of immunological reaction and rejection³. As autologous cancellous bone graft of the femoral head is easily available at primary hemiarthroplasty we intend to study the functional recovery following bipolar with bone graft.

II. Research Objectives

1. To compare relief of pain and range of motion and functional recovery using Harris Hip Score following Cemented Bipolar and Bipolar with Bone Graft.
2. To study implant related complication and chances of reoperation following cemented bipolar and bipolar with bone graft.
3. To compare intraoperative time and blood loss

Review of Literature:

Whether to cement the hemiarthroplasty or not is a perennial argument¹In 1958, Sir John Charnley⁴ used PMMA bone cement to anchor femoral head prostheses in the femur, as is done in modern-day joint arthroplasty

For over 40 years, polymethylmethacrylate (PMMA) based bone cement, commonly referred to as acrylic bone cement, and has been used for fixation of total joint replacement prostheses to periprosthetic bone

tissue. But using bone cement has certain disadvantages. Bone cement implantation syndrome (BCIS) is poorly understood. It is an important cause of intraoperative mortality and morbidity in patients undergoing cemented hip arthroplasty. It is characterized by a number of clinical features that may include hypoxia,^{5,6} hypotension,^{5,6,7} cardiac arrhythmias,² increased pulmonary vascular resistance (PVR),^{2,7} and cardiac arrest.²

In a reaction to problems incident to the use of the acrylic cement, efforts were made to promote a more biological fixation by eliminating the cement altogether. Beginning in the 1970s and continuing through the end of the century, orthopaedic surgeons have attempted to eliminate bone cement as a secondary fixation substance and obtain direct fixation of bone to the implant.⁸ Modern day uncemented press fit implants are expensive. Hence we tried use of bone graft in primary hemiarthroplasty

Phemister^{9,10} introduced the term creeping substitution. He believed that transplanted bone was invaded by vascular granulation tissue, causing the old bone to be resorbed and subsequently replaced by the host with new bone. In cancellous autografts the vascular response is much greater than in cortical grafts. The entire cancellous bed may become completely revascularized within approximately 1 to 2 weeks¹¹. The cell population of this environment comprises predominantly osteoblasts. It is not known if these cells are produced from the recipient site or if they are the descendants of cells transplanted with the graft itself¹². In any case these cells line the scaffold presented by the trabeculae of the graft and deposit a seam of osteoid that surrounds and entraps the original dead bone. This entrapped dead bone is eventually resorbed by osteoclasts. Radio graphically the cancellous bone first becomes more dense as the new bone forms on the old trabeculae and then becomes less dense as the osteoclastic remodeling takes place.

III. Materials And Methods

The present prospective study was conducted in between the period of July 2012 to December 2014. Patients were divided into two groups. Group A underwent bipolar with bone graft and group B underwent cemented bipolar. The permission of the ethical committee was obtained. Patients were randomly selected into either group; the following observations were made from the data collected.

All patients of intracapsular neck femur fracture with Age more than or equal to 60 years, preinjury status ambulatory, willing for operation and cooperative for physiotherapy were included in the study.

Patients with age less than 60 years, Multiple fracture with shaft femur fracture or with acetabulum fracture or with fracture trochanter, severely moribund, open fracture uncontrolled diabetes mellitus and not willing for operation were excluded from the study.

Patients were admitted to the ward. Detailed history was taken with particular emphasize on mode of injury and associated medical illness. In depth, clinical assessment was carried out in each case.

In all patients preoperatively skin traction with appropriate weight was applied, to the fractured lower limb, with the aim of relieving pain, preventing shortening and to reduce unnecessary movements of the injured limb. Anteroposterior radiographs of the affected hip joint were taken for all the patients. Routine blood investigations for anaesthesia fitness were done. Patients with associated disorders like Diabetes Mellitus, Hypertension, Chronic Obstructive Pulmonary Disease, Cerebrovascular Accident, Ischaemic Heart Disease, Anaemia, were evaluated and treated by physician in the early period of hospitalization. The patients were taken up for surgery only after they became medically fit for the surgical procedure.

Intravenous antibiotics were given an hour before the surgery. All surgeries were performed on an elective basis using standard aseptic precautions. Surgery was performed under spinal or general anaesthesia

Operative procedure was performed in lateral position with the patient lying on the unaffected side. For all our patients posterolateral approach was used, Moore's Approach (Southern exposure).

In case of cemented group cementing of the femoral canal was done by using cement gun and then prosthesis was inserted into the femoral shaft in about 5-10 degree of anteversion and impacted into the femur.

In case of the bone graft group the extracted femoral head was taken and cartilage was removed. Then head was nibbled into pieces and single large piece was introduced into the canal to act as restrictor and then prepared cancellous bone graft was packed into the femoral canal and the prosthesis was introduced.

Post operative monitoring of temperature, pulse, blood pressure and respiration rate was done. Intravenous antibiotics were continued for 5 days followed by oral antibiotic for another 5 days. Drain removal was done after 48 hours.

Patients were made to sit up on the second day, encouraged to perform static and dynamic quadriceps exercise. Weight bearing was started depending on patients pain tolerance in the first week in cemented group. Weight bearing in bone grafted group was started after 21 days.

Patients were followed up at an interval of 6 weeks, 3 months, 6 months, and 12 months and functional outcome was analyzed by modified Harris hip scoring system.

IV. Data Analysis and Findings

Between July 2012 and November 2014, 50 elderly patients with displaced femoral neck fractures were treated surgically with hemiarthroplasty at our hospital.

The average age of the patients in our bone Graft group was 70.36 and cemented group was 70.04 years. In our series there were 27(54%) female patients and 23 male patients. . Out of 50 cases 27 cases (54%) were on the left side and 23 cases (46%) are on the right. Majority of the patients(45 patients out of 50 i.e.90%) had minimal trauma most of them slipped and fell down on flat ground or in bathroom and were not able to walk or stand.

In the Bone Graft group the mean duration of surgery was 84 minutes where as in the cemented group the mean duration of surgery was 101.2 minutes. The difference between the two groups was significant (p value< 0.0001)

In the Bone Graft group the mean amount of blood loss was 188.95millilitres, and in cemented group the mean amount of blood loss was 288 millilitres. The difference between the two groups was significant (p value< 0.00001)

The complications were distributed in both groups. In the Bone Graft group we had one case (4%) of deep infection detected on day 10 for which debridement was done. There were two cases (8%) of superficial infection which responded to antibiotics with regular dressing & one case (4%) of bed sore was noted. In the cemented group we had one case (4%) of dislocation on the 14th day postoperative day, for which open reduction was done under general anaesthesia. One case each of bed sore (4%) and superficial infection (4%) which responded to antibiotics and dressing were seen. One case (4%) of intraoperative calcar fracture was noted and hence weight bearing was delayed in that patient.

In the Bone Graft group the mean duration of full weight bearing was 21.68 days where as in the cemented group the mean duration of full weight bearing was 5.72 days. The difference between the groups was significant (P= 0.00001)

As per the Harris hip scoring system the pain component was measured, and accordingly in the Bone Graft group 3 patients (12%) had no pain; 17 patients (68%) had slight pain and 5 patients (20%) had mild pain. Where as in the cemented group 5 patients (20%) had no pain; 19 patients (76%) had slight pain and one patient (4%) had mild pain at one year follow up. The result was statistically insignificant(p value =0.075)

In the Bone Graft group 6 patients (24%) had no limp; 19 patients (76%) had slight limp; whereas in the cemented group 9 patients (36%) had no limp; 15 patients (60%) had slight limp and 1 patients (4%) had moderate limp. The result was statistically insignificant(p value=0.574)

In the Bone Graft group 17 patients (68%) had range of movement between 211°-300°; 8 patients (32%) had range of movement between 161°-210° ; whereas in the cemented group 12 patients (48%) had range of movement between 211°-300°; 13 patients (52%) had range of movement between 161°-210°. The result was statistically insignificant(p value =0.158)

In the Bone Graft group 3 patients (12%) had excellent results; 17 patients (68%) had good results; 4 patients (16%) had fair results and 1 patient(4%) had poor result; whereas in the cemented group 4 patients (16%) had excellent results; 19 patients (76%) had good results; 2 patients (8%) had fair results. the result was not significant (p value= 0.368).

V. Discussion

We undertook the study to compare hemiarthroplasty using bone graft of the femoral head with cemented hemiarthroplasty. No study in literature has been reported Previous studies have compared cemented hemiarthroplasty with the uncemented one. Autogenous bone grafts are considered as the gold standard for bone replacement, mainly because they offer minimum immunological rejection, complete histocompatibility and provide the best osteoconductive, osteogenic and osteoinductive properties^{3,13}. Autograft from the iliac crest causes post operative pain, limp and morbidity. The average age incidence in our study was 70.20 years with a range of 60 to 82 years. our study was comparable to other studies like Wender Figved MD, et.al,¹⁴(70 years)R.J.K. Khan et.al,¹⁵(83 years)Jaimo Ahn MD, PhD, Li-Xing Man MD et.al,¹⁶(78 years).

In the Bone Graft group the mean duration of surgery was 84.00 minutes with a mean amount of blood loss of 188.95 millilitres, where as in the cemented group the mean duration of surgery was 101.2 minutes and mean amount of blood loss being 288 millilitres. The difference between the groups was significant. Wender Figved MD et al.¹⁴ reported duration of 70.2 min with a blood loss of 300ml in uncemented group and 82.6 min with a blood loss of 390ml in the cemented group. Jaimo Ahn MD, PhD, Li-Xing Man MD et al.¹⁶ in their study recorded two operative parameters of blood loss and surgical time was lower for the uncemented group. The weighted average blood loss was 476 mL for the cemented and 338 mL for the uncemented groups. Surgical time was greater for the cemented cohort than the uncemented (95 minutes versus 80 minutes, respectively).

In our study we had one case (4%) of periprosthetic fracture (calcar fracture) in the Cemented group. There was no intraoperative periprosthetic fracture in the bone graft group. Wender Figved MD et al¹⁴ reported

Intraoperative periprosthetic fracture one case (0.9%) in cemented group & 2(1.9%) in uncemented groups. R.J.K. Khan et al.¹⁵ reported three iatrogenic periprosthetic fractures, all occurring in the uncemented group. The number in our study was not statistically significant but studies have reported higher rates of intraoperative periprosthetic fracture in uncemented hemiarthroplasty. In our study we had one case of dislocation (4%) in cemented group which occurred on the fourteenth post-operative day. Open reduction of the dislocation was successfully done under general anaesthesia. Jameson et al.¹⁷ reported higher dislocation rate at 18 months in the cemented group (0.44% vs. 0.25%). Wender Figved MD et al.¹⁴ reported 5 cases of dislocation in each cemented (4.5%) & uncemented (4.6%) groups. The number was not statistically significant in our study but studies have reported higher rates of dislocations in cemented hemiarthroplasty. In our study we had two cases (8%) superficial infection in the bone Graft group and one (4%) superficial infection in the cemented group which responded to regular dressing and antibiotics. One (4%) case of deep infection was noted in the bone graft group on the 10th postoperative day for which debridement was done. Wender Figved MD et al.¹⁴ only one case of superficial infection (0.9%) in the cemented group. There was no mortality in our study. Despite the known physiological effect of cement upon the cardiopulmonary system, we found no clinical morbidity or mortality because of this in our study, as measured by a fall in blood pressure, irregular ECG tracing and fall in oxygen saturation. Our results matched results in other similar studies by Hansen et al.¹⁸ Jaimo Ahn MD et al.¹⁶ who compared complications, mortality and they did not find any statistically significant difference between the uncemented and the cemented group. In our study there was slightly more pain in the bone graft group but it was not of statistical significance. (p value=0.075) between the cemented and Bone Graft groups. Jaimo Ahn MD, PhD, Li-Xing Man MD et al.¹⁶ who noted persistence of pain did not reach statistical significance between uncemented and the cemented groups. Wender Figved MD et al.¹⁴ reported there were no differences in pain scores and use of analgesics. Hansen et al.¹⁸ did not find any statistically significant difference in pain score between the uncemented and the cemented group.

The results in our study did not show any statistical difference in the evaluation of limp, distance walked and use of walking aids. Other studies like Jaimo Ahn MD, PhD, Li-Xing Man MD et al.¹⁶; Wender Figved MD, et al.¹⁴; Hansen et al.¹⁸. which have compared uncemented and cemented groups also have similar results.

The mean Harris Hip Score in bone graft group was 84.52 at 1 year follow up; whereas in the cemented group the mean Harris Hip Score was 86.08 at 1 year follow up. There was no statistically significant difference in the functional outcome (P = 0.368) between the two groups in our study.

According to Wender Figved MD et al.¹⁴ 1 year Harris Hip Score results were equivalent in the cemented and the uncemented groups and there were no differences in ability to walk, use of analgesics, or place of living in both the groups.

According to Jaimo Ahn MD, PhD, Li-Xing Man MD et al.¹⁶ who compared cemented and uncemented cohorts postoperative mortality rates, overall complications, and pain were similar between the two cohorts.

According to S. Santini, et al.¹⁹ There was no significant difference between the 2 groups of patients regarding most variables.

Hansen et al.¹⁸ compared complications, reoperations and mortality and they did not find any statistically significant difference between the groups. Deangelis JP et al.²⁰ concluded in the treatment of non pathologic displaced femoral neck fractures, the use of cemented and uncemented femoral components is associated with similar functional outcome at 1 year. At 30-day, 60-day, and 1-year follow-ups, no clinically or statistically significant differences were found in mortality, disposition, need for assistance with ambulation.

According to SKS Marya²¹, R Thukral, R Hasan, M Tripathi cementless bipolar hemiarthroplasty for femoral neck fractures in the very elderly permits early return to pre-morbid life and is not associated with any untoward cardiac event in the perioperative period. It can be considered a treatment option in this select group.

VI. Conclusion

We found that hemiarthroplasty with bone graft of the femoral head is a good treatment option in elderly patients as it is cost effective and does not introduce any foreign material into the body. Also the known hazards of cementing are minimized. Revision surgeries when required at a later date are easier to perform in the bone graft group as they are associated with improved bone stock on the femoral side. Also removal of the implant and the cement during revision surgeries is difficult.

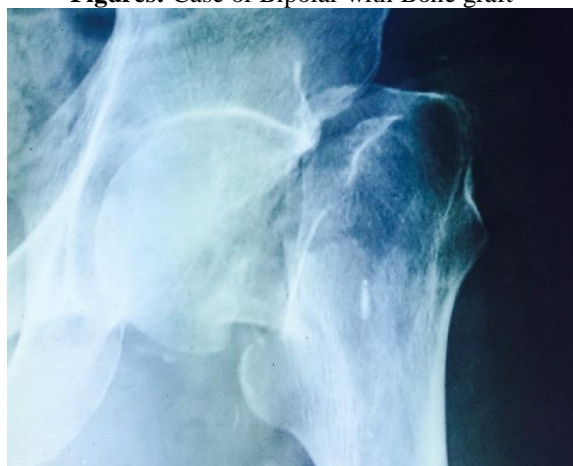Bipolar with bone graft can be considered as the best treatment option for femoral neck fractures in elderly

References

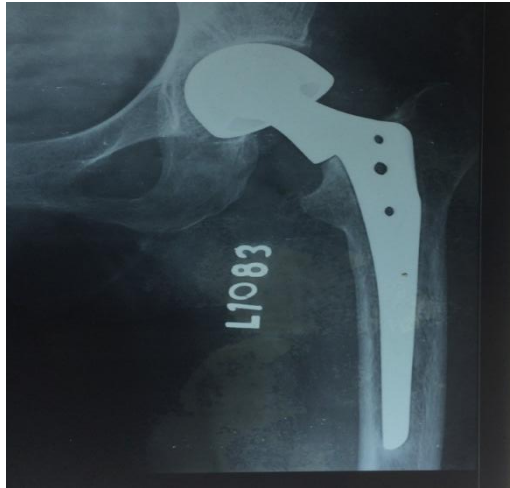
- [1]. Parker MJ, Gurusamy K. Arthroplasties (with and without bone cement) for proximal femoral fractures in adults. *Cochrane Database Syst Rev.* 2006;3:CD001706.
- [2]. Parvizi J, Holiday AD, Ereth MH, Lewallen DG. The Frank Stinchfield Award. Sudden death during primary hip arthroplasty. *Clin Orthop* 1999; 369 : 39-48.

- [3]. D, Shen FH, Goldberg EJ, An HS. Is autograft the gold standard in achieving radiographic fusion in one-level anterior cervical discectomy and fusion with rigid anterior plate fixation? *Spine* 2005; 30 : 1756-61
- [4]. Charnley J. Clinical experiences with self-curing acrylic cement. In: *Acrylic cement in orthopaedic surgery*. E & S Livingstone, Edinburgh (1970) p. 33-35
- [5]. Modig J, Busch C, Olerud S, Saldeen T, Waernbaum G. Arterial hypotension and hypoxaemia during total hip replacement: the importance of thromboplastic products, fat embolism and acrylic monomers. *Acta Anaesthesiol Scand* 1975; 19: 28-43
- [6]. Werner L. A response to 'Sudden deaths during hip hemiarthroplasty'. *Anaesthesia* 2003; 58: 922-3 Parry G. *Anaesthesia* 2004 Feb; 59: 200
- [7]. Wheelwright EF, Byrick RJ, Wigglesworth DF, et al. Hypotension during cemented arthroplasty. Relationship to cardiac output and fat embolism. *J Bone Joint Surg* 1993; 75: 715-23
- [8]. *Adult Hip, The, 2nd Edition Volume I > Section I - History of Hip Surgery > 1 - A History of Hip Surgery* Leonard F. Peltier
- [9]. Harkins HN, Phemister DB. Simplified Technic of Onlay Grafts. *JAMA*. 1937;109:1501
- [10]. Phemister DB. The Fate of Transplanted Bone and Regenerative Power of Its Various Constituents. *Surg Gynecol Obstet* 1914;19:303
- [11]. Albee :Evolution of bone graft surgery *Ann J. Surg* 1944;63:421-536
- [12]. Burchardt H: The biology of bone graft repair. *Clin Orthop Rel Res* 174:28, 1983
- [13]. Nandi S.K., Roy S, Mukherjee P, Kundu B, DeD.K. & Basu D. Orthopaedic applications of bone graft & graft substitutes: a review *Indian J Med Res* 132, July 2010 : 15-30
- [14]. Wender Figved MD, Vidar Opland MD, Frede Frihagen MD, Tore Jervidal MD, Jan Erik Madsen MD, PhD, Lars Nordsletten MD, PhD *Clin Orthop Relat Res* (2009) 467:2426-2435
- [15]. Khan RJ, MacDowell A, Crossman P, Datta A, Jallali N, Arch BN, Keene GS. Cemented or uncemented hemiarthroplasty for displaced intracapsular femoral neck fractures. *Int Orthop*. 2002;26:229-232.
- [16]. Jaimo Ahn MD, PhD, Li-Xing Man MD, MSc, SangDo Park MD, Jeffrey F. Sodl MD, Systematic Review of Cemented and Uncemented Hemiarthroplasty Outcomes for Femoral Neck Fractures, *Clin Orthop Relat Res* (2008) 466:2513-2518
- [17]. S Jameson, P James, A Rangan, S Muller, and M Reed; Cemented versus uncemented hemiarthroplasty for intracapsular fractured neck of femur - a national analysis of matched NHS patients; *J Bone Joint Surg Br Proceedings* 2012 94-B:29
- [18]. Hansen SK, Brix M, Birkelund L, Troelsen A: Can introduction of an uncemented, hydroxyapatite coated hemiarthroplasty for displaced femoral neck fractures be recommended? *Hip International*. 2010;20(1):109-114
- [19]. S. Santini, A. Rebeccato, I. Bolgan and G. Turi, Hip fractures in elderly patients treated with bipolar hemiarthroplasty: comparison between cemented and cementless implants. *Journal Of Orthopaedics And Traumatology* Volume 6, Number 2 (2005), 80-87
- [20]. Deangelis JP, Ademi A, Staff I, Lewis CG. Cemented versus uncemented hemiarthroplasty for displaced femoral neck fractures: a prospective randomized trial with early follow-up. *J Orthop Trauma*. 2012 Mar; 26(3):135-40.
- [21]. Marya SKS, Thukral R, Hasan R, Tripathi M *IJO*(2011)VOL 45 Issue3:236-242

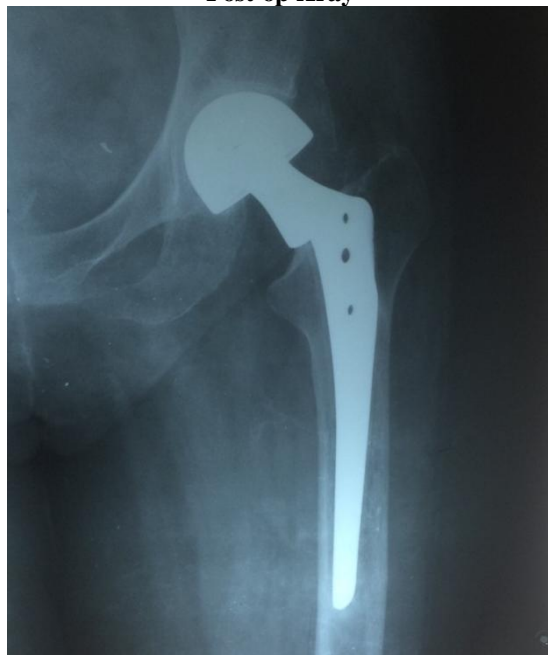Figures: Case of Bipolar with Bone graft



Pre op Xray

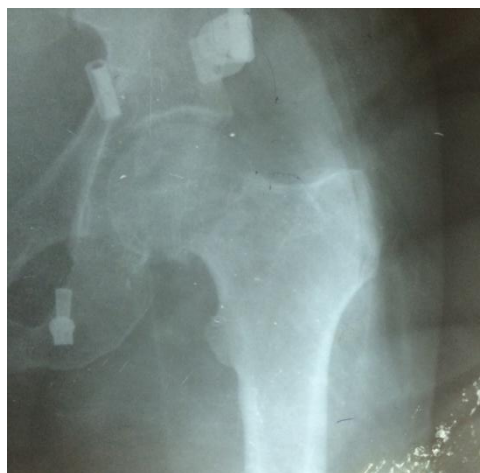

Post op Xray

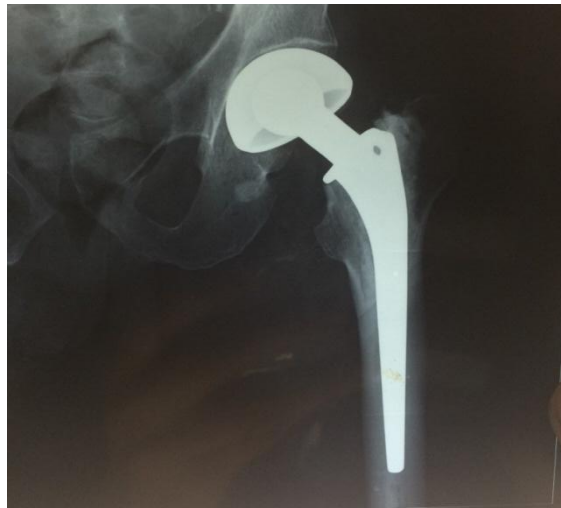

Post op 1 year

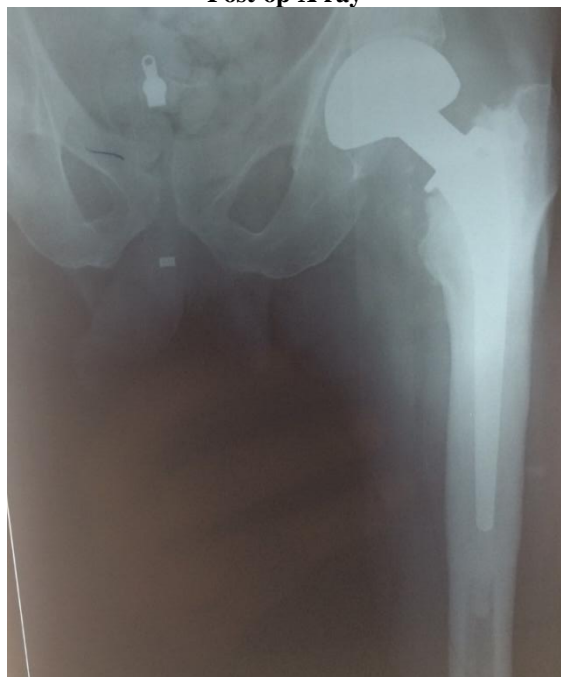Case of Cemented Bipolar



Pre op Xray

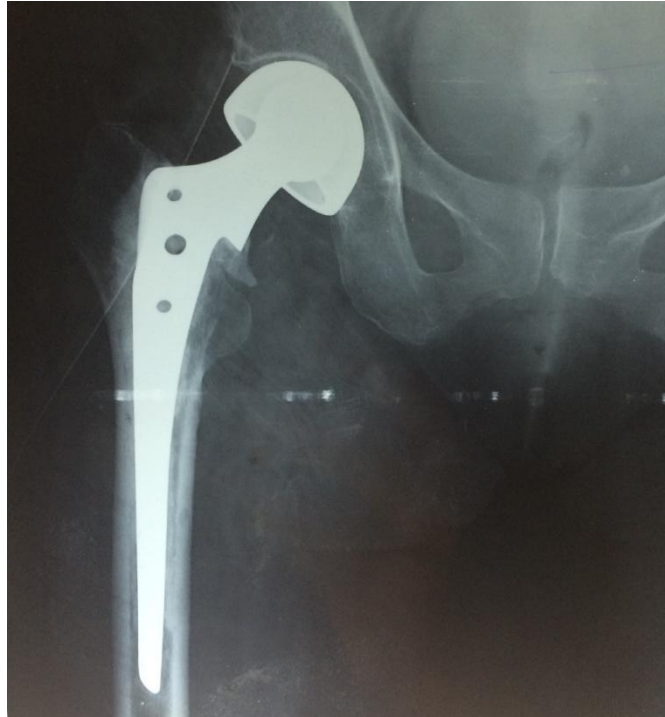

Post op X ray



Post op 1 year

Complications of Cemented Group:



Calcar Fracture