

Posterior Gastric Perforation in a Case of Pancreatitis with Pseudocyst

Prashant Tubachi¹, K. Rajgopal Shenoy², Raunak Maru³, Deepti Pai⁴
^{1, 2, 3, 4}(General Surgery, Kasturba Medical College/ Manipal, India)

Abstract: Acute pancreatitis has a number of complications. Stress related mucosal lesions in the gastrointestinal tract and pseudocysts are a few to name. Here by we present a case of a 37 year old male patient who was admitted to the urology ward of our institute with a diagnosis of left pyonephrosis. On evaluation a diagnosis of infected pancreatic pseudocyst was made. A surgical intervention was carried out where an external drainage of the pseudocyst was done instead of internal drainage as the patient developed intraop hypotension. As bile was seen in the drain postoperatively, an evaluation was done which led to a confirmed diagnosis of gastric perforation. There is no mention in the literature as to when a repair for gastric perforation in cases of pancreatic pseudocyst has to be carried out. In this case we carried out surgical intervention 2 weeks postoperatively, but were unsuccessful in treating the patient. Hence we conclude that gastric perforation can be diagnosed post operatively in a case of pseudocyst of pancreas, but if the patient is responding to a conservative line of treatment it is better to delay the perforation closure.

Keywords: acute pancreatitis, gastric perforation, pseudocyst of pancreas.

I. Introduction

Acute pancreatitis is a rapid-onset inflammatory process of the pancreas. It is commonly seen secondary to gallstone, alcoholism, hyperlipidemia or other causes. Acute fluid collection and pancreatic pseudocyst formation are the common complications. Acute pancreatitis may lead to severe systemic complications involving the lung, kidney and gastrointestinal tract. Studies have reported that more than half of patients with acute pancreatitis might present with upper gastrointestinal mucosal lesions [1, 2]. However, severe gastric necrosis with perforation is rarely encountered. Here, we report a case of acute pancreatitis with a pseudocyst formation complicated with gastric perforation.

II. Case Report

A 37 year old male patient was admitted in the urology ward of our institute with a history of pain in left side of the abdomen for one month with intermittent fever. Pain was insidious in onset and no specific aggravating and relieving factors were present. On clinical examination there was a mass felt in the left hypochondrium and the left lumbar region. The mass was ballotable. On percussion there was a dull note all over the mass. A diagnosis of left sided hydronephrosis or pyonephrosis was made. Ultrasonography showed left PUJ obstruction with pyonephrosis. The patient underwent ureteroscopy. No pus was seen and hence DJ stenting was done. As the symptoms did not subside, a CT scan abdomen plain with contrast was done. The CT scan not confirmatory and a differential diagnosis of left sided pyonephrosis and pseudocyst at the tail of pancreas was made (Fig 1). The patient was then referred to our surgical unit. The history revealed that the patient was a chronic alcoholic since 20 years and had previous attacks of pain abdomen, for which he was treated by a local doctor as acid peptic disease. His blood amylase and lipase were repeated during the episode of pain and results revealed significantly elevated levels. The patient was diagnosed as having severe acute on chronic pancreatitis with a pseudocyst at the tail of pancreas. A CT scan was repeated which showed a persistent pseudocyst. He was managed conservatively for two weeks. The patient had repeated episodes of fever with chills. Total counts were raised. It was then decided to perform exploratory laparotomy with a midline incision and internal drainage. Intraoperatively left kidney was normal. Lesser sac was frozen and could not be opened. Descending colon was mobilized and 10*10 cms thick walled cyst was present at the tail of pancreas (Fig 2). The cyst was opened and 1 litre of pus was drained. The pus had a green tinge to it. The patient developed hypotension after the drainage of pus and hence external tube drainage was done. The patient was fine for two days post operatively, but on the third day the drain was bilious (Fig 3). Drain fluid analysis showed bilirubin levels of 11 mg/dl and amylase levels of 1 lakh U/L. The patient was then administered with methylene blue orally which was seen in the drain.

Oral gastrografin study was then done, which showed a leak of the dye in the stomach (Fig 4). Upper GI scopy showed a perforation at the lesser curvature of the stomach but could not be clipped because of mucosal edema. He was managed conservatively and nasojejunal feeds were started. The drain was bilious even after two weeks and hence an exploratory laparotomy was done which revealed adhesions in the lesser sac. Adhesiolysis

by sharp dissection was done, (Fig 5) but the gastric perforation was not found intraoperatively and hence the drain was not taken out. Post operatively the patient was kept in the ICU as the patient had persistent hypotension and was started on inotropes. Parenteral nutrition was then administered on the 2nd post-op day. Unfortunately the patient developed pneumonia and succumbed to septicemia.

III. Discussion

A pancreatic pseudocyst is defined as a collection of pancreatic juice enclosed by a nonepithelialized wall that occurs as a result of acute pancreatitis, pancreatic trauma or chronic pancreatitis. Pseudocysts are said to occur in 16–50% of cases of acute pancreatitis and in 20–40% of cases of chronic pancreatitis. 70-80% of pancreatic pseudocysts are related to alcoholic pancreatitis [3]. According to previous reports, the gastrointestinal complications of pancreatitis include ileus, obstruction, regional bowel edema, ischemic necrosis and intramural hematoma [4]. Colonic perforation with peritonitis has also been reported [5]. As previously described mucosal lesions in the gastrointestinal track can also be seen. The majority of ulcers are located in the stomach and duodenum, and concomitant esophageal ulcers are not uncommon [6].

In the present case a surgical intervention was carried out as the patient was deteriorating secondary to infected pseudocyst of the pancreas. Intra operatively internal drainage was not possible due to his deteriorating blood pressure. Post operatively the drain showed bile following which a diagnosis of gastric perforation was confirmed by gastrograffin study and upper GI endoscopy. There are no definitive guidelines in the literature as to when the intervention for gastric perforation secondary to acute pancreatitis has to be carried out. Chometowski et al reported a patient with both gastric and colonic perforation; intravascular coagulation was proposed as the possible mechanism of perforation [7]. Kirschniak et al reported a patient with necrotizing pancreatitis who received laparoscopic necrosectomy and highlighted the development of delayed gastric perforation of the stomach [8]. Both the studies make no mention about the time at which a surgical intervention is to be carried out. In the present case though a bilious drain was still seen after 2 weeks of conservative treatment it showed a definite downward trend. As the patient's general physical condition was deteriorating laparotomy for perforation closure was carried out but the treatment was unsuccessful.

IV. Figures

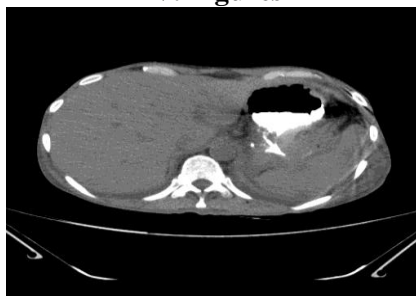


Figure 1: CT showing pseudocyst at the tail of pancreas

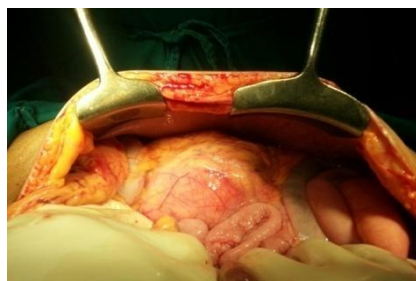


Figure 2: Intraoperative picture of the cyst



Figure 3: Bilious drain

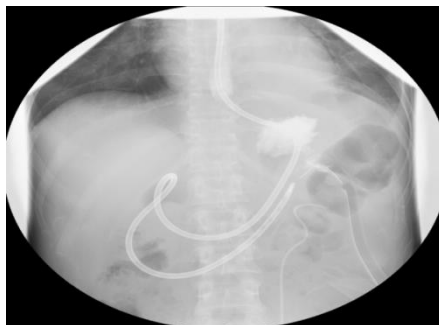

Figure 4: Gastrograffin study showing leak from the stomach

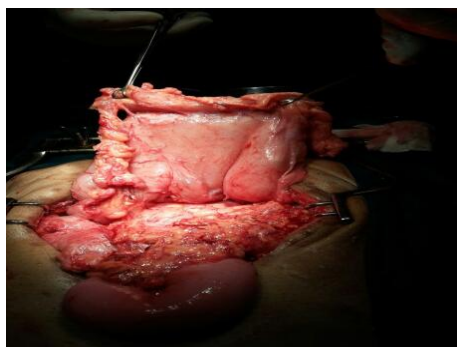


Figure 5: Dissection of the posterior gastric wall

V. Conclusion

Gastric perforation in a case of pancreatic pseudocyst is a rare complication which can be diagnosed intraoperatively or post operatively as seen in the present case report. Finding the exact location of gastric perforation intraoperatively is difficult due to dense adhesions secondary to pancreatitis. It is better to manage such a case conservatively if the patient is responding to treatment.

References

- [1]. Lin CK, Wang ZS, Lai KH, Lo GH, Hsu PI. Gastrointestinal mucosal lesions in patients with acute pancreatitis. *J Chin Med Assoc* 2002;65:275–8.
- [2]. Chen TA, Lo GH, Lin CK, Lai KH, Wang HY, Yu HC, Hsu PI, et al. Acute pancreatitis-associated acute gastrointestinal mucosal lesion: incidence, characteristics, and clinical significance. *J Clin Gastroenterol* 2007;41:630–4.
- [3]. Groeneveld JH, Tjong a Lieng JG, de Meijer PH. Resolution of a complex mediastinal pseudocyst in a patient with alcohol-related chronic pancreatitis following abstinence from alcohol. *Eur J Gastroenterol Hepatol.* 2006;18:1113.
- [4]. Chen CY, Lu CL, Chang FY, Lee SD. Duodenal lesions following severe acute pancreatitis: review of 10 years' clinical experience. *Hepatogastroenterology* 2001;48:869–71.
- [5]. CallejaSubiran MC, UrienBlazquez LM. Colonic perforation, a rare complication of acute necrotizing pancreatitis. *An Med Interna* 2006;23:235–7.
- [6]. Chebli JM, de Souza AF, Gaburri PD, Bastos KV, Ribeiro TC, Filho RJ, Chebli LA, et al. Prevalence and pathogenesis of duodenal ulcer in chronic alcoholic pancreatitis. *J Clin Gastroenterol* 2002;35:71–4
- [7]. Chometowski S, Bourde J, Assadourian R, Pietri H, Lamy J. Double gastric perforation and colonic perforation during necrotizing pancreatitis submitted to arteriography. *Ann Chir* 1976;30:621–4
- [8]. Kubo K, Nakamura H, Hirohata Y, Abe S, Onari N, Otsuki M. Ruptured aneurysm and gastric perforation associated with acute pancreatitis: a rare cause of hematemesis. *Gastrointest Endosc* 2001;53:658–60.