

Human Tail – The Lumbo Sacral Stigma: A Case Report

Dr. Chandrakanta Nayak¹, Dr. Barada Prasanna Samal²,

Senior Resident, Department Of Orthopaedics
All India Institute of Medical sciences, Bhubaneswar

Abstract: A tail in a six year old girl is reported and the findings from previously reported cases of true and pseudo tails are discussed. The girl presented with a dorsal midline appendage and associated pain over the tip of the appendage. Radiologic evaluation showed five well developed coccygeal vertebrae. She was thoroughly investigated to exclude any underlying spinal pathology. As the cosmesis was not an indications for that patient and symptoms were not so severe patient was treated conservatively and followed up for three years .

I. Introduction

Human tail has always generated curiosity. Caudal appendages are unusual malformations of neuro spinal axis and divided into true and pseudo tails. true tail contain nonosseous and non cartilaginous soft tissues containing adipose tissue, connective tissues. pseudo tails contain fibroblastic tissues including elongated coccyx, prolonged sacrum, teratoma etc. there are very few documented cases of human tail containing cartilage or up to five vertebrae. We present a case of pseudo human tail containing five well developed coccygeal vertebrae and its three year follow up.

II. Case Report

A six year old female child presented with a tail like appendage in midline coccygeal region (**fig 1**) since birth and pain on that area since last 3 months. The pain was not radiating in nature and was severe on sitting on hard surfaces. The child was not able sit cross legged as the appendage was hitting the surface. The child was accustomed to sit with one leg on ground.

She was the first child of the healthy mother and was born after term pregnancy and with an uneventful normal vaginal delivery. Mother had no history of previous miscarriage, or any illness, exposure to radiation or drug during pregnancy. she did not have any family history of congenital anomaly either.

On examination the girl was healthy with history of on time developmental milestones. Neurological examinations including muscle strength, tone, sensation and reflexes were normal. Bladder and bowel were not involved. On per rectal examinations there was normal rectal tone with posterior wall feeling bony and painless and anal wink reflexes present bilaterally. On local examinations there was a appendage of 3 cm long and was attached to back of tip of coccyx appearing like a human tail. It was soft, non tender and was covered with normal skin. There was a bursa over the tip of coccyx causing pain.

A lateral radiograph of lower vertebral column showed the normal number of lumbar and sacral vertebra but there was very prominent coccyx measuring 7 cm length and consisting five well developed vertebra. Antero posterior view of x ray showed normal lumbo sacral configuration. CT scan (**fig 2**) and MRI (**fig 3,4**) was done to excludes any other vertebral, cord or soft tissue anomaly.

Partial excision of the coccyx was considered. But on bed rest in hospital after admission the bursa over the coccyx healed and the pain subsided. so the operation was not performed as parents believed the pain decreasing. The patient was discharged and put for follow up. On three year follow up child is asymptomatic throughout and able to sit cross legged as the gluteal mass has been increased by age and the size of tail has been relatively inconspicuous.

III. Discussion

Reiter⁽¹⁾ in 1944 found that the greatest number of somites are found in 5th week of pregnancy as he noted a total of 42 : five occipital, seven cervical, twelve thoracic, five lumbar, five sacral and eight coccygeal. Reiter noted that all eight coccygeal segments developed into blastemal vertebrae. Around sixth week centres of chondrification appears in blastemal vertebrae and the vertebral column becomes the axial supporting structure⁽²⁾. Chondrification centres donot appear in lowest cocygeal vertebrae. As cartilage develops in upper coccygeal segments, lower regions disappear. By eighth week, sixth, seventh and eighth coccygeal segments have disappeared and fourth and fifth are in the process of reduction⁽¹⁾. Normally the typical vertebrae is ossified from three primary centres one for body and two for arches where as each segment of coccyx is ossified from one primary centre. The coccyx is a small triangular bone formed by fusion of four rudimentary coccygeal segments⁽³⁾. In our case probably the somite formation was normal and all eight

segments developed blastemal vertebrae. The sixth seventh and eighth disappeared as normal. Each of the remaining five vertebrae developed three primary centres of chondrification as in typical vertebrae⁽⁴⁾.

According to Harrison⁽⁵⁾, anything appended to the sacral / coccygeal region is a tail. rudimentary caudal appendages in man has been classified in to five types by bartel. first, second and third are variants of soft tail that arises from embryonic tail. fourth and fifth are bony tail. fourth is a sacro coccygeal hypertrophy as in our case. Fifth is a true animal tail containing extra vertebrae. Dao and Netsky⁽⁶⁾ again classified human tail into true and pseudo tail. A true tail is defined as non osseocartilagenous midline protrusion containing adipose tissue, connective tissue, blood vessels and nerves but no spinal cord material covered by normal skin with usual hair follicle and sweat glands. movement of the tail has been described as spontaneous reflex motion in some case^(5,7). Pseudotails are osteocartilagenous structures including elongated coccyx, sacral prolongation, teratoma etc^(8,9).

But all cases of congenital tail need to be fully investigated because of high suspicion of other intraspinal pathology^(10,11). Frank et al⁽⁶⁾ reviewed 59 cases of human tail and noted incidence of spinal dysraphism in 49% of cases and tethered cord in 20% of patients. In tethered cord rarely it is seen that the tail leading to tether the cord through a fibrous band⁽¹²⁾. A wide array of spinal cord and spine anomalies like spina bifida, lipomeningocele, myelomeningocele, intraspinal lipoma cord tethering are seen to be associated with human tail. Cleft palate was reported once⁽¹³⁾. Chunquan Cai et al⁽¹⁴⁾ have reported a case of human tail coexisting with type I split cord malformations. Donovan⁽¹⁵⁾ et al have reported child with a tail and intraspinal lipoma that were not contiguous with each other

CT scan has high sensitivity in diagnosing spinal dysraphism and intraspinal lesions. MRI is used widely in evaluating all spinal disorders like syringomyelia, lipomeningocele, tethered cord and also relationship of tail with spinal cord^(16,17). All the human tail should be investigated by CT scan and MRI.

Treatment of caudal appendages has also indications. It is prudent to check intraspinal pathology before deciding for treatment. For Soft/true tail en bloc excision of the tail with resection of lumbosacral fibrous band is done. After the operation, long term follow up of the patients is necessary for development of tethered cord⁽¹⁴⁾. Now a days Microsurgical treatment is done to prevent tethered cord syndrome, even with no pre operative neurological involvements^(18,19). for bony/ pseudo tails without any associated anomaly a simple partial coccyx excision can be performed for cosmetic purposes without any further exploration.

In some studies⁽²⁰⁾ the proposed operation has been postponed and patients were followed up with no future complications. In our case after 3 year follow up the patient is asymptomatic and not seems to need any intervention in future.

IV. Conclusion

There are very few case reports on human tail in literature. This is considered to be a marker of underlying spinal dysraphism. MRI is the diagnosis of choice to exclude other associations. Treatment is usually unnecessary but Partial coccygeal excision or en bloc tail excision can be done for coccygodynia or cosmetic purpose with long term follow up for tethered cord syndrome. For not so cosmetically demanding cases only a good follow up is necessary.

Competing interests: none declared

Conflict of interests: none declared

Funding : none declared

Bibliography

- [1]. Reiter A. Die Fruhentwicklung der menschlichen Wirbels#{}ule. Z Anat Entwick 1944;113:203-27.
- [2]. Williams PL, Wendell-Smith CP, Treadgold S. Basic human embryo/ogy. London: Pitman Medical Publishing Company, 1966:53,82-3.
- [3]. B D .Chaurasia 5th edition page 203
- [4]. Parsons RW. Human tails. P/ast Reconstr Surg 1960;25:618-21.
- [5]. Harrison RG: On the occurrence of tails in man, with a description of the case reported by Dr. Watson. Bull Johns Hopkins Hosp 12: 96-101, 1901
- [6]. Dao AH, Netsky MG: Human tails and pseudotails. Hum Pathol 15: 449-453, 1984
- [7]. Dubrow TJ, Wackym PA, Lesavoy MA: Detailing the human tail. Ann Plast Surg 20: 340-344, 1988
- [8]. Bar-Maor JA, Kesner KM, Kaftori JK: Human tails. J Bone Joint Surg [Br] 62: 508-510, 1980
- [9]. Odeku EL, Adeloje A: A case of human pseudo-tail. West Afr Med J 19: 115-116, 1970
- [10]. Biswanath M, Ram MS, Madhumita M, Kartik CM, Pankaj H, Abhijit B. Spectrum of human tails: A report of six cases. J Indian Assoc Pediatr Surg. 2012;17:23-5.
- [11]. Singh DK, Kumar B, Sinha VD, Bagaria HR. The human tail: rare lesion with occult spinal dysraphism--a case report. J Pediatr Surg. 2008;43:41-3.
- [12]. Lu FL, Wang PJ, Teng RJ, Yau KI. The human tail. Pediatr Neurol. 1998;19:230-3.
- [13]. Lundberg GD, Parsons RW. A case of a human tail. Am J Dis Child 1962; 104: 72-3
- [14]. Cai C, Shi O, Shen C. Surgical treatment of a patient with human tail and multiple abnormalities of the spinal cord and column. Advances in orthopedics 2011; 2011: 153797.

- [15]. Donovan DJ, Pedersen RC . Human tail with noncontiguous intraspinal lipoma and spinal cord tethering: case report and embryologic discussion. *Pediatr Neurosurg* 2005 ; **41** : 35 – 40 .
- [16]. Brophy JD, Sutton LN, Zimmerman RA, Bury E, Schut L: Magnetic resonance imaging of lipomyelo meningocele and tethered cord. *Neurosurgery* 25: 336-340, 1989
- [17]. Hall WA, Albright AL, Brunberg JA: Diagnosis of tethered cords by magnetic resonance imaging. *Surg Neurol* 30: 60-64, 1988
- [18]. Hoffman HJ, Taecholarn C, Hendrick EB, Humphreys RP: Management of lipomyelomeningo celes. Experience at the Hospital for Sick Children
- [19]. Kanev PM, Lemire RJ, Loeser JD, Berger MS: Management and long-term follow-up review of children with lipomyelomeningocele, 1952- 1987. *J Neurosurg* 73: 48-52, 1990
- [20]. J.Abar morr , k .m.kesner :Human tail: *JBJS* vol 62b no4 nov 1980

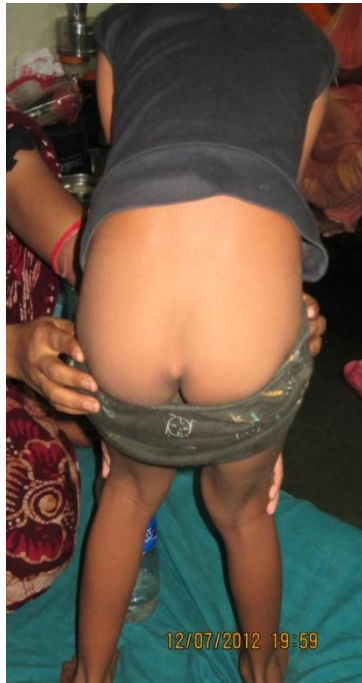

Fig 1 showing the human tail

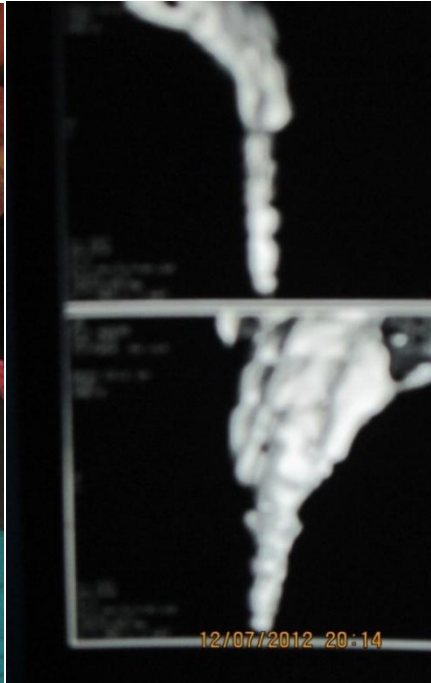


Fig2 :

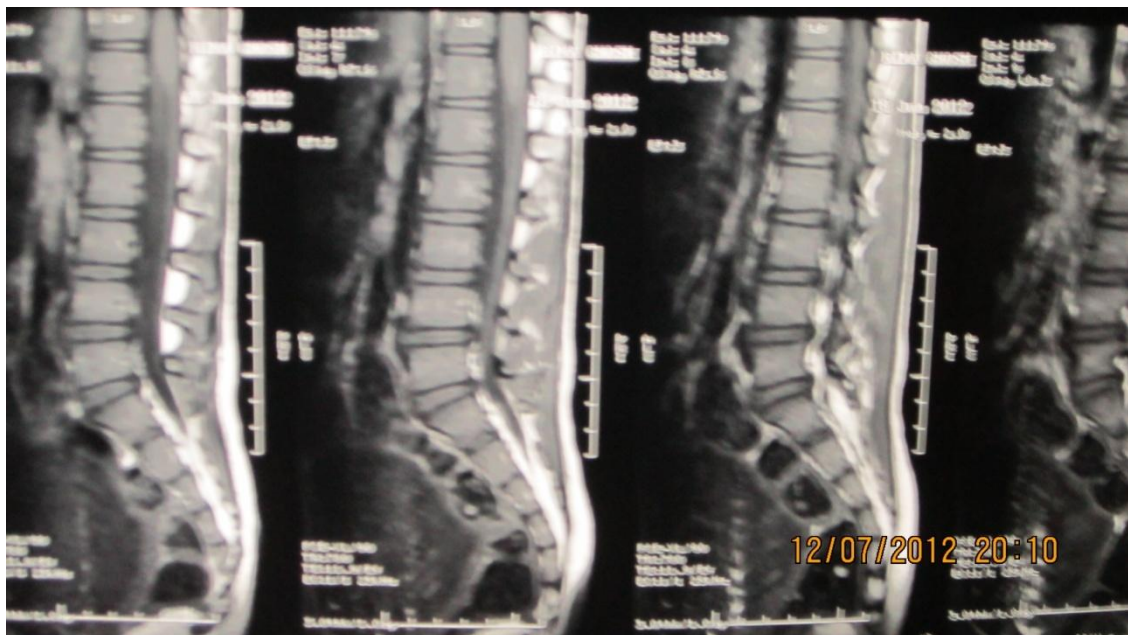


Fig 3