

## Variations on Renal Vessels – a cadaveric study

Dr. Padmaja Vasi M.B.B.S., M.D.

(Assistant Professor in Anatomy, Gandhi Medical College, Secunderabad – 500 025, Andhra Pradesh, India)

---

**Abstract :** The scientific works to explore normal structure of the human kidney and its different variations are neither new nor recent. The very large number of studies already carried out speaks volumes on the great magnitude of importance of the organ that is the kidney. The kidney as is well known, is a very vital organ on account of different functions that are carried out by it namely removing the excess water products, maintaining the pH of blood, formation of the urine, regulation of blood pressure. The vascular system of the kidney is complex & highly specialised and is remarkably adapted to the function which it has to perform. The origin and course of human renal blood vessels and their variations are of great interest to surgeons and physicians. Although the various individual scientific works on renal vasculatures are concluded, yet the information obtained thereby can never be declared as complete. The studies related to such vital organ are more warranted and useful owing to their clinical importance. The study was conducted to add meaningful information to the existing data pertaining to the blood supply of kidney.

**Keywords -** renal vessels, accessory renal arteries, accessory renal veins and multiple renal veins

---

### I. Introduction

Variation in numbers and arrangement of renal vessels are very common. These variations are of importance to clinicians who deal with surgical procedures mainly in kidney transplantations and surgeries. The study is mainly focused on morphology of renal blood vessels and their variations. We believe that the outcome of this work may add meaningful information to the existing data pertaining to renal vasculature and this may be of considerable value in the other different further studies in various medical and surgical specialities related to the kidney on the clinical studies.

The renal artery branch laterally from the aorta just below the origin of the superior mesenteric artery. The right renal artery (RRA) is longer and often higher, passing posterior to the inferior vena cava (IVC) and right renal vein. The left renal artery is a little lower and passes behind the left renal vein. A single renal artery to each kidney is present in 70% of individuals. Accessory renal arteries are common in 30% of individuals, and usually arise from the aorta above or below (most commonly below) the main renal artery and follow it to the renal hilum [1]. Accessory renal arteries may also enter the kidneys directly, usually into the superior or inferior poles. Accessory renal artery to the inferior pole (polar renal artery) may cross anterior to the ureter and obstruct it, causing hydronephrosis. If the artery enters to the inferior pole of the right kidney, it usually crosses anterior to the IVC and ureter. They are regarded as persistent embryonic lateral splanchnic arteries. It is important to be aware that accessory renal arteries are end arteries; consequently if an accessory renal artery is damaged or ligated, the part of the kidney supplied by it is likely to become ischemic. Accessory renal arteries are about twice as common as accessory veins [2].

The large renal veins lie anterior to the renal arteries and open into the inferior vena cava almost at right angles. The left is three times of the right in length (7.5 cm and 2.5 cm). The left renal vein runs from its origin in the renal hilum, posterior to the splenic vein and the body of pancreas, and then across the anterior aspect of aorta. The left testicular or ovarian vein enters the left renal vein from below, and the suprarenal vein usually receiving one of the left inferior phrenic veins, enters it above. The right renal vein is behind the descending part of duodenum. The right testicular or ovarian vein and the right suprarenal vein enter the inferior vena cava directly. The left renal vein may be double, one vein passing posterior, the other anterior to the aorta before joining the inferior vena cava.[3]

### II. Method

The present study was done on hundred embalmed cadavers over a period of ten years during routine dissection practices for under graduates in the dissection hall of Gandhi medical college, Secunderabad.

**Procedure:** Dissection was carried out using dissection instruments as per standard procedure as given below -

- A vertical incision was given from xiphoid process to pubic symphysis and one horizontal incision was given from xiphoid process laterally to the body.
- Another horizontal incision was given from the pubic symphysis to iliac crest.

- Skin flaps were reflected laterally, anterior abdominal wall muscles, rectus abdominis muscles and their aponeurosis were identified and reflected.
- Abdominal cavity was opened by reflecting the peritoneum.
- Greater omentum was identified and is reflected.
- Stomach and transverse colon were identified and reflected.
- Duodenum is reflected. Small intestines were turned to left and are reflected. Jejunum and ileum were identified and reflected.
- Pancreas, spleen and liver were reflected. Fat and fascia from anterior surface of left kidney and supra renal gland were traced.
- The left suprarenal vein and left testicular vein or ovarian vein were traced to left renal vein.
- Renal vein was displaced to expose the left renal artery
- Left kidney was turned medially to expose its posterior surface and that of its vessels, ureter, muscles and nerves which were posterior to them.
- The similar procedure was carried out on right side to expose the right kidney.

**Observations:** Observations were recorded in the following order –

- Anomalies of renal arteries on right side & left side.
  - Anomalies of renal veins on left side & right side.
  - Specimens were named as C1 to C100. Out of 100 specimens, total seven anomalies were observed.
1. In specimen no. C 9 - accessory renal artery was found close to the lower pole of the left kidney. It was found anterior to the ureter arising from the abdominal aorta at the level of L3. (Fig.1)
  2. In specimen no. C 12 - accessory renal artery and accessory renal vein were present on right side. An accessory renal vein was emerging at the hilum and is opening into inferior vena cava. An accessory renal artery on the right kidney was also seen and was arising from the abdominal aorta little above the renal artery at the level of L1 and was supplying the upper pole. (Fig.2 and 3)
  3. In specimen no. C 35 – in right kidney, no anomalies were observed, whereas, on left side in addition to main artery two accessory renal arteries were arising from the abdominal aorta. One was above the main renal artery and was entering into the hilum, the other accessory artery was observed below the main artery and this was also entering into the hilum of the kidney. (Fig. 4)
  4. In specimen no. C 42 - the right kidney was normal. In the Left kidney the hilar structures were abnormal the renal artery was anterior to renal vein and posterior to renal pelvis. An accessory renal artery was seen arising from the aorta at the level of L4 & was passing anterior to the ureter. (Fig.5)
  5. In specimen no. C 56 - the left kidney was normal. In the right kidney an additional renal artery was observed. It was observed that this accessory renal artery was also supplying the supra renal gland and also supplying the right side of the diaphragm at the upper pole at the level of L1. (Fig.6)
  6. In specimen no. C 80 - left kidney was normal. On the left kidney an accessory renal artery was arising from the abdominal aorta it was just below the main renal artery entering into the hilum. (Fig.7)
  7. In specimen no. C 85 - multiple renal veins were observed on both sides of the kidney and all were opening into inferior vena cava. (Fig.8)

### III. Discussion

In this study of renal vasculature we found accessory renal arteries in 6 cases and in 2 cases we found accessory renal veins. This was a quite low frequency when compared to De. Virgilic et al 1995 (75%) [4], Graves F.T (1956) (50%) [5], 42 % in Brodie P. et al in 2004 [6]. 36 % by Chugh K.S. et al in 1993 [7], Singh et al 1998 observed 30 to 35 % of accessory renal arteries [8]. Park B. et al in 1998 found 30% of aberrant renal arteries [9], whereas Dhar P. et al 2005 observed 20% [10], in 2003 Satyapal K.S. et al found 18% on right side, 27.6% on left side [11], 2006 Karmacharya J et al found a very low incidence of 6.6 % [12] when compared to the other authors & was same frequency when compared with our study. There were also single cases of accessory renal arteries reported by Morishik et al in 1996 [13], Mohanty et al in 2002, [14] in 2003 by Bayramogulu [15], Vaniya VH in 2004 [16], Tae won kwan et al in 2004 [17] and Loukas et al in 2005 [18].

As far as the incidence of accessory arteries passing to the poles of the kidney are concerned, Brodie p et al found that the accessory renal arteries are passing to inferior poles twice that passing to upper pole. In the present study it was observed that three cases of accessory renal arteries were entering lower pole of kidney and in two cases renal arteries were entering into upper pole of kidney. Regarding the origin of the accessory renal arteries and left predominance most of the authors have observed that these arteries are originating from the aorta. The present study also observed left predominance in 8% of cases & in 4% of cases on right side. It is also observed an aberrant renal artery supplying supra renal gland of the right kidney and also right dome of diaphragm in addition to right upper pole of the kidney. This was rare anomaly which was not found in any

literature. Regarding renal vein anomalies are concerned the right renal vein is far more often double than the left one. In present study it was found that double renal veins in one cadaver and multiple renal veins in another cadaver, out of 100 which was high in frequency when compared to Satyapal K.S. et al (0. 4%) and is of less incidence when compared to Dhar P et al 2004 (3%) on left side & 12% on right side & Brodiei p et al also mentioned 7 % of additional renal veins a single case was reported by Kasely G et al 1999 [19].

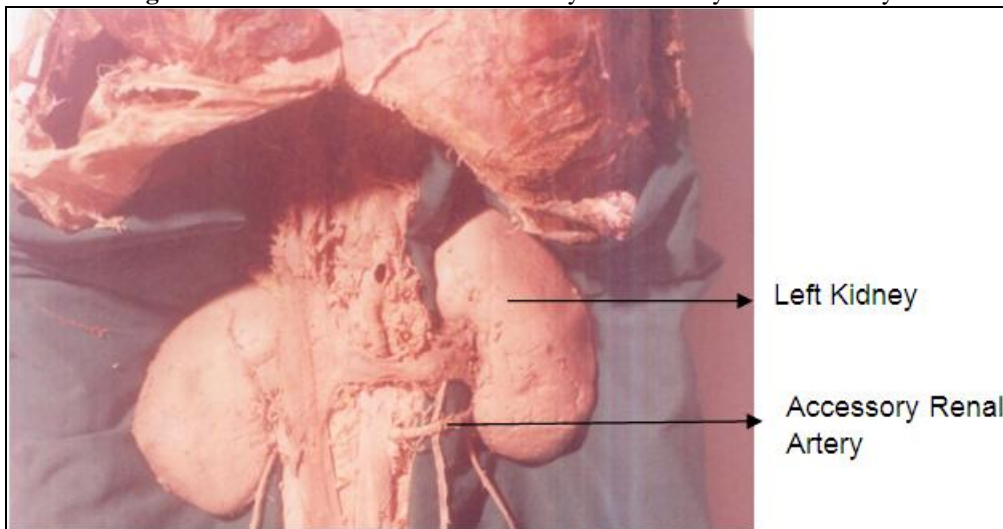
According to Pick and Anson [20] most of multiple renal veins were present on right side in their studies (27.8 %), Nayak B.S. [21] also observed variations of right renal veins and there are common than left renal veins. The present case study results were compared with earlier authors and tabulated in Table 1 and 2 and same is depicted in Graph 1 and 2.

#### IV. Conclusion

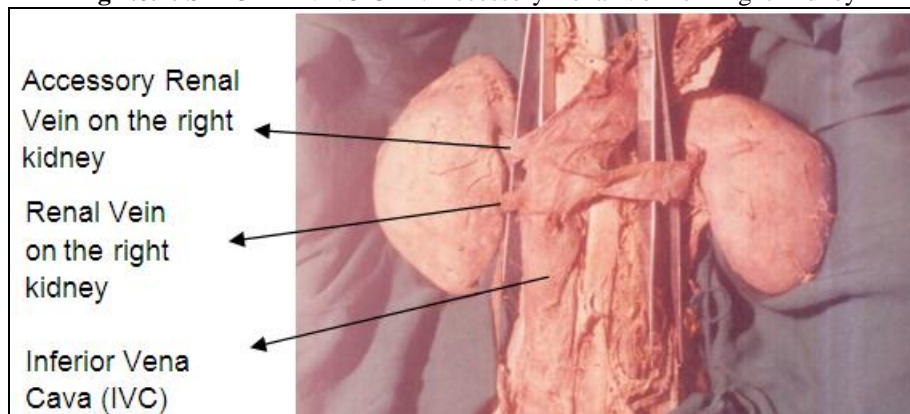
After an attempt to study renal vascular anomalies in the present case study it was observed that the findings are in general agreement with the findings of the earlier studies. The author found accessory renal arteries at a low incidence in the present study when compared to earlier authors. The author feels it is due to limited cross sectional study on cadavers. However it was found that the incidence of accessory renal arteries is more common than that of accessory renal veins.

#### Figures And Tables

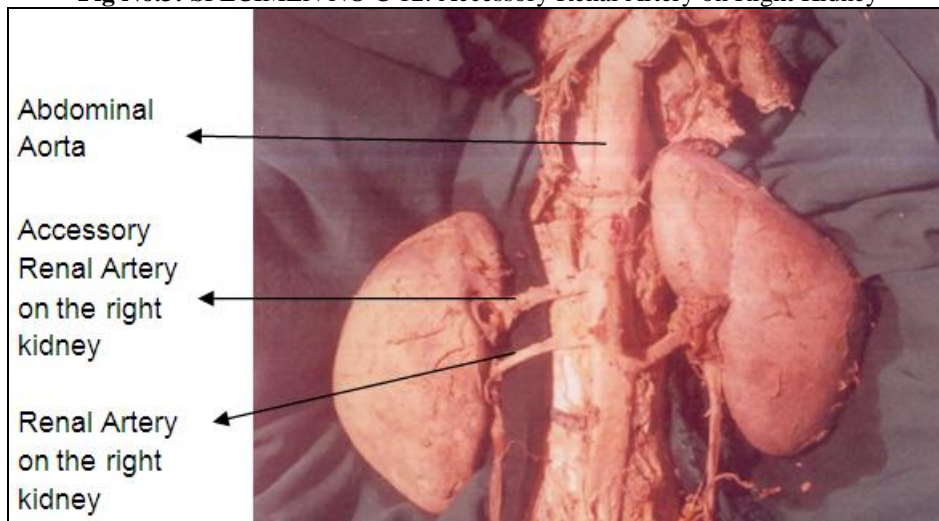
**Fig No.1:** SPECIMEN NO C 9: Accessory Renal Artery on Left Kidney



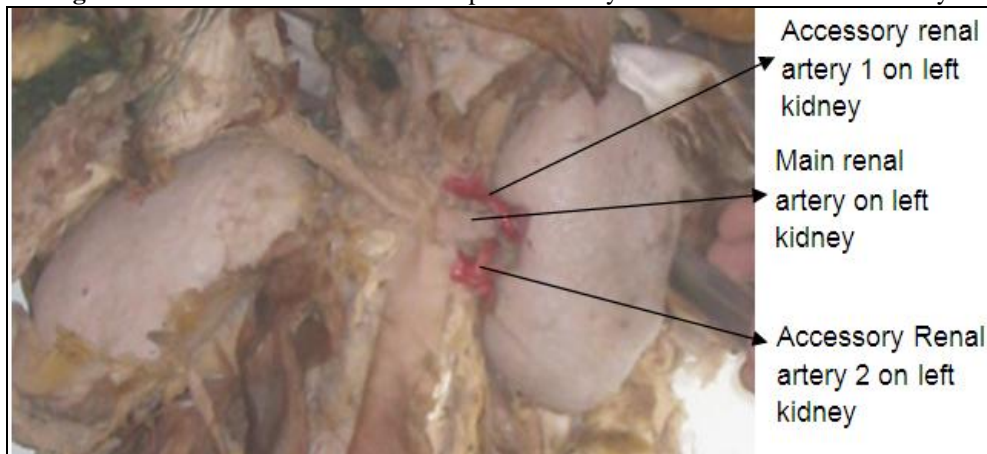
**Fig No.2:** SPECIMEN NO C 12: Accessory Renal Vein on Right Kidney



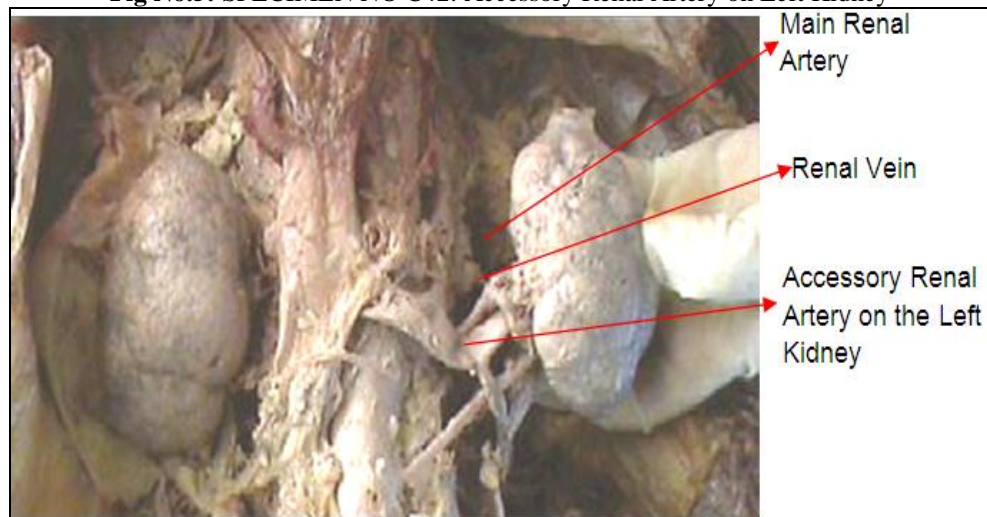
**Fig No.3:** SPECIMEN NO C 12: Accessory Renal Artery on Right Kidney



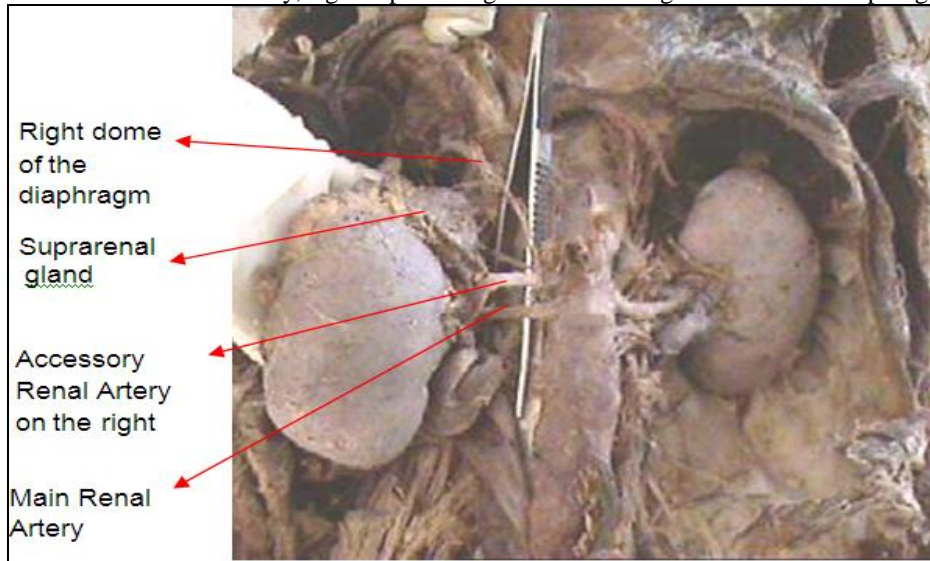
**Fig No.4:** SPECIMEN NO C 35: Multiple Accessory Renal Arteries on Left Kidney



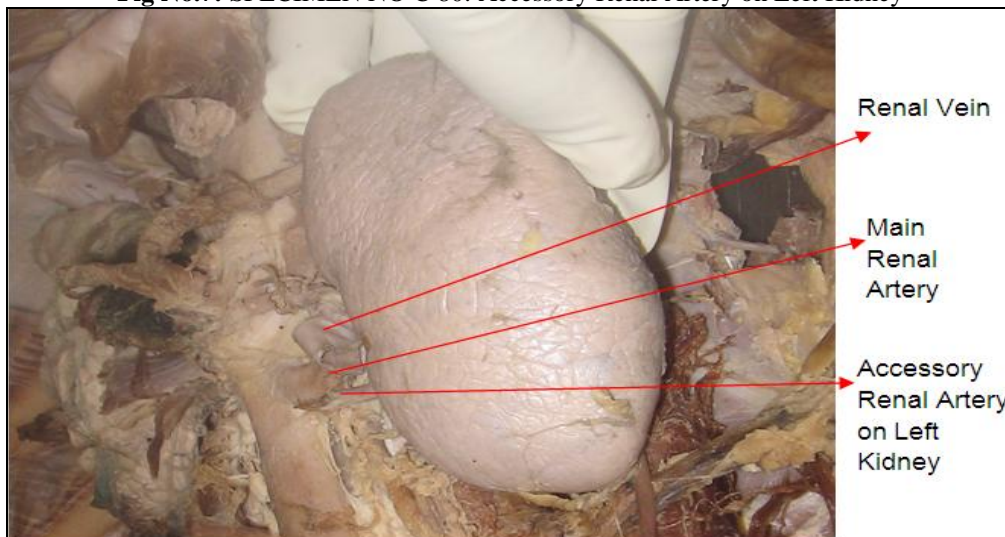
**Fig No.5:** SPECIMEN NO C42: Accessory Renal Artery on Left Kidney



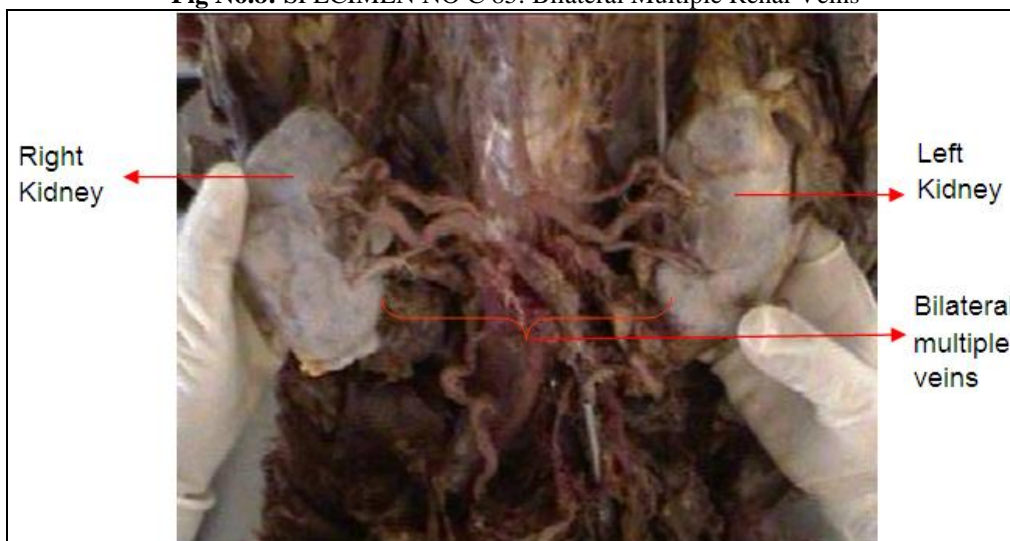**Fig No.6:** SPECIMEN NO C 56: Accessory Renal Artery on the right kidney supplying upper pole of the kidney, right suprarenal gland and also right dome of the diaphragm.



**Fig No.7:** SPECIMEN NO C 80: Accessory Renal Artery on Left Kidney



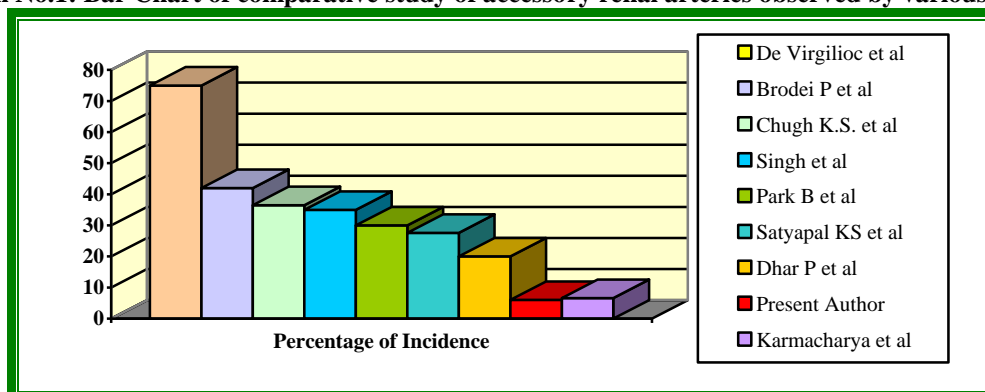
**Fig No.8:** SPECIMEN NO C 85: Bilateral Multiple Renal Veins



**Table No.1: Comparative study of accessory renal arteries observed by various authors**

S.No.	Author	Year	No. of cases	Percentage of incidence
1.	Chugh K.S. et al	1993	170 Kidneys (85 cases)	36.5%
2.	De Virgilioc et al	1995	12 Cases	75%
3.	Singh G. et al	1998	100 cases	35%
4.	Brodei P. et al	2004	54 cases	42%
5.	Dhar P. et al	2005	40 cases	20%
6.	<b>Present author</b>	<b>2004-2014</b>	<b>100 cases</b>	<b>6%</b>

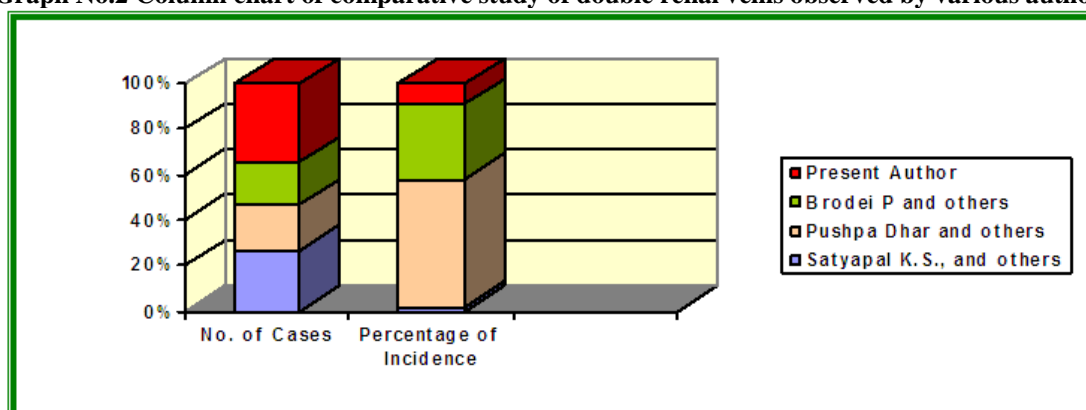
**Graph No.1: Bar Chart of comparative study of accessory renal arteries observed by various authors**



**Table No.2 Comparative study of double renal veins observed by various authors**

S.No.	Author	Year	No. of cases	Percentage of incidence
1.	Satyapal K. S., et al	1998	153 Kidneys (76 cases)	0.4% on left side
2.	Pushpa Dhar, et al	2004	59 Cases	3% on left side 12% on right side
3.	Brodei P, et al	2004	54 cases	7%
4.	<b>Present author</b>	<b>2004-2014</b>	<b>100 cases</b>	<b>1%</b>

**Graph No.2 Column chart of comparative study of double renal veins observed by various authors**



### References

- [1]. Standring S, ed. Gray's Anatomy. The Anatomical Basis of Clinical Practice. 40th Ed., Edinburg, Churchill & Livingstone. 2008; 1231.
- [2]. Moore KL, Persaud TVN. The Developing Human. Clinically Oriented Embryology. 8th Ed., New Delhi, Elsevier. 2008; 249–250.
- [3]. Standring S, Jeremiah HC, Glass J, Collins P, Wigley C, eds. Gray's Anatomy. The Anatomical Basis of Clinical Practice. 39th Ed., London, New York, Oxford, Philadelphia, St. Louis, Sydney, Toronto, Elsevier Churchill Livingstone. 2005; 1276–1277.
- [4]. De. Virgilioc, Gloviczkip, Cherry. K.J., Stanson. A.W., Bower. T.C., Hallett. J.W., Jr., Pairolero. P.C. (1995) Renal artery anomalies in patients with horseshoe or ectopic kidneys: the challenge of aortic reconstruction. Cardiovasc Surg. 1995 Aug;3(4):413-20. PMID: 7582997
- [5]. Graves F.T. (1956) The Aberrant Renal Artery ; J Anat. 90:553
- [6]. Brodei P., Sapte E., Iliescu D. Double renal arteries originating from the aorta. Surg Radiol Anat. 2004; 26(6):474-9 (ISSN: 0930-1038)

- [7]. Chugh. K.S., Malik. N., Gosh A.K., Sakhya. V., Minz M. (1993) Pattern of renal arteries in normal subjects : a study of 170 renal donor angiograms. *Indian Journal of Nephrology*. 1993 Jan-Mar; 3(1): 9-11 Record Identifier: NI002338
- [8]. Singh. G., Ng. Y. K., Bay. B.H., (1998) Bilateral accessory renal arteries associated with some anomalies of the ovarian arteries: a case study. *Clin Anat*. 1998;11(6):417-20. PMID: 9800922
- [9]. Park BS, Jeong TK, Ma SK, Kim SW, Kim NH, Choi KC, Jeong YY. (2003) Hydronephrosis by an aberrant renal artery: a case report. *Korean J Intern Med*. 2003 Mar;18(1):57-60. PMID: 12760271
- [10]. Dhar P, Lal K.(2005) Main and accessory renal arteries--a morphological study; *Ital J Anat Embryol*. 2005 Apr-Jun;110(2):101-10; PMID: 16277160.
- [11]. Satyapal K.S., Kalideen J.M., Singu B., Hafejee A.A., Robbs J.V. (2003) Why we use the donor left kidney in live related transplantation. *S Afr J Surg*. 2003 Feb;41(1):24-6; PMID: 12756870
- [12]. Karmacharya J., Parmer S.S., Antezana J.N., Fairman R.M., Woo E.Y., Velazquez O.C., Golden M.A., Carpenter J.P. (2006) Outcomes of accessory renal artery occlusion during endovascular aneurysm repair. *J Vasc Surg*. 2006 Jan;43(1):8-13; PMID: 16414380.
- [13]. Morishimak, Miyaki. T., Ito. H. (1996) A rare case of a kidney with an widely opened hilus and supernumerary renal vessels. *Kaibogaku Zasshi*. 1996 Jun;71(3):215-8. PMID: 8831188
- [14]. Mohanty. C., Ray. B., Samaratung. U., Singh. G. (2002) Horseshoe Kidney with Extrarenal Calyces – A Case Report; *J Anat. Soc. India* 51(1) 57-58 (2002)
- [15]. Bayramoglu. A., Demerymek. D., Erbil. K.M. Bilateral additional renal arteries and an additional right renal vein associated with unrotated kidneys. *Saudi Med J*. 2003 May;24(5):535-7 PMID: 12847633
- [16]. Vaniya. V.H. (2004) Horseshoe Kidney With Multiple Renal Arteries And Extrarenal Calyces - A Case Report ; *J.Anat. Soc. India* 53 (2) 52-54 (2004)
- [17]. Tae Won Kwan, Kyu-Bo Sung, Geun-Eun Kim (2004) Experience of an Abdominal Aortic Aneurysm in a Patient having crossed Ectopia with Fusion Anomaly of the Kidney; *J Korean Med Sci* 2004; 19: 309-10
- [18]. Loukas M, Aparicio S, Beck A, Calderon R, Kennedy M. (2005) Rare case of right accessory renal artery originating as a common trunk with the inferior mesenteric artery: a case report. *Clin Anat*. 2005 Oct;18(7):530-5. PMID: 16134127
- [19]. Kalsey G., Patnaik V.V.G., Singla R. (1999) Retro-Aortic Left Renal Vein; *J Anat. Soc. India* 48(2) 105-107 – 1999
- [20]. Pick, JW, Anson, BJ (1940) The renal vascular pedicle: an anatomical study of 430 body-halves. *J Urol* 44: pp. 411-434
- [21]. Nayak, B. S. Multiple variations of the right renal vessels. *Singapore Medicine Journal*, v. 49, n. 6, p. 153-155, 2008a.