

A Clinical Study on Visual Outcome and Complications of Penetrating Keratoplasty

Dr. Manu Thomas¹, Dr. Hrishikesh Amin², Dr. Vijay Pai³,
Dr. Jayaram Shetty⁴

Department of Ophthalmology, K.S. Hegde Medical Academy, Nitte University, India

Abstract

Aim: To evaluate visual outcome and complications of penetrating keratoplasty.

Materials and Methods: 30 cases underwent penetrating keratoplasty for optical and therapeutic purpose. Clinical examination and investigations were conducted. Indications, demographic profile, visual outcome and complications were assessed. Follow up period was 6 months.

Results: 93.33% operated for optical and 6.67% for therapeutic purpose. Most common indication was corneal opacity (36.7%) followed by bullous keratopathy (33.3%). Others were re-graft (13.3%), non-healing infectious keratitis (6.7%), Fuchs' endothelial dystrophy (6.7%), and keratoconus (3.3%). Majority of patients (54%) were involved in agricultural and construction work. Preoperative vision of 30% was PL, 20% had HM, 16.7% had CFCF and 23.3% had CF 0.5 meter. BCVA improved in 76.7% cases and there was no improvement in 23.3% cases and the causes were rejection due to ocular inflammation, graft infection, glaucoma and retinal pathology detected after surgery. Complications were AC reaction, persistent epithelial defect, filamentary keratitis, suture infiltrate, fistula, vascularization, graft infection, glaucoma, cystoid macular edema and rejection. Surgical success was achieved in 83.3% cases and therapeutic success in 100% cases.

Conclusion: Penetrating keratoplasty may be considered in patients with corneal blindness and refractory corneal ulcers as it can save the eye and bring back vision.

Keywords: Bullous Keratopathy, Corneal Opacity, Infectious Keratitis, Penetrating Keratoplasty, Re-graft

I. Introduction

WHO estimates that there are 45 million blind people in the world, of which 90% are in developing countries and around 60% reside in Sub Saharan Africa, China & India. According to 2011 census, the current population of India is 122 crores^[1], of which 1% total blindness constitutes about 1.22 crore. Corneal blindness constitutes about 1% of total blindness^[2], which means around 1.22 lakh people have bilateral corneal blindness in India. In addition, another 20,000-30,000 new cases of corneal blindness are being added annually.

According to National Programme for Control of Blindness (NPCB) 2001-2002 survey, major causes of blindness were^[2] Cataract 62.6%, Refractive Error 19.70%, Corneal Blindness 0.90%, Glaucoma 5.80%, Surgical Complications 1.20%, Posterior Capsular Opacification 0.90%, Posterior Segment Disorders 4.70%, Others 4.19%. Keratoplasty also known as corneal transplantation, is a surgical procedure in which the diseased cornea is replaced with a healthy donor cornea^[3]. Keratoplasty may be done for optical, tectonic, therapeutic and cosmetic purpose. The 2 main types are full thickness (penetrating keratoplasty) and partial thickness (lamellar keratoplasty).

This study was undertaken to assess the indications and demographic profile of patients undergoing penetrating keratoplasty and to assess the factors affecting visual outcome and complications of penetrating keratoplasty.

II. Materials And Methods

This is a prospective hospital based clinical analysis carried out on 30 patients admitted for penetrating keratoplasty.

Inclusion criteria: Patients undergoing penetrating keratoplasty for optical and therapeutic indications. Exclusion criteria: Patients in whom posterior segment anomalies are detected preoperatively and in whom penetrating keratoplasty is done for cosmetic purpose.

In the present study, surgical success of penetrating keratoplasty is defined as the graft remaining clear till the end of 6 months follow up. Therapeutic success in cases of non-healing infectious keratitis is defined as complete eradication of infection after penetrating keratoplasty.

An informed consent, detailed ocular and systemic history was taken. Ocular examination included the following:

- Visual acuity

- Slit lamp biomicroscopic examination to assess the position and extend of the corneal opacity or non-healing corneal ulcer. Corneal thinning, vascularization or anterior synechiae if present was noted. In cases with extensive vascularization, peritomy was done.
- Direct and Indirect Ophthalmoscopy was done in possible cases to rule out any posterior segment pathology.
- B-scan ultrasonography was done in all opaque corneas to rule out any possible retinal detachment.
- Keratometry was done for the fellow eye if cornea was clear and cataract extraction is being planned. In case of bilateral corneal opacity, standard K values were taken, ie. KH & KV 44.00.
- A-scan was done for both eyes for comparison of axial length and for IOL power calculation.
- Intraocular pressure measurement was done
- Lacrimal sac syringing was done in all cases.
- Schirmer's test was done for tear film function.
- Corneal scrapings were taken for Grams stain, KOH mount and culture in ulcer cases.

Investigations were also carried out screen diabetes mellitus and systemic hypertension in all patients. Appropriate control of systemic conditions were achieved before surgery.

2.1 Preoperative preparation of patients

- Eyelashes were cut and lid margins were cleaned thoroughly with povidone iodine.
- 2 % Lignocaine test dose was given.
- Gatifloxacin eye drops were instilled hourly on the eye to be operated.
- Injection Mannitol 200ml i.v stat when IOP was to be brought under control.
- Tab. Acetazolamide 250 mg 2 tabs was given 1 hour prior to surgery to make the eye soft and to counter the positive pressure.
- Injection Cefotaxime 1 gm i.v BD was started in all patients after test dose 1 hour prior to surgery.
- 1% Tropicamide and 5% phenylephrine eye drops were instilled 1 drop every 10 minutes for 1 hour, prior to surgery for pupillary dilatation in cases where cataract extraction was planned.

2.2 Anaesthesia

Analgesia and akinesia was achieved with peribulbar block consisting of a mixture of 2% lignocaine, adrenaline (1 in 10,000), 0.5 % bupivacaine and hyaluronidase was given in all cases. Facial block was given in few cases.

2.3 Surgical technique

With full aseptic precautions part was painted and draped. Lids were separated using Barraquer wire speculum.

Donor corneal button preparation:

Donor cornea with 3mm scleral rim was cut and separated from the donor eyeballs. Donor cornea was cleaned with sterile balanced salt solution and few drops of antibiotic eye drops were put on the cornea before trephination. The donor cornea with scleral rim was carefully placed on the Teflon block with the endothelial side up. An appropriate size trephine was fixed on the guillotine punch. Size of trephine varied from 7.5, 8.0 and 8.5 mm depending upon the size of opacity. The guillotine punch with trephine was carefully placed over the endothelial side of the donor cornea on the Teflon block and is trephined out. The donor button is carefully removed and placed in a sterile bowl and hydroxypropyl methylcellulose was applied on the endothelial side. The cut corneo scleral rim was send for microbiological examination.

Recipient bed preparation:

The trephine used for the recipient cornea was 0.5mm less than that used for donor cornea. The trephine was carefully placed over the recipient cornea and trephined to half thickness of cornea. Side port blade was used to make an entry in to the anterior chamber. Using Castroviejo's corneal scissors, full thickness of recipient cornea is cut along the already made trephine markings. The recipient cornea was cut in to two equal halves and was send for microbiological and histopathological examination.

The donor corneal button is placed carefully on the recipient bed and aligned well. Suturing of the donor cornea to the recipient bed is done with 16 interrupted sutures with 10-0 nylon in all cases. The first suture put at 12'o clock is the most important for the proper alignment of the donor cornea and the second suture put at 6'o clock determines postoperative astigmatism.

Rest of the cardinal sutures were put at 3'o clock and 9'o clock making sure that they are not too tight or loose. Rest 12 sutures were put radially around the donor button to the recipient bed. Anterior chamber was

maintained with air or balanced salt solution and was checked for any leaks. Sub conjunctival injection of gentamycin and dexamethasone was given. Eye speculum removed and the eye was patched till next day.

Additional procedures like synechiotomy, anteriorvitrectomy, cataract extraction with PCIOL implantation, IOL exchange with Scleral fixated IOL or posterior Iris fixated lens was done in required cases. There were 4 cases of bullous keratopathy with ACIOL. In 3 cases, IOL exchange was done. The ACIOL was explanted and SFIOL, posterior iris fixated lens and sulcus placement of PCIOL was done in these 3 cases. In 1 case, ACIOL was left in place and penetrating keratoplasty was carried out.

Intraoperative complications noted were difficulty in maintaining the anterior chamber, difficulty in releasing the synechiae, bleeding from iris vessels and vitreous loss.

2.4 Postoperative management:

- Injection Diclofenac 1 ampule i.m stat.
- Injection Cefotaxime 1 gm i.v BD was for 5 days
- Injection Dexamethasone 8mg i.v was given 8th hourly in required cases.
- Oral Acetazolamide 250mg TID for 3 days
- Oral analgesics sos
- Combination of gatifloxacin- prednisolone eyedrops instilled hourly
- Lubricant eyedrops 8 times a day
- Lubricant eye ointment 3 times a day

Oral prednisolone was given in required cases 1mg/kg/day and tapered over 6 weeks. All patients were examined under slitlamp biomicroscope daily and was discharged after a week depending on the condition of the graft.

2.5 Follow up

All patients were followed up at 1st week, 1st month, 3rd month and 6th month and was instructed to use antibiotic- steroid eyedrops regularly up till 6 weeks. Lubricant eye drops and gel were also continued. Cyclosporine 0.1% eyedrops was started 1 month post operatively. Patients were also advised to report immediately if redness, pain, blurring of vision or photophobia was present. At each follow up symptoms were noted, vision was recorded, slit lamp examination of the graft and IOP measurement was done.

2.6 Suture removal

Tight sutures, loose sutures, suture infiltrate, vascularization at suture site were indications for immediate removal. Otherwise, suture removal was initiated at 4- 6 months postoperatively. Postoperative glaucoma was treated with timolol eye drops 0.5% twice daily and tab. acetazolamide 250 mg TID.

2.7 Criteria for diagnosis of graft rejection

- Symptoms such as pain, redness and diminution of vision
- Presence of an initial clear graft postoperatively
- Rapid onset of haziness of graft
- Keratic precipitates on the graft
- Raised intra ocular pressure
- Presence of epithelial or endothelial rejection line
- Subepithelial deposits
- Favourable response to corticosteroids.

Rejection was treated with i.v methyl prednisolone 1 gm in 500ml dextrose OD for 3 days or oral prednisolone 1mg/kg/day in divided doses along with topical 1% prednisolone acetate eye drops hourly.

2.8 Criteria for diagnosis of graft failure

- Conjunctival and ciliary congestion
- Infiltrates extending to graft host junction
- Edematous graft with haziness extending to deeper layers
- Signs of uveitis like flare, synechiae and muddy iris.
- Progressive diminution of vision

III. Results

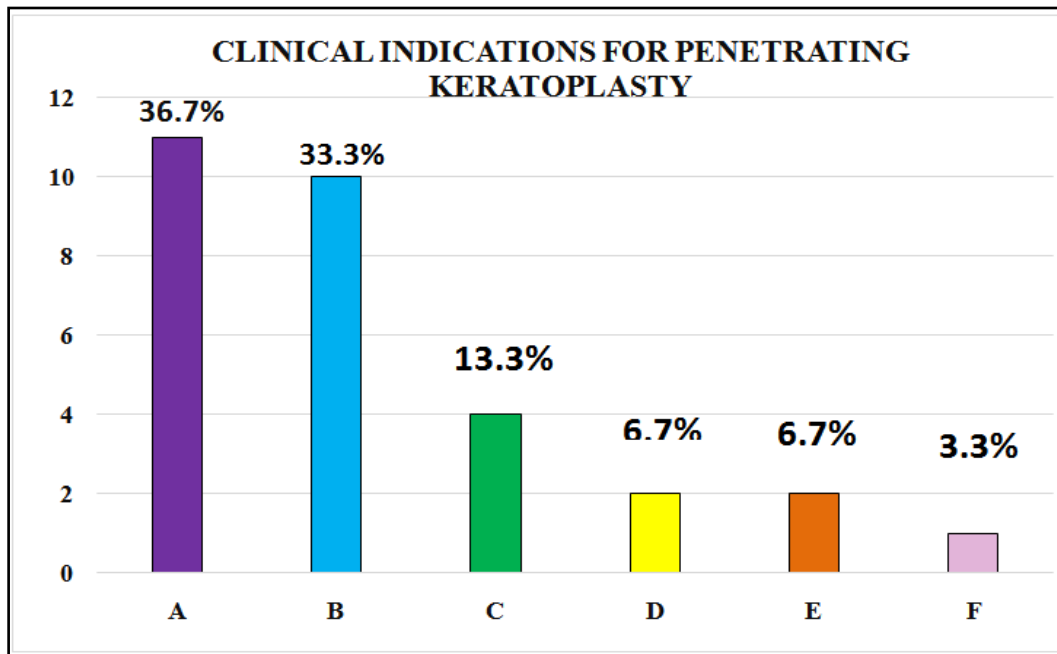
There were 30 cases who underwent penetrating keratoplasty of which 16 (53.3%) were males and 14 (46.7%) were females. Majority of the cases were in the 41-60 years (50 %) age group.

Table 1: Distribution Of Cases According To Age Group And Gender

Age of patient (years)	Males	Females	Total	Percentage
21- 40	2	3	5	16.67
41-60	10	5	15	50
61-80	4	6	10	33.33
Total	16	14	30	100

Most of the patients (54%) were involved active work like agriculture, construction and industrial work. Many of the women involved in house hold work also did part time ‘beedi’ making job. Maximum cases who underwent penetrating keratoplasty were from rural areas (83%). Majority of cases (93.33%) underwent penetrating keratoplasty for optical indication. Most common indication was corneal opacity 36.7%.

Chart 1



A	Corneal opacity
B	Bullous keratopathy
C	regraft
D	Fuch's endothelial dystrophy
E	Non healing infectious keratitis
F	keratoconus

Key to chart1

Chart 2 – Preoperative vision

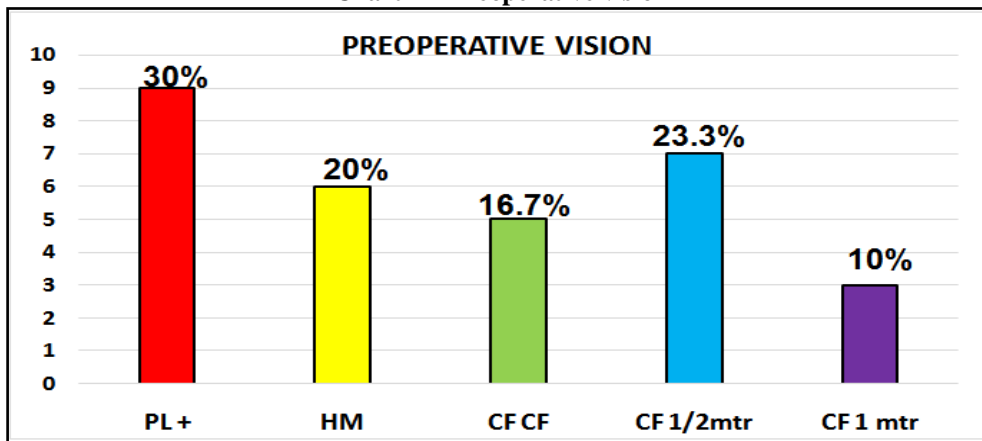


Table 2: Visual Acuity - Postoperative 1 Week

Vision acuity (1 week)	No. of cases	Percentage%
HM- CFCF	7	23.33
CF 0.5mtr - CF 3mtr	22	73.33
6/60 - 6/24	1	3.3
6/18 or better	0	0
Total	30	100

Chart 3: Visual Acuity – Postoperative 3 Months

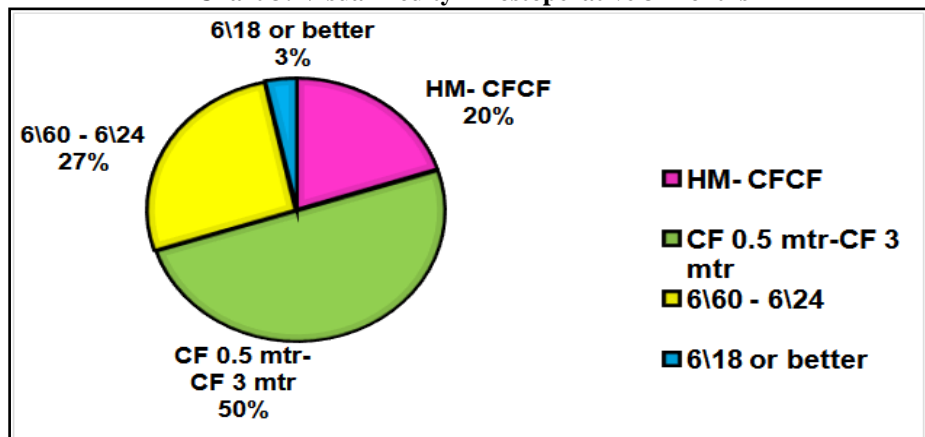


Chart 4: Visual Acuity - Postoperative 6 Months

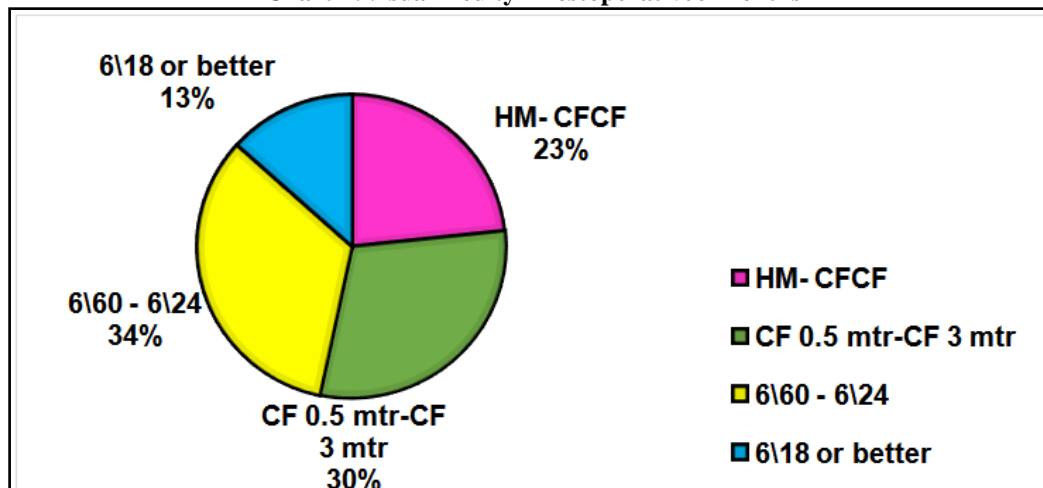


Table 3 Complications - Postoperative Day 1

Complications (POD 1)	No. of cases	Percentage%
Nil	23	76.7
Toxic anterior segment syndrome	4	13.3
Mild AC reaction	1	3.3
Epithelial defect	1	3.3
Vitritis	1	3.3
Total	30	100

Table 4 Complications - Postoperative 1 Week

Complications (1 week)	No. Of cases	Percentage %
Nil	22	73.3
Mild AC reaction	3	10
Epithelial defect	1	3.3
Vitritis	1	3.3
Peripheral anterior synechiae	1	3.3
High IOP	1	3.3
Cystoid macular edema	1	3.3
Total	30	100

Table 5 Complications - Postoperative 1 Month

Complications (1 month)	No. of cases	Percentage%
Nil	19	63.3
Mild AC reaction	1	3.3
High IOP	1	3.3
Persistent epithelial defect	1	3.3
Suture infiltrate	2	6.7
Suture fistula	1	3.3
Infectious keratitis	1	3.3
Cystoid macular edema	2	6.7
Rejection	2	6.7
Total	30	100

Table 6 Complications - Postoperative 6 Months

COMPLICATIONS (6 months)	No. of cases	Percentage %
Nil	21	70
Glaucoma	2	6.7
Superficial vascularization and rejection	1	3.3
Cystoid macular edema	2	6.7
Graft failure	4	13.3
Total	30	100

Glaucoma was noted in 2 of the cases, 1 adherent leukoma and 1 regrant where there was vitreous loss intraoperatively. 1 case with superficial vascularization showed rejection. There were 4 cases which showed rejection previously which ultimately went in to graft failure.

Chart 5: Percentage of Cases Showing Improvement In Visual Acuity At 6 Months Follow Up

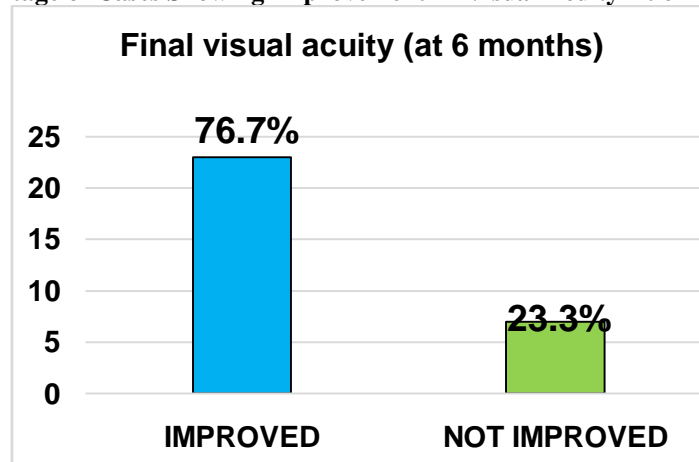


Chart 6 - Causes of No Improvement In Final Visual Acuity (7 Cases)

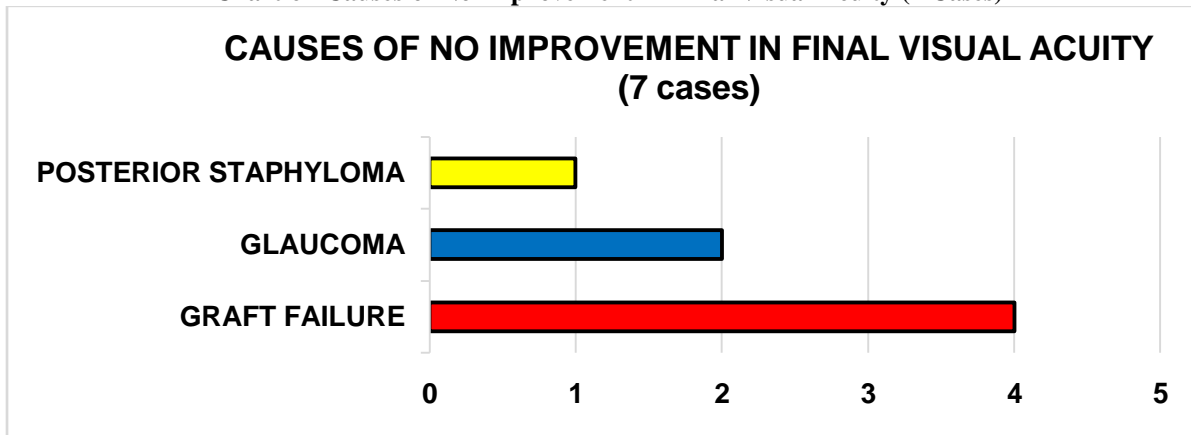
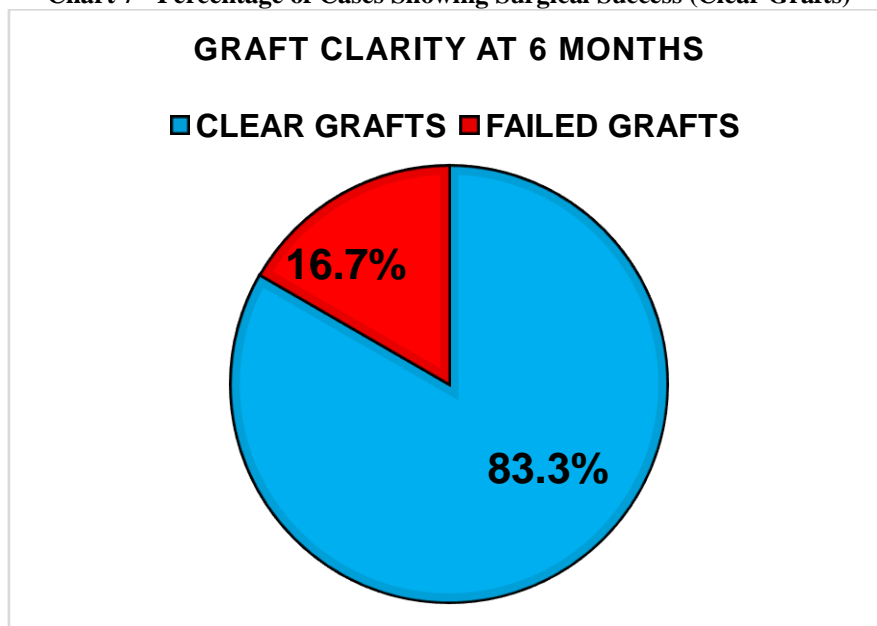


Chart 7 - Percentage of Cases Showing Surgical Success (Clear Grafts)



IV. Discussion

Penetrating keratoplasty can visually rehabilitate many patients who have corneal blindness. But the prognosis depends on the pathology that has caused the corneal blindness.

Of the 30 cases who underwent penetrating keratoplasty, 16 (53.3%) were males and 14 (46.7%) were females. Most of the patients were in the age group 41-60 years. Majority of the cases (83%) belonged to rural areas and 17% are from urban areas. Most of the patients (54%) were involved in active work like agriculture, construction and industrial work. Female patients had parttime job of 'beedi' rolling. All patients were followed up at 1 week, 1 month, 3 months and 6 months postoperatively.

The indications of penetrating keratoplasty varies from one country to another. India being a developing country, has majority of its people working in agricultural field and therefore are more prone to injuries and infections. In the present study, majority of the cases (93.33%) were operated for optical purpose and 6.67% for therapeutic purpose. The most common indication of penetrating keratoplasty in the present study was corneal opacity (36.7%) including adherent leukoma. Among the corneal opacities 81.8% were following infectious keratitis and 18.2% were post traumatic. There was 1 case of corneal opacity with vascularization in 2 quadrants. This graft showed signs of rejection in the post-operative follow up period.

Shilpa A. Joshi et al^[4] found that the extent of vascularization of recipient bed correlates strongly with the graft survival. Non vascularized corneas survived longer than those with less than or more than two quadrants of vascularization.

The second most common indication in the present study was bullous keratopathy (33.3%). Majority of the bullous keratopathy was due to PCIOL (50%), followed by ACIOL (40%) and aphakic bullous keratopathy in

1 case. Other less common indications were regrant (13.3%), non-healing infectious keratitis (6.7%), fuch's endothelial dystrophy (6.7%), and keratoconus (3.3%).

Dandona L, Ragu K et al (1997)^[5] also reported similar observation in their study. They noted that corneal scarring was the most common indication for penetrating keratoplasty in India (28.1%). Keratitis accounted for 50.5% of this corneal scarring, trauma accounted for 21.0%, and etiology was undetermined in 25.6% of cases. According to them, pseudophakic bullous keratopathy, keratoconus and fuch's endothelial dystrophy are less common indications of penetrating keratoplasty. But in the present study bullous keratopathy was the second most common indication.

Among the 11 cases of corneal opacity, there were 4 adherent leukomas. In 1 case the iris was completely adherent to the cornea and aphakia was noted. There was intra operative vitreous loss in this case and developed high IOP postoperatively. All the 4 grafts remained clear at 6 months follow up, but in 2 cases there was no visual improvement due to glaucoma and posterior staphyloma which was detected after penetrating keratoplasty.

Out of the 11 corneal opacity cases, surgical success was achieved in 8 of the grafts and 3 grafts were hazy at 6 months follow up. The 3 grafts got rejected due to vascularization, inflammation and infectious keratitis. Shilpa A Joshi et al^[4] also reported that corneal scar had good prognosis.

There were 10 cases of bullous keratopathy and all the cases achieved surgical success and improvement in visual acuity at 6 months follow up. Similar reports were noted by Schanzlin D et al^[6] who found that after keratoplasty, the mean visual acuities of aphakic bullous keratopathy and pseudophakic bullous keratopathy patients improved significantly from preoperative vision.

In 2 cases of bullous keratopathy due to ACIOL where IOL exchange was done for SFIOL and posterior iris fixated lens, cystoid macular edema was noted postoperatively. Schanzlin Det al^[6] also described that cystoid macular edema and glaucoma were the most common causes of visual acuities worse than 20/40 in bullous keratopathy. Intraocular lens removal did not significantly affect either visual acuity or macular complications after keratoplasty.

There were 4 cases of regrant. All of them achieved surgical success at 6 months and 3 of them had improvement in visual acuity. In 1 case due to vitritis and glaucoma there was no improvement in vision. Patel NP et al^[7] stated that failed grafts are increasing as an indication for penetrating keratoplasty and the graft clarity and visual acuity results continue to be very good, supporting the use of repeat corneal transplantation.

Fuch's endothelial dystrophy was seen in 2 cases and both were females. Dandona et al^[5] also found female preponderance in corneal dystrophies. Both the patients had clear grafts and better visual acuity at 6 months follow up.

Therapeutic penetrating keratoplasty was done in 2 cases of non-healing infectious keratitis. Therapeutic success was achieved in both as the infection was eradicated. But both the grafts showed rejection by 1 month and 3rd month and failed ultimately, in spite of adequate control of infection. In a study by Lomholt et al^[8] also showed that microbial keratitis had a high risk of failure. Hence penetrating keratoplasty should be done in quiet eye. Panda et al (1995)^[9] stated that penetrating keratoplasty has a scope in refractory corneal ulcers.

There was only 1 case of Keratoconus who underwent penetrating keratoplasty. There was improvement in visual acuity and the graft was clear at 6 months. In a study by Arun Brahma et al^[10] there was rapid improvement of vision in keratoconus cases as a result of uncomplicated penetrating keratoplasty.

Time interval between enucleation and corneal transplantation varied from 6 to 48 hours. Most of the corneas were stored in moist chamber as it was economic and easier method of storage. Most of the cases (86.66%) were operated within 24 hours duration. In 2 cases surgery was done after 48 hours, as these corneas were preserved in M K medium.

Good quality donor tissue was used in maximum cases (90%), excellent quality in 6.7% and very good quality in 3.3% cases.

The donor button size was 7.5 mm in 60% cases. Larger donor button of 8.0, 8.2 and 8.5 mm was used depending on the size of the opacity. Donor button used was 0.25 - 0.50 mm larger than recipient button. There was no association between the donor button size and graft clarity in this study.

Preoperative visual acuity in majority of the cases (30%) was PL, 20% had HM, 16.7% had CF, 23.3% had CF0.5 meter.

Penetrating keratoplasty with cataract extraction was done in 11 cases. Anterior vitrectomy was done in 2 cases (1 adherent leukoma and 1 regrant following adherent leukoma). There were 4 cases of bullous keratopathy with ACIOL. In 3 cases, IOL exchange was done. The ACIOL was explanted and SFIOL, posterior iris fixated lens and sulcus placement of PCIOL was done in these 3 cases. In 1 case, ACIOL was left in place and penetrating keratoplasty was carried out. In 1 case of aphakic bullous keratopathy, SFIOL implantation was done 3 months after penetrating keratoplasty and the graft remained clear.

On 1st postoperative day complications were noted in 7 cases. Toxic anterior segment syndrome in 4 cases, mild AC reaction, epithelial defect, vitritis was seen in others.

In the 1st week follow up, mild AC reaction, epithelial defect, high IOP, vitritis, Peripheral anterior synechiae (in 1 of the therapeutic grafts) and cystoid macular edema was noted.

At 1 month follow up, mild AC reaction, high IOP, suture fistula, persistent epithelial defect (PED) and infectious keratitis was seen in 1 case each. Suture infiltrate, Cystoid macular edema and rejection was noted in 2 cases each.

At 3 months high IOP and PED persisted. Suture infiltrate, suture fistula, superficial vascularization and filamentary keratitis was noted in 1 case each. Rejection was noted in 4 cases.

At 6 months the complications noted were glaucoma in 2 cases, superficial vascularization with rejection in 1 case, 4 cases which showed rejection previously went into graft failure and 2 cases had cystoid macular edema. Both the therapeutic grafts went in to rejection at 1 month and 3rd month and failed ultimately. 1 patient acquired infectious keratitis 1 month postoperatively and went into rejection and failure later. 1 corneal opacity post infectious keratitis went into rejection at 1 month due to ocular inflammation and went in to graft failure.

Only 10-0 nylon sutures were used. Sutures that showed vascularization and infiltrate was removed. Suture fistula with active leak was treated with tissue adhesive and bandage contact lens. Filamentary keratitis was treated with lubricant eyedrops and debridement of the filaments. Persistent epithelial defect was treated with frequent use of lubricant eye drops and ointment.

Rejection was treated with i.v methyl prednisolone 500mg OD for 3 days or oral prednisolone 1mg/kg/day in divided doses along with topical 1% prednisolone acetate eye drops hourly.

Postkeratoplasty glaucoma (PKG) is one of the challenging issues important for the survival of the graft. The incidence reported was between 9% and 35%^[11]. It is one of the most serious complications following penetrating keratoplasty and the second leading cause of graft failure after graft rejection^[12]. Its diagnosis and management are much more difficult than glaucoma. The diagnosis of PKG was made if IOP rise persisted after one month following PK in the presence of glaucomatous optic disc changes

In the present study, glaucoma was noted in 2 cases at 6 months follow up, 1 adherent leukoma and 1 regraft. Both the cases were aphakic and there was vitreous loss intraoperatively. They were left aphakic due to posterior vitreous pressure. These cases were on timolol eye drops 0.5% twice daily and tab a cetazolamide 250 mg TID.

Yildirim N et al^[13] reported that patients with pseudophakia and aphakia prior to penetrating keratoplasty and combined surgery were at risk for developing post keratoplasty glaucoma.

At 6 months follow up most of the cases (76.7 %) improved from their preoperative visual acuity. 7 cases (23.3%) did not improve. The causes of no improvement in visual acuity were due graft failure in 4 cases due 2 therapeutic grafts, and 2 cases of ocular inflammation and infectious keratitis, probably due to poor patient compliance. 3 clear grafts did not improve because of high IOP, vitritis and posterior staphyloma.

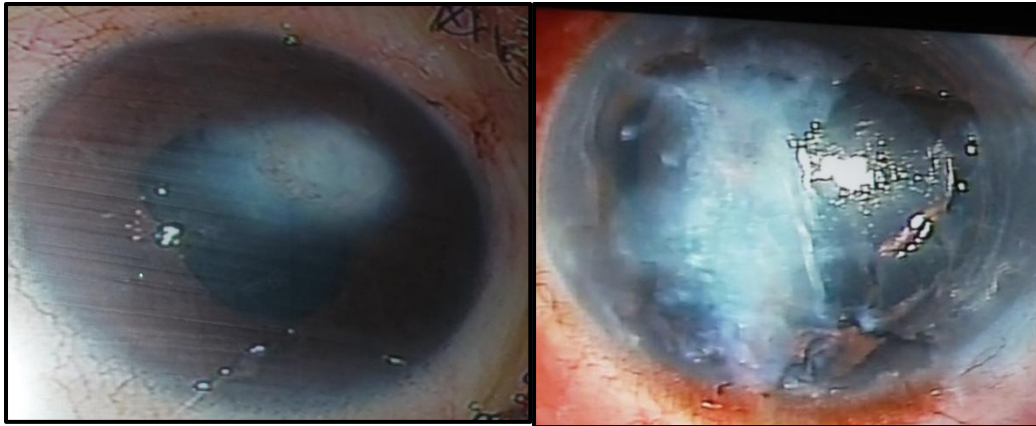
At 6 months follow up, out of the 30 cases, 25 grafts achieved surgical success and 5 graft remained hazy. Causes for failure of graft was rejection due to vascularization, inflammation and infection of graft. 2 therapeutic grafts, 1 graft due to infectious keratitis and 1 graft due to ocular inflammation went into failure. There was 1 case with vascularization on the graft which showed rejection at 6 months postoperative period. This patient had improvement in visual acuity from preoperative vision but the graft remained hazy at 6 months follow up and was going in to failure.

Shilpa A. Joshi et al (2012)^[4] also described that non vascularized cornea have better graft survival than those with less than 2 or more than 2 quadrant vascularization.

V. Figures

INDICATIONS OF PENETRATING KERATOPLASTY

CORNEAL OPACITY - post infectious keratitis and post traumatic

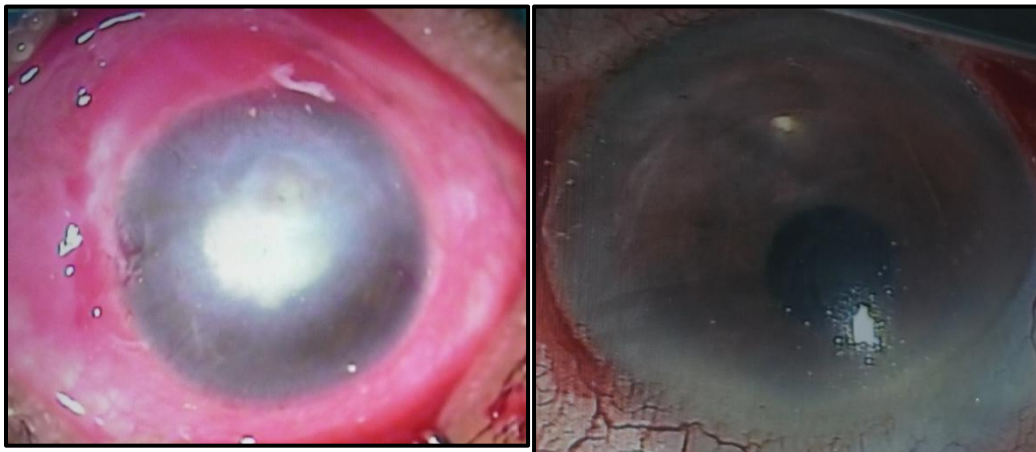


NON HEALING INFECTIOUS

BULLOUS KERATOPATHY

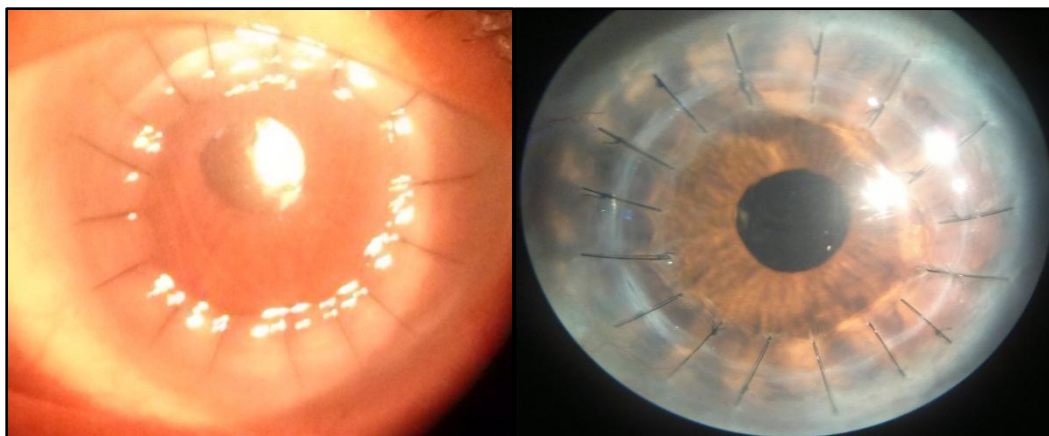
KERATITIS

Post ACIOL

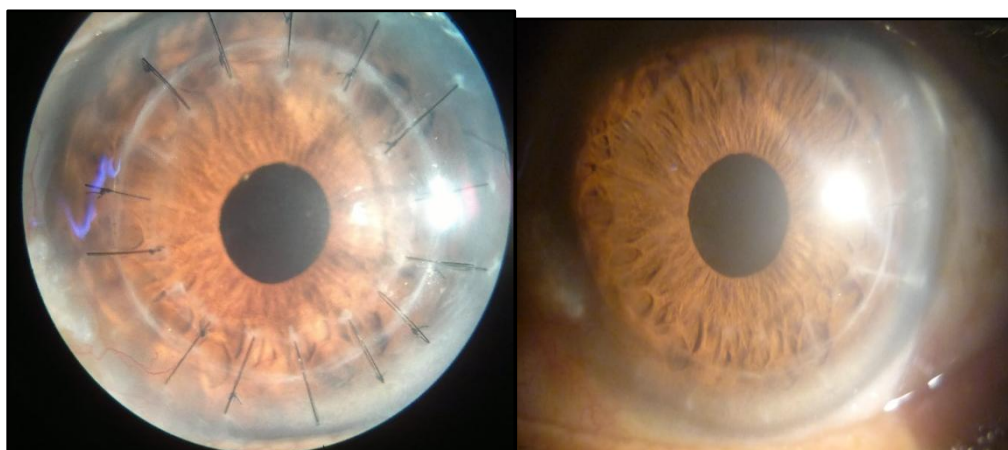


FOLLOW UP

POST OP 1 WEEK POST OP 1 MONTH



POST OP 6 MONTHS AFTER SUTURE REMOVAL



VI. Conclusion

After assessing the demographic profile of patients undergoing penetrating keratoplasty, it was found that most of the patients were males and were involved in active work like agriculture, construction and industrial work. Most of the patients came from rural areas.

The commonest indication for penetrating keratoplasty was corneal opacity followed by bullous keratopathy and re-raft. Good prognosis cases were bullous keratopathy, Fuchs' endothelial dystrophy, corneal opacity and keratoconus in the present study. Vascularized corneal opacity has high chance of going into rejection. In case of non-healing corneal ulcers, therapeutic success was achieved as penetrating keratoplasty could eradicate infection and save the eye. Since the therapeutic grafts are known to go in to failure, an optical keratoplasty can be done once the eye is quiet.

Final visual acuity improved from preoperative vision in majority of the cases. The factors which affected the postoperative visual outcome in few cases were mainly rejection due to glaucoma, infectious keratitis due to low patient compliance, posterior staphyloma detected postoperatively and graft infection in therapeutic keratoplasty.

If cataract is present it is better to do cataract extraction along with penetrating keratoplasty. Removing cataract after keratoplasty is a risk for graft rejection. But if clear lens is noted then only penetrating keratoplasty is done. In aphakic eye and in ACIOL decompensation, SFIOL has showed surgical success at 6 months follow up.

The complications of penetrating keratoplasty such as anterior chamber reaction, persistent epithelial defect, filamentary keratitis, suture infiltrate, suture fistula can be treated with appropriate measures. While others like graft infection, glaucoma, cystoid macular edema and rejection was difficult to treat. In the present study surgical success was achieved in majority of the cases (83.3%). Causes for failure of graft in 16.7% cases was rejection due to vascularization, inflammation and infection of graft.

Thus penetrating keratoplasty done in ideal conditions has huge success rate and can bring back light into the lives of many who have corneal blindness.

Acknowledgement

I express my heartfelt gratitude to Dr. Hrishikesh Amin, Professor, Department of Ophthalmology, Justice K. S. Hegde Charitable Hospital, Deralakatte, Mangalore for his invaluable guidance, supervision and words of wisdom which helped me in the completion this study. I am immensely thankful to the HOD, Dr. Jayaram Shetty, Department of Ophthalmology, who selected this topic for study and has encouraged me in making it a success. I am extremely grateful to Dr. Vijay Pai, Professor, Department of Ophthalmology for all the enlightening discussions that helped me in the progress of this work.

References

- [1]. Population census of India 2011 (<http://censusindia.gov.in>)
- [2]. MOH& FW (NPCB), Rapid Assessment of Avoidable Blindness-India. Report 2006 -2007
- [3]. Manthosh R, Namrata S, Rasik B V. Indications and outcomes of penetrating keratoplasty, 1 st edition pg 6-15 jaypee brothers 2002
- [4]. Joshi SA, Jagdale SS, More PD, Deshpande M. Outcome of optical penetrating keratoplasties at a tertiary care eye institute in Western India. *Indian J Ophthalmol.* 2012 Feb;60(1):15–21
- [5]. Dandona L, Ragu K, Janarthanan M, Naduvilath TJ, Shenoy R, Rao GN. Indications for penetrating keratoplasty in India. *Indian J Ophthalmol.* 1997 Sep;45(3):163–8.

- [6]. Schanzlin D, Robin J, Gomez D, Gindi J, Smith R. Results of penetrating keratoplasty for aphakic and pseudophakic bullous keratopathy. *American journal of ophthalmology*. 1984;98(3):302-12
- [7]. Patel NP, Kim T, Rapuano CJ, Cohen EJ, Laibson PR. Indications and outcomes of repeat penetrating keratoplasty, 1989- 1985. *Ophthalmology* 2000 april; 107 (4); 719- 724
- [8]. Lomholt JA, Ehlers N. Graft survival and risk factors of penetrating keratoplasty for microbial keratitis. *ActaOphthalmologicaScandinavica*. 1997;75(4):418-22
- [9]. Panda A, Khokhar S, Rao V, Das GK, Sharma N. Therapeutic penetrating keratoplasty in nonhealing corneal ulcer. *Ophthalmic surgery*. 1994;26(4):325-9
- [10]. Brahma A, Ennis F, Harper R, Ridgway A, Tullo A. Visual function after penetrating keratoplasty for keratoconus: a prospective longitudinal evaluation. *British journal of ophthalmology*. 2000;84(1):60-6.
- [11]. J. W. Karesh and V. S. Nirankari, "Factors associated with glaucoma after penetrating keratoplasty," *American Journal of Ophthalmology*, vol. 96, no. 2, pp. 160–164, 1983
- [12]. J. J. Ing, H. H. Ing, L. R. Nelson, D. O. Hodge, and W.M. Bourne, "Ten-year postoperative results of penetrating keratoplasty," *Ophthalmology*, vol. 105, no. 10, pp. 1855–1865, 1998.
- [13]. Yildirim N, Gursoy H, Sahin A, Ozer A, Colak E. Glaucoma after penetrating keratoplasty: incidence, risk factors, and management. *Journal of ophthalmology*. 2011;2011.