

Giant inguinal hernia.. A challenge to Surgeons

Gurjit Singh¹, Digvijay Singh Jadhav², Mackson Nongmaithem³, Iqbal Ali⁴
^{1,2,3,4}(Department of Surgery, Dr.D.Y. Medical College/Dr.D.Y Patil Deemed University, Pimpri, Pune, India)

Abstract: Giant inguinal hernias are rare . A case of giant inguinal hernia in a 67-year-old male with discomfort in performing his daily chores is reported. Patient had a giant inguinal hernia (Rt) which was irreducible, non tender & had no cough impulse. Elective hernia repair via inguinoscrotal approached revealed small & large intestines, omentum as contents. Orchidectomy, omentectomy & reduction of contents into abdominal cavity with the help of infraumbilical midline incision & right meshplasty was done without any complication. He recovered uneventfully. The management of GIH can be demanding and challenging.. Its management requires careful pre- operative preparation, close intra & post operative monitoring to ensure a successful outcome.

Keywords: giant, irreducible, Elective

I. Introduction

Giant Inguinoscrotal hernias(GIH) are defined as hernias that extent below the midpoint of inner thigh in standing position[1]. Sometimes penis can be found buried inside the scrotum causing urine to dribble over the already stretched out scrotal skin. This can result in excoriation of the skin. Complications like intestinal obstruction, strangulation[2] are fatal as there are high chances of developing bowel ischaemia and perforation. Giant inguinal hernias are rare. These are present due to neglect[3].The management is quite challenging and demanding specially when associated with complications. We report a case of an irreducible giant inguinal hernia reaching almost upto knee.

II. Case report

A 67 year old patient presented with history of irreducible right inguino – scrotal swelling since 15 years. He experienced increasing discomfort in lower abdomen while performing his daily chores during the preceding two weeks. There was no difficulty in passing stools or urine.

He was detected to have an irreducible, non tender right inguino-scrotal swelling with a dimension of 25 × 20 cms reaching just above his right knee (Fig.1). The scrotal and penile skin were stretched and the penis was almost buried in the swelling. Scrotal skin was normal. The right testis was palpable. Bowel sounds could be heard within the swelling. The abdomen was slightly distended but soft.

After a meticulous preoperative work up he was taken up for surgery. The hernia was approached through an extended inguinal incision. Sac contained caecum, appendix, part of ascending colon, transverse colon, loops of bowel & omentum (Fig.2). Right testis was atrophic.

To facilitate reduction, peritoneal cavity was opened up by a infraumbilical midline incision .The internal inguinal ring was widened in order to replace contents into peritoneal cavity after performing omentectomy & orchidectomy. The internal ring was obliterated using 2-0 prolene. The posterior wall was strengthened by placing prolene mesh & wound closed in layers.

He was closely monitored for any features of abdomen compartment syndrome. However he had uneventful postoperative recovery with both wounds healing by primary intention.

Patient has been followed up for a period of one month till date. Scrotal skin has shrunken in size & there is no evidence of any respiratory problem or recurrence.

III. Discussion

Giant inguinoscrotal hernias(GIH) are defined as hernias that extend below the midpoint of inner thigh in standing position[1]. They are uncommon in developed countries. The massive size of these hernias can interfere with walking & other routine work. Sometimes penis can be found buried inside the scrotum causing urine to dribble over the already stretched out scrotal skin. The ipsilateral spermatic cord will be greatly elongated and obviously prone to torsion. The testis in most of the cases is atrophic as was found in our case. Besides interfering in the daily activities such hernia can present with obstruction, incarceration, strangulation & perforation[4].

Small bowel and omentum are the common contents of the hernia sac. However stomach, caecum, appendix, ascending colon, transverse colon, sigmoid colon, urinary bladder & ovaries have also been reported

amongst the contents [5] A case of herniation of the kidney and ureter has also been reported[6]. Rarely GIH is associated with intestinal malrotation[7] .

In our case, penis was buried in the scrotum but there was no evidence of any ulceration, excoriation or infection of the scrotal skin. Caecum, appendix, ascending and transverse colon along with most of the small bowel and omentum were found to be the content of the hernia sac.

In patients with GIH the abdominal contents remains outside the abdominal cavity therefore the capacity of the abdominal cavity is reduced. The herniated contents have thus lost the “right to domain.” Repositioning of the viscera in such an abdomen may lead to sudden increase of intra – abdominal and intra-thoracic pressure. This can lead to respiratory compromise and multi-organ failure resulting in death [4].

The management of GIH can be demanding and challenging . The physiological changes associated with the loss of domain can pose a risk of increased complications during surgery and the post operative period[8]. To address the problems associated with this loss of domain, procedures like debulking of abdominal contents or measures to enlarged the abdominal cavity have been advocated. Extensive bowel resections, for example total or hemicolectomy as well as omentectomy and even small bowel resections have been described.

In elective repair progressive pneumoperitoneum has been used to increase the abdominal space[9]. However, it has failed on several times in case of giant hernias[10].

A new classification for GIH and recommended procedures have been suggested by Trakarnsagna. A et al[11]. Several musculocutaneous flaps have been used and component separation techniques have also been described[4].

Merret et al. advocated a technique for giant inguinal hernia involving the reduction of hernia[12]. In this technique repair of hernial orifices with Marlex mesh and the creation of a midline abdominal wall defect to increase the intra-abdominal capacity followed by covering this defect with Marlex mesh with a rotation flap of inguinoscrotal skin has been described.

In our case, we did omentectomy, orchidectomy which helped in repositioning the contents in the abdominal cavity. Placement of mesh and obliteration of right inguinal canal was undertaken to prevent recurrence of hernia.

Management of reduntant scrotal skin is another Important consideration. Most of the authors agree that the scrotal skin should be left reduntant , as it retracts due to contraction of dartos muscle[5]. It also serves as a safety net , because if the patient develops respiratory compromise post operatively, the bowel can temporarily be returned to the scrotum. In our case too it was left intact & it retracted considerably within a short period of four weeks(fig.3).

IV. Figures

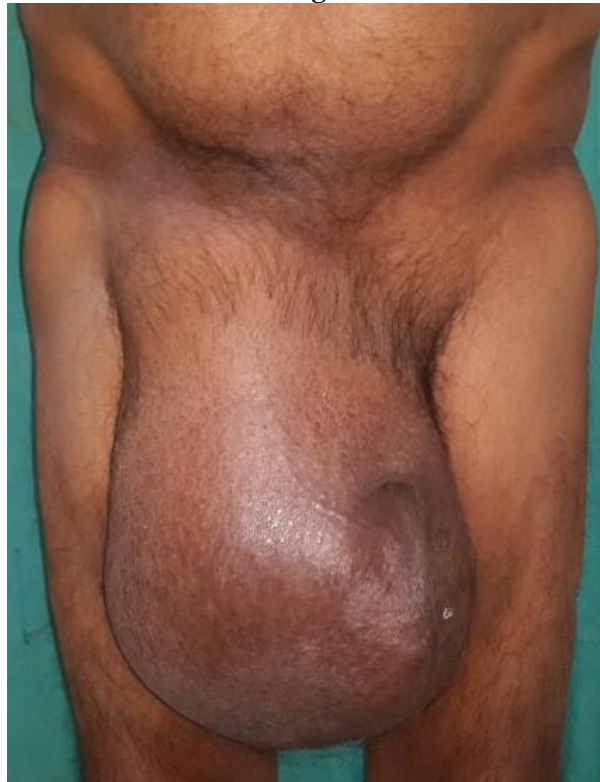

Fig 1 – Giant inguinal hernia with buried penis , reaching just above right knee.

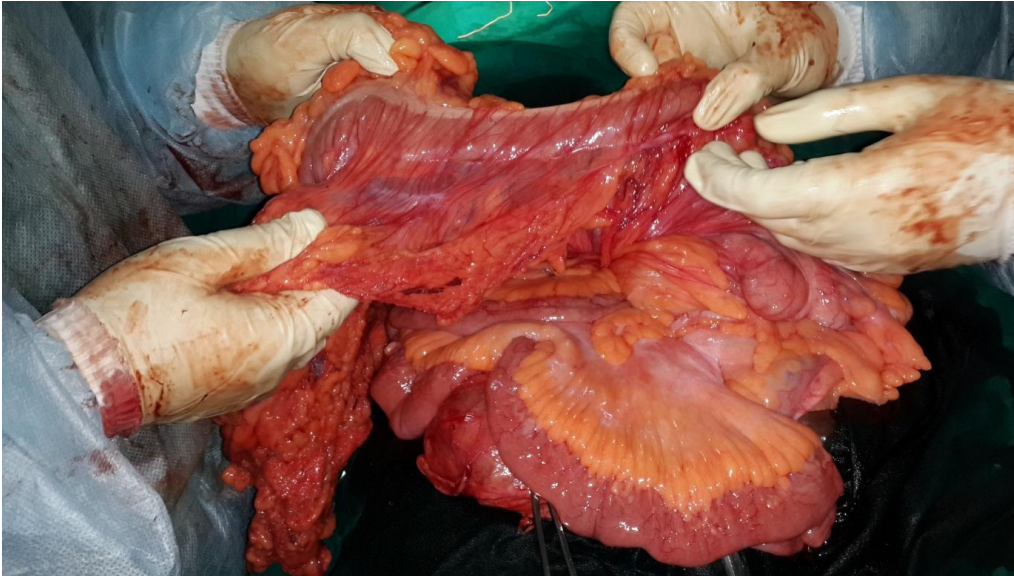


Fig 2 – Contents of Giant inguinal hernia sac showing Transverse colon(TC), Ileocaecal Junction(IC JN), Small Bowel(SB) & Omentum(Om)

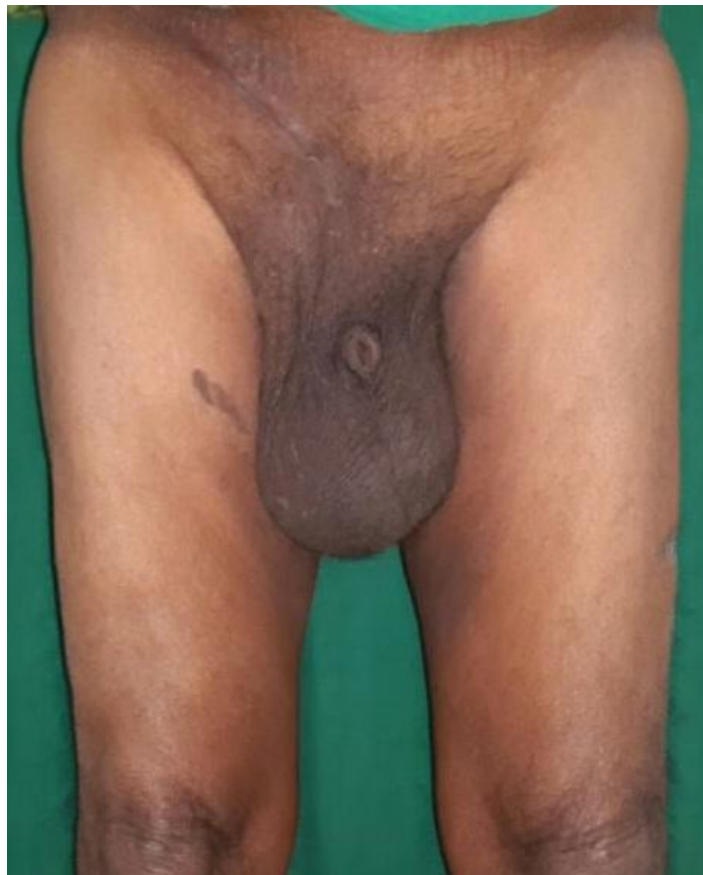

Fig 3 – Post operative healthy scar and retracted scrotal skin

V. Conclusion

To conclude , GIH is a challenging problem to the treating surgeon especially when it presents as an emergency with obstruction. Chance of intra abdominal hypertension leading to Abdomen Compartment Syndrome upon successful reduction of the herniated abdominal contents is always a cause for concern. Its management requires careful pre- operative preparation and close intra & post operative monitoring to ensure successful outcome.

References

- [1]. Sarakbi W.Al., Agrawal A, Taffinder A. A giant inguinoscrotal hernia: a case report and review of the literature. *Grand rounds* 2005;5:46-48.
- [2]. Burke TP, Joyce KM, Ahmed K, Waters PS, Khan W, Barry K. Giant inguinoscrotal hernia: An emergency presentation with life threatening sepsis. *2014;5(6):456-58(A1)*
- [3]. Patsas, A., Tsiaousis, P., Papaziogas, B., Koutelidakis. I., Goula, C. & Atmatzidis, K.(2010). "Repair of a Giant Inguinoscrotal Hernia," *Hernia*.2010;14(3):305-7.(A2)
- [4]. Ikhwan SM, Saiful AS, Ibariyah MI, Zaidi Z. Giant Inguino- scrotal Hernia: Repair and Management. *Journal of Dental and Medical sciences*.2013;4:42-5.
- [5]. Tahir M., Ahmed F.U., Seenu V. Giant inguinoscrotal hernia: case report and management principles. *Int J Surg*. 2008;6:495–97.
- [6]. Wietzenfeldt M.B., Brown B.T., Morillo G., Block N.L. Scrotal kidney and ureter: an unusual hernia. *J Urol*. 1980;123:437–438.
- [7]. Lee SE. A case of giant inguinal hernia with intestinal malrotation. *Int J Surg Case Rep*. 2012;3(11):563-4.
- [8]. Vasiliadis K, Knaebel HP, Djakovic N, Nyarangi-Dix J, Schmidt J, Büchler M. Challenging surgical management of a giant inguinoscrotal hernia: report of a case. *Surg Today*. 2010; 40: 684-7.
- [9]. McAdory RS, Cobb WS, Carbonell AM. Progressive preoperative pneumoperitoneum for hernias with loss of domain. *Am Surg*.2009;75:504-508.
- [10]. Merrett ND, Waterworth MW, Green MF. Repair of giant inguino scrotal inguinal hernia using marlex mesh and scrotal skin flaps. *Aust N Z J Surg* 1994;64:380-383.
- [11]. Trakarnsagna A, Chinswangwatanakul V, Methasate A, Swangsri J, Phalanushitthepha C, Parakonthon T.et al. Giant inguinal hernia: Report of a case and reviews of surgical techniques. *2014;5:868-72*.
- [12]. Merrett, N. & Biankin, A. "Giant Inguinal Hernia Containing Right "Colon Repaired Using the Prolene Herniasystem." *ANZ Journal of Surgery*.2009;79(1-2): 92-3.