

## Craniofacial Fibrous Dysplasia—A Case Report and Review of Literature

Mohammed Sheikh<sup>1</sup> B.D.S, Hiba Obad<sup>2</sup> B.D.S

<sup>1</sup>Department of oral and Maxillofacial Pathology, Faculty of Oral & Dental Medicine - Cairo University

<sup>2</sup>Department of oral and Maxillofacial Surgery, Faculty of Oral & Dental Medicine - Cairo University

**Abstract:** Fibrous dysplasia is a developmental skeletal condition characterized by replacement of normal bone with cellular fibrous connective tissue. The genetic predisposition is suspected to be the etiology. Fibrous dysplasia is classified as monostotic or polyostotic or as a component of McCune-Albright syndrome. The clinical findings show asymptomatic growth of the involved bone, which produces facial Asymmetry. Radiographically, the appearance differs with the stage of development and amount of bony matrix within the lesion. Microscopic examination shows cellular fibrous tissue with spindle-shaped cells and immature trabeculae of woven bone without osteoblasts rimming.

**eywords** – fibrous dysplasia; craniofacial dysplasia; fibro-osseous lesion

### I. Introduction

Fibrous dysplasia is a condition characterized by excessive replacement of normal bone by fibrous tissue. It is a benign disorder of unknown etiology. There are two major types : monostotic that involves a single bone and polyostotic that involves multiple bones (Zanetti & Gamba, 2007) .

It may form part of the McCune-Albright syndrome (MAS) or of the Jaffe- Lichtenstein syndrome (JLS). JLS is characterized by polyostotic FD and café-au-lait pigmented skin lesions, while MAS has additional features of hyperfunctional endocrinopathies manifesting as precocious puberty, hyperthyroidism, or acromegaly. FD is caused by GNAS1 (guanine nucleotide-binding protein,  $\alpha$ -stimulating activity peptide 1) gene mutation leading to abnormal proliferation and differentiation of pro-osteoblasts. (Agarwal et al., 2014) .

The monostotic fibrous dysplasia is the most common form of fibrous dysplasia, comprising 70% of cases, most likely to occur at puberty. Usually the monostotic lesion presented unilateral and will involve the femur, tibia or ribs, with 25% occurring in the bones of the skull (Zenn & Zuniga, 2001).

The term “craniofacial fibrous dysplasia” (CFD) is used to describe fibrous dysplasia that confined to adjacent bones of the craniofacial skeleton. Most cases of craniofacial fibrous dysplasia cannot be truly categorized as monostotic as the lesions involve multiple adjacent bones of the .

The radiographic appearance reflects the histological structure. If there is an excessive osseous element, the lesion appears more opaque. A mixture of fibrous and bony elements produces a ground glass appearance, while predominance of fibrous tissues produces a radiolucent appearance (Bertoni et al., 2004) .

The microscopic appearances show spindle cells with interspersed trabeculae of immature woven bone, devoid of rimming osteoblasts or osteoclasts. The trabeculae consist of immature, woven bone without osteoblasts (Agarwal et al., 2014) . craniofacial skeleton. Also they are not truly polyostotic because bones outside the craniofacial skeleton are spared. (Menon et al., 2013)

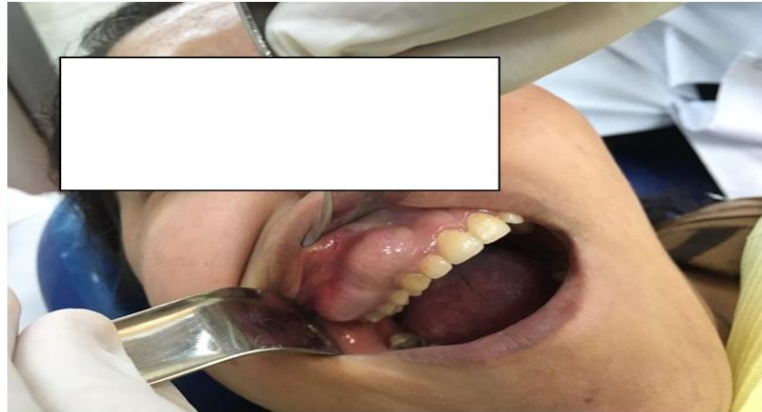The treatment should be delayed until after skeletal maturity has been reached. It consists of either conservative contouring or radical excision with immediate reconstruction. The surgical option choice depends on many factors: site of the lesion, rate of growth, aesthetic disturbance, functional disruption and the availability of a multi-disciplinary team (Guruprasad & Chauhan, 2012).

This article aims to present a clinical case of craniofacial fibrous dysplasia in maxilla, proceeding with its surgical correction and to make a review of literature, describing the most important aspects.

### II. Case Report

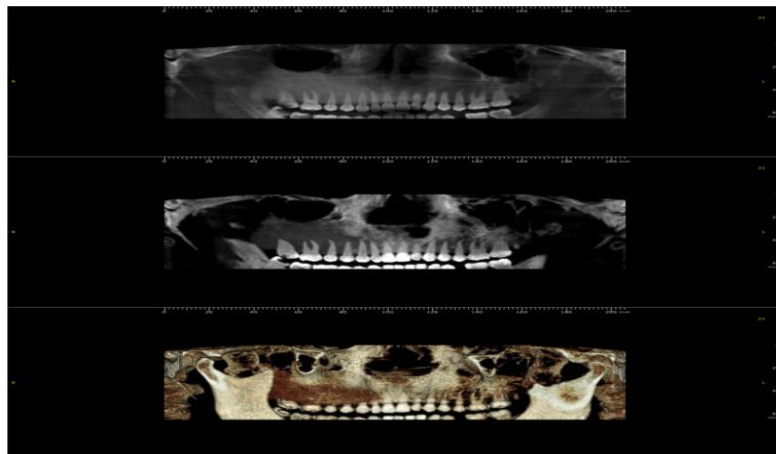
A 30-year-old female patient reported to the outpatient clinic of the Department of Oral Surgery at Faculty of Dentistry –Cairo University with a chief complaint of asymptomatic hard swelling in the Upper right alveolar bone since 8 years ago which started as a small hard swelling then enlarged gradually . On extraoral examination, facial asymmetry was slight evident. On intraoral examination, a single well-defined swelling was evident from upper right lateral incisor to right maxillary tuberosity with normal gum color, the related teeth were vital.

The hard swelling measured approximately 3 X 3 cm in size and was roughly oval in shape. The swelling was not tender and hard in consistency. (Fig. 1).

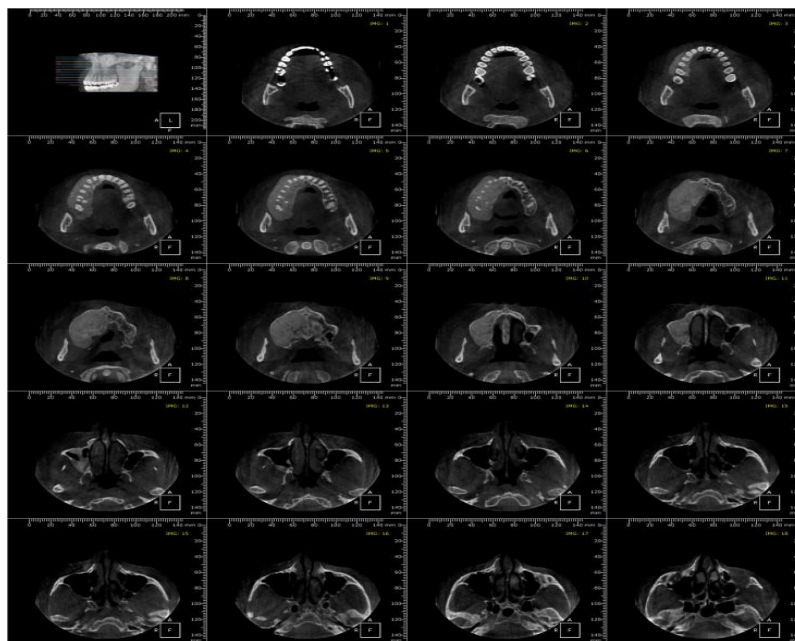


**Figure 1.** A single well-defined swelling evident on Upper right alveolar bone from upper right lateral incisor to right maxillary tuberosity area.

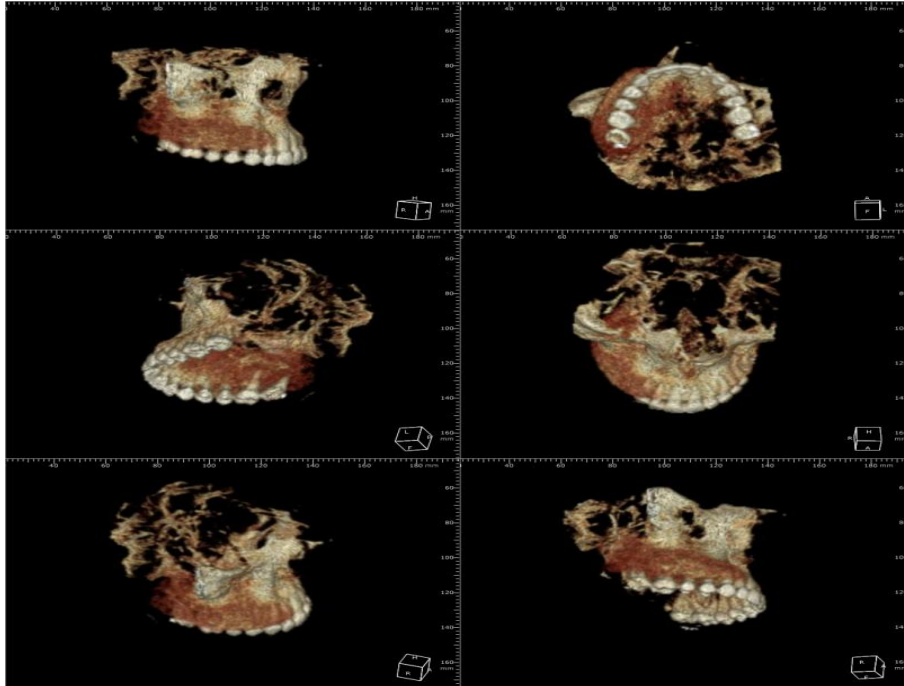
The radiographic x -ray showed ground glass area in upper right teeth-bearing alveolar bone with ill demarcated margin. Seen on panoramic x ray and cone beam CT scan (Fig. 2,3 and 4).



**Figure 2.** Panoramic radiograph represents a ground glass appearance in right maxillary quadrant with ill demarcated margin.

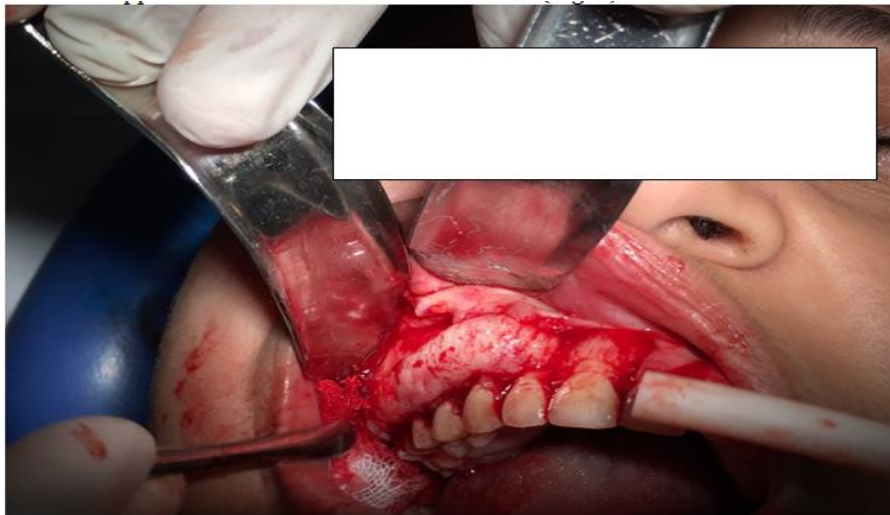

**Figure 3.** Cone beam CT scan revealed a radioopacity in upper right teeth-bearing alveolar bone.



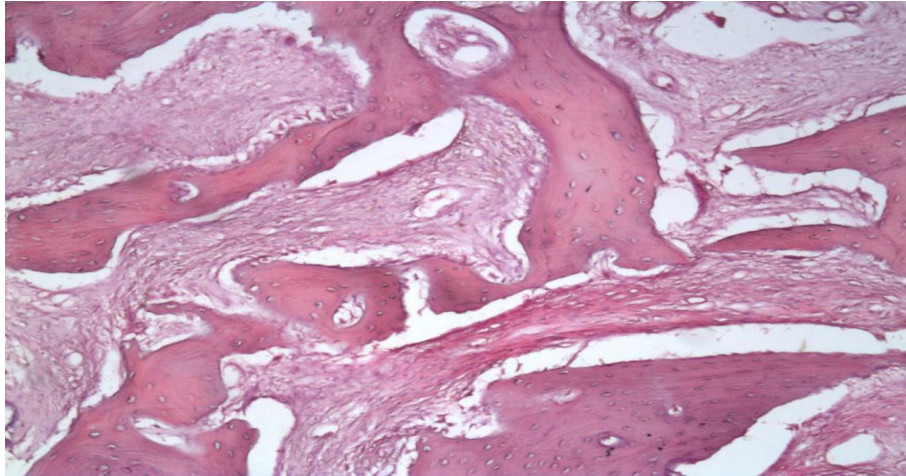
**Figure 4.** The reconstructed CBCT image gives a sense of the three dimensional shape of the lesion.

Based on clinical and radiographic findings, differential diagnosis for the bony hard swelling considered of ossifying fibroma, pagets disease, focal cementosseous dysplasia and osteoma. Incisional biopsy was done and a vestibular approach was used to remove the lesion (Fig. 5).



**Figure 5.** Incisional biopsy was done and a vestibular approach was used to remove the lesion.

Histopathological examination of H&E stained sections revealed an interconnecting trabeculae of woven bone showing Chinese letter appearance. No osteoblastic rimming was detected. The bone trabeculae were embedded in a fibroblastic stroma (Fig. 6). The mere existence of this lesion in the craniofacial area is not an justification for treatment. so for this patient, treatment was delayed, however she is under regular follow up.



**Figure 6.** Haematoxylin- and eosin-stained slide showing interconnecting trabeculae of woven bone in a fibroblastic stroma. There is a lack of osteoblastic rimming surrounding the bony trabeculae.

### III. Discussion

Fibrous dysplasia (FD) is a benign bone disease characterized by replacement of the normal bone by fibro-osseous connective tissue demonstrating varying degrees of osseous metaplasia. It is a developmental condition of the bone-forming mesenchyme in which fibrous tissue expands and replaces the bone. (Ozek et al., 2002).

Fibrous dysplasia is a sporadic condition, resulting from a post-zygotic mutation on gene *GNAS 1* (guanine nucleotide-linked protein, Alpha stimulating activity of polypeptide), coding for the subunit of signal transduction G – (GS-a) resulting in increased production of c-AMP affecting the proliferation and differentiation of preosteoblasts (ALONSO et al., 2014).

The clinical appearance of the condition depends on the time of fetal life or of postnatal life in which the mutation of the *GNAS 1* happens. So when the mutation occurs during the embryonic life, the result will be multiple bone lesions of fibrous dysplasia, and also skin and endocrine abnormalities. However, if the mutation happens during postnatal life period, the progeny of the modified cells will be essentially confined to one location, leading to fibrous dysplasia that affects a single bone (Uppala et al., 2015).

The disease has mainly two major forms; monostotic form affecting single bone whereas polyostotic form affecting multiple bone. The most affected bones are; femur, tibia, ribs and facial bones. It accounts for about 7.5% of the benign bone neoplasms. The facial and cranial bones involvement occurs in approximately 50% of patients with the polyostotic form and in 10-27% of patients with monostotic form. A special form of FD is McCune-Albright syndrome, which is characterized by endocrine dysfunction including acromegaly, Cushing syndrome, hyperthyroidism (Menon et al., 2013).

The plain radiological features of FD are non-specific and vary widely. The typical appearance is a homogenous ground-glass appearance and ill-defined borders. Occasionally, the radiograph may reveal predominantly sclerotic lesions with or without accompanying lytic lesions (Fitzpatrick et al., 2004).

Surgical Treatment usually involves osseous shaving at the affected site to improve esthetics and function, after the active growth cessation. This depends on the presence and severity of the symptoms, location and the patient's age (Sachdeva, 2015).

Microscopically the stromal fibroblastic element is proliferative and hypercellular. As the disease progresses, trabeculae thickens and assumes the classic “Chinese letter” appearance, the osseous collagen pattern remains woven. The fibrous element continues to be hypercellular. Later, woven bone is replaced by lamellar bone trabeculae; extensive remodeling may lead to a mosaic pattern of resting and reversal lines (Eversole et al., 2008).

### IV. Conclusion

Fibrous dysplasia is a disease characterized by replacement of normal bone by an increased proliferation of fibrous connective tissue cell with irregular bone trabeculae. It can affect single bone (monostotic) or multiple bones (polyostotic). It is usually seen in young adults and comprises 7% of benign bone tumors. The etiology is not obvious but genetic predisposition is suspected. It has a predilection for long bones and the craniofacial bones. The most commonly affected facial bone is the maxilla with a facial asymmetry. There are many treatment approaches including monitoring or surgery. Diagnosis of fibrous dysplasia is based on clinical examination, radiographic and histopathological findings. The microscopic

features are those of a hypercellular and cytologically uniform fibrous stroma within which delicate and irregular trabeculae of woven bone. These trabeculae resemble Chinese letters configuration.

### References

- [1]. Agarwal, M., Balaji, N., Mk, S., Jd, S., Dawar, G., & Rallan, N. S. (2014). FIBROUS DYSPLASIA : A REVIEW, 1(1), 25–29.
- [2]. ALONSO, N., MATUSHITA, H., & ALESSI, M. S. (2014). Surgical approach to the treatment of craniofacial fibrous dysplasia - A 14 -year experiencedysplasia- 14 years experience. *Revista Brasileira de Cirurgia Plástica (RBCP) – Brazilian Journal of Plastic Surgery*, 29(1), 66–70. <https://doi.org/10.5935/2177-1235.2014RBCP0010>
- [3]. Bertoni, F., Arias, L. F., Alberghini, M., & Bacchini, P. (2004). Fibrous dysplasia with degenerative atypia: A benign lesion potentially mistaken for sarcoma. *Archives of Pathology and Laboratory Medicine*, 128(7), 794–796.
- [4]. Eversole, R., Su, L., & ElMofly, S. (2008). Benign fibro-osseous lesions of the craniofacial complex a review. *Head and Neck Pathology*, 2(3), 177–202. <https://doi.org/10.1007/s12105-008-0057-2>
- [5]. Fitzpatrick, K. A., Taljanovic, M. S., Speer, D. P., Graham, A. R., Jacobson, J. A., Barnes, G. R., & Hunter, T. B. (2004). Imaging findings of fibrous dysplasia with histopathologic and intraoperative correlation. *American Journal of Roentgenology*, 182(6), 1389–1398. <https://doi.org/10.2214/ajr.182.6.1821389>
- [6]. Guruprasad, Y., & Chauhan, D. (2012). Craniofacial fibrous dysplasia - A review of current management techniques. *Chronicles of Young Scientists*, 3(2), 106. <https://doi.org/10.4103/2229-5186.98672>
- [7]. Menon, S., Venkatswamy, S., Ramu, V., Banu, K., Ehtaih, S., & Kashyap, V. M. (2013). Craniofacial fibrous dysplasia: Surgery and literature review. *Annals of Maxillofacial Surgery*, 3(1), 66–71. <https://doi.org/10.4103/2231-0746.110088>
- [8]. Ozek, C., Gundogan, H., Bilkay, U., Tokat, C., Gurler, T., & Songur, E. (n.d.). Clinical Notes.
- [9]. Sachdeva, S. K. (2015). Craniofacial Fibrous Dysplasia in an Elderly Patient: A Case Report with a Review of Literature. *Acta Stomatologica Croatica*, 49(1), 60–64. <https://doi.org/10.15644/asc49/1/8>
- [10]. Uppala, D. (n.d.). Monostotic Fibrous Dysplasia of the Thoracic Spine.Pdf, 628–631.
- [11]. Zanetti, D., & Gamba, P. (2007). Cholesteatoma and fibrous dysplasia of the temporal bone: Case report and review of the literature. *Journal of Otolaryngology*, 36(1), 2002–2005. <https://doi.org/10.2310/7070.2005.5015>
- [12]. Zenn, M. R., & Zuniga, J. (2001). Treatment of fibrous dysplasia of the mandible with radical excision and immediate reconstruction: case report. *The Journal of Craniofacial Surgery*, 12(3), 259–263.