

Immediate Implant Placement in to Fresh Extraction Socket: A 3 Year Follow Up.

Dinesh M. Chavan¹, Roshani D. Chavan².

Abstract: The replacement of a single tooth is a common procedure performed in contemporary implant dentistry. Placement of implant immediately following tooth extraction provides several advantages to the patient compared with a staged approach. This case presentation illustrates a case of an extraction and immediate implant placement in the maxillary second premolar region.

Keywords: Immediate implant, Implant

I. Introduction

In the initial days of implant dentistry, a two-stage surgery was believed mandatory to provide a submerged, stress-free healing period for the implants to osseointegrate.^{1,2} In cases of tooth extraction, complete healing of the alveolar bone was required before placing an implant, according to Brånemark's original principles.² This process required 6 to 12 months, and during this period, a considerable amount of bone can be lost as a result of bone resorption.³

In the past decades, implant dentistry has undergone a series of advances that allowed to modify the original protocol. Immediate placement of implants in fresh extraction sockets has been demonstrated also to be a successful procedure that helps in preventing bone resorption.⁴ W Schulte first reported placement of a Tubingen dental implant into a fresh extraction socket.⁵ Grafting procedures have been proposed as a means to enhance bone formation around implants placed in fresh extraction sockets with good results.⁶ Graftless procedures have also resulted in good outcomes in the anterior and premolar areas.³ The advantages of immediate implants are that Immediate implants prevent undue resorption bound to happen post extraction⁷ and allows for maintenance of gingival form and facilitates periimplant gingival tissue esthetics by maintaining the interdental papilla.

II. Case Description

51-year-old male patient presented for routine checkup. Health history of the patient was relatively sound. Intraoral examination of the patient revealed presence of root piece with maxillary right second premolar (FIG. 1). Clinical and radiological evaluation revealed adequate alveolar bone, absence of periapical pathology but fracture line was below the crest of alveolar bone and was limited to the tooth (FIG. 2). So it was decided to extract the root piece and place implant immediately and place provisional restoration to avail the benefits like preservation of bone and emergence profile. Therefore, with the patients consent treatment planned for the patient included, extraction of the root piece and placement of immediate implants.

After administering appropriate antibiotic and analgesic, induction of local anesthesia was carried followed by placing sulcular incisions around the premolar. As preservation of alveolar bone is key to success of immediate implants, extraction of tooth has to be atraumatic, so by using periostomes periodontal ligament fibers are dissected and by using small periosteal elevators, the fragment was luxated without excessive enlargement of the socket and root piece was extracted (FIG. 3,4,5). Following root piece extraction the extraction socket is thoroughly curetted and irrigated to remove any remnant tooth fragments and after extraction of the teeth, sockets were examined for any fracture of the walls of the socket. An implant was planned with dimensions 5 × 13mm. Primary stability was achieved by wrenching the implant into the bone beyond the apex of the socket. The cover screw was placed and interrupted sutures were placed. Postoperative radiographs were taken (FIG. 6). Postoperative instruction and medication were given. Amoxicillin (Augmentin 675mg thrice a day) was prescribed for 5 days. Sutures were removed after 8 days and the patient received temporary acrylic crown bonded to the adjacent teeth with fiber-reinforced composite on the same day.

After the initial healing phase of 4 months, Stage 2 procedure of uncovering the implant was undertaken. Healing abutment (gingiva former) was screwed in. 2 weeks later, healthy gingival collar was evident and abutment was screwed (FIG. 7). Impressions were made with the open tray technique using rubber based impression material. Cement retained final porcelain fused to metal (PFM) prosthesis was placed (FIG. 8). Patient was put on the maintenance schedule of 4 months interval and was followed upto 3 years with clinical and radiographic evaluation. The clinical and radiographic appearances at 3 years show good esthetics, osseointegration and maintenance of bone around the implant with a stable perimplant crestal bone on the site.

III. Conclusion

The success of the implant lies in the primary stability as achieved when implant is placed 2-3 mm apical to the socket. The overall reduced treatment time and surgical visits makes immediate implants a treatment of choice over the conventional approach of tooth extraction and waiting upto 4-6 months. The use of grafting materials when used, provide a conducive environment for soft tissue closure in the fresh extraction socket, thus fulfilling both functional and esthetic requirements of replacement of missing teeth. There was good esthetic without gingival recession These results are due to the selection of only type I extraction sites, which have a thick periodontal biotype according to the pre-operative classification proposed by Salama and Salama.⁸

References

- [1]. Brånemark PI, Hansson BO, Adell R, et al. Osseointegrated implants in the treatment of the edentulous jaw. Experience from a 10-year period. *Scand J Plast Reconstr Surg Suppl* 1977;16:1-132.
- [2]. Adell R, Lekholm U, Rockler B, Brånemark PI. A 15-year study of osseointegrated implants in the treatment of the edentulous jaw. *Int J Oral Surg* 1981;10:387-416.
- [3]. Paolantonio M, Dolci M, Scarano A, et al. Immediate implantation in fresh extraction sockets. A controlled clinical and histological study in man. *J Periodontol* 2001;72:1560-1571.
- [4]. Schropp L, Kostopoulos L, Wenzel A. Bone healing following immediate versus delayed placement of titanium implants into extraction sockets: A prospective clinical study. *Int J Oral Maxillofac Implants* 2003;18:189-199.
- [5]. Schulte W. The intraosseous Al2O3 (Frialit) Tuebingen implant. Developmental status after eight years (II). *Quintessence Int* 1984;15:19-35.
- [6]. Fugazzotto PA. Implant placement at the time of maxillary molar extraction: Technique and report of preliminary results of 83 sites. *J Periodontol* 2006;77:302-309.
- [7]. Lazzara RM. Immediate implant placement into extraction sites. Surgical and restorative advantages. *Int J Periodontics Restorative Dent* 1989;9:333-343.
- [8]. Salama H, Salama M. The role of orthodontic extrusive remodeling in the enhancement of soft and hard tissue profiles prior to implant placement: A systematic approach to the management of extraction site defects. *Int J Periodontics Restorative Dent* 1993;13:313-33.

Figure Legends

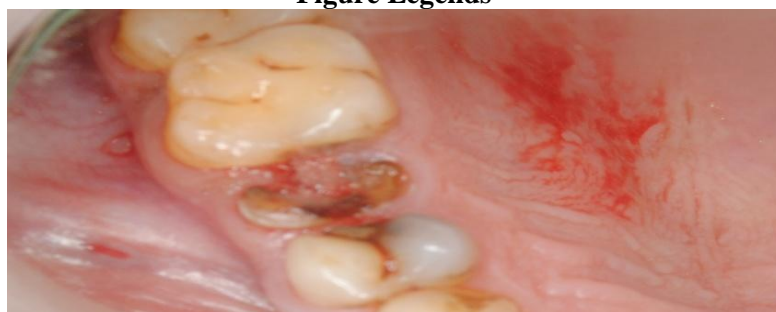

Figure 1 Fractured maxillary second premolar.

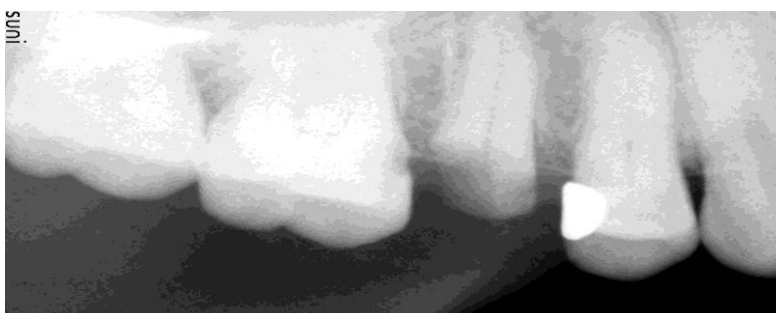

Figure 2 Adequate alveolar bone around root piece.

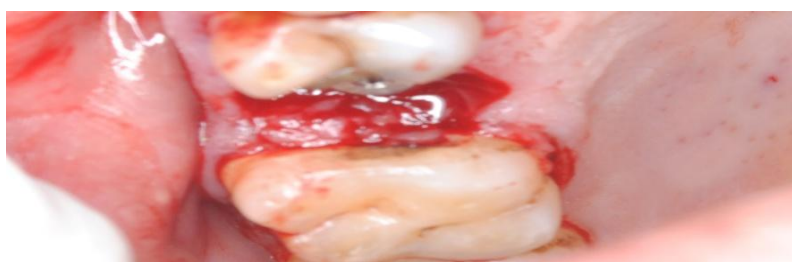


Figure 3 Extracted socket.

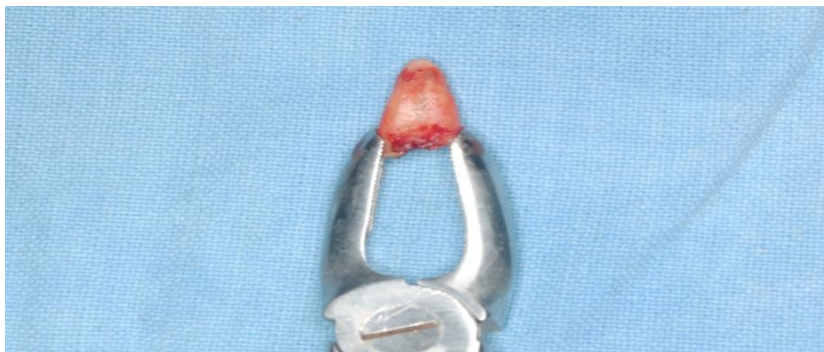


Figure 4 Extracted intact root piece.

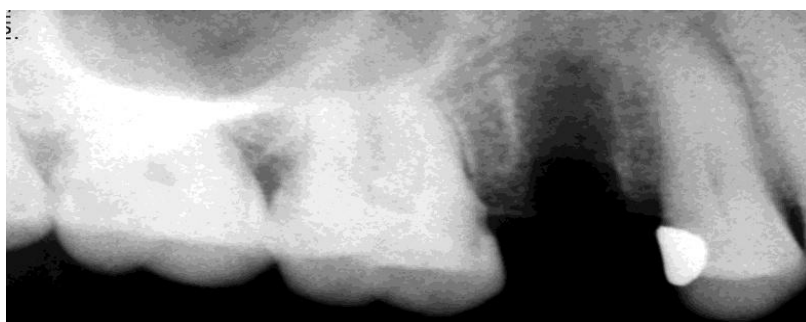

Figure 5 Extracted socket without any fracture line.

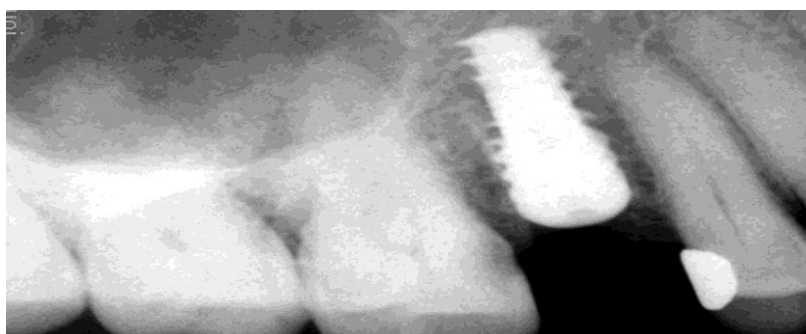


Figure 6 Implant placed 3 mm apically in extracted socket

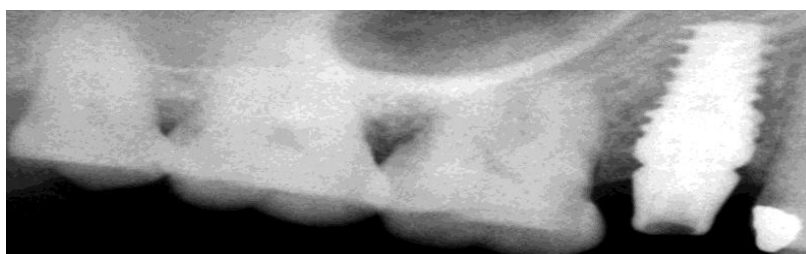


Figure 7 Abutment placed over implant.

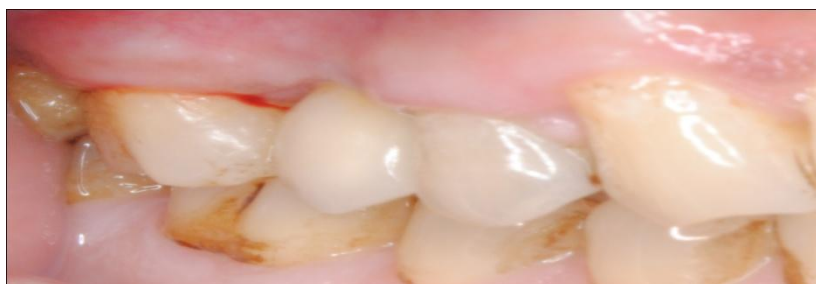

Figure 8 Final prosthesis at the end of 3 years.