

## Little Old Lady's Hernia: A Rare Cause of Intestinal Obstruction

Sumita A. Jain<sup>1</sup>, Mohit kumar Badgurjar<sup>2</sup>, Laxman Agarwal<sup>3</sup>, Deshraj Chawla<sup>4</sup>,  
R.G.Khandelwal<sup>5</sup>, Rajnish Meena<sup>6</sup>, Rajeev Kumar<sup>7</sup>, Kaknale Harish<sup>8</sup>, Bharathi  
Mohan<sup>9</sup>

<sup>1,2,3,4,5,6,7,8,9</sup>(General Surgery, Sawai Man Singh Medical college & Hospital, India)

**Abstract :** Obturator hernia is a rare type of pelvic hernia which generally occurs in elderly patients with accompanying diseases. Because it is difficult to diagnose before surgery, the morbidity and mortality rates are high. The most common clinical presentation is intestinal obstruction with or without features of strangulation. We operated a case of 60 year old, multiparous, female patient admitted in the emergency with 5 days history of abdominal pain, abdominal distension, nausea, vomiting, constipation & inability to pass flatus. On examination abdomen was distended but soft with few visible loops and increased peristaltic bowel sounds. Her lab investigation were normal. X-ray FPA upright revealed multiple gas fluid levels. Her CT showed a small bowel loop herniating through obturator foramen and proximal small bowel dilatation. On operation a small bowel loop was found to be herniated through obturator foramen and on reduction of hernia the herniated loop was found to be gangrenous. So, resection anastomosis was done and obturator foramen was closed with primary sutures. Post operative period was uneventful. In conclusion obturator hernia must be considered in the differential diagnosis of thin elderly patients, especially females admitted with symptoms of intestinal obstruction and immediate CT must be done to prevent gangrenous changes.

**Keywords:** C.T. scan, intestinal obstruction, obturator hernia, pelvic hernia, strangulation

### I. Introduction

Obturator hernia is a type of pelvic hernia in which a bowel segment protrudes through the obturator foramen adjacent to the obturator vessels and nerve. It occurs more frequently in patients with ascites, chronic constipation, and chronic obstructive pulmonary disease and in thin, elderly multiparous women [1]. The most common clinical symptom is strangulation combined with mechanical intestinal obstruction. Because the symptoms are nonspecific, obturator hernia is difficult to diagnose, and most patients are diagnosed during surgery. Obturator hernias occur frequently in elderly patients with accompanying diseases, and therefore the morbidity and mortality rates are high [2]. Currently, diagnostic imaging, especially computed tomography, is widely used to diagnose obturator hernias before surgery in the early stages of the disease [3]. *The aim of this case report was to present the fact that obturator hernia can be diagnosed preoperatively if CT scan is done without wasting time so that one can prevent gangrenous changes in the herniated loop.* Though in our case there was a delay of 10 hours due to CT reporting problem as Radiologist consultants are not available at night.

### II. Case Report

A 60-year-old female patient weighing 43 kg & BMI 17.2 presented to the ER with a five-day history of abdominal pain, abdominal distension, nausea, vomiting, constipation, and inability to pass gas. Her physical examination revealed abdominal distention with increased bowel sounds. External hernial sites were normal. Her lab tests were normal except HB was 7.9 gm/dl. X ray FPA upright revealed dilated small bowel loops along with multiple gas fluid levels. CT results showed a small intestine loop herniating through the obturator foramen and dilatation in the proximal small bowel (Figure 1). Howship-Romberg sign was absent. A preop diagnosis of obturator hernia was established. During surgery, a strangulated small intestinal segment extending through the right obturator foramen was detected which was gangrenous (Figure 2). After reduction of herniated gangrenous bowel loop, resection anastomosis was done. Hernial sac identified and removed after identifying obturator nerve & vessels. The obturator foramen (Figure 3) was closed with primary sutures and the postoperative period was uneventful and the patient got discharged on POD 7.

### III. Discussion

Obturator hernia was first described by Arnaud de Ronsil in 1724 and was successfully treated for the first time by Henry Obre in 1851 [4, 5]. Obturator hernia protrudes through the circle surrounded by the superior ramus of the pelvic bone in the front, the obturator membrane and the internal and external obturator muscles on the inferior side, and the obturator vessels and the nerves on the posterolateral aspects. Obturator hernias account for 0.05–0.4% of all abdominal hernias [6]. It is often referred to as “little old lady’s hernia” [5]. Due to its nonspecific symptoms, obturator hernia is difficult to diagnose. The preoperative diagnosis rate is reported as

only 10–30% [2]. More than 90% of patients with obturator hernia are admitted to the hospital with acute intestinal obstruction, presenting with abdominal pain, nausea, and vomiting [7]. The Howship-Romberg sign ie pain along the medial aspect of the thigh radiating to the knee due to compression of the anterior branch of the obturator nerve by the contents of the hernia is present in 50% of patients [8, 9]. However, the sign is commonly mistaken for neuromuscular pain, as joint pain is common in elderly patients and is overlooked. Another clinical sign of obturator hernia is the Hannington-Kiff sign, in which the adductor reflex is absent in the thigh. Clinically diagnosing obturator hernia is difficult because the symptoms are nonspecific. A reliable preoperative diagnosis can be made by preop computed tomography which has high sensitivity and specificity [3].

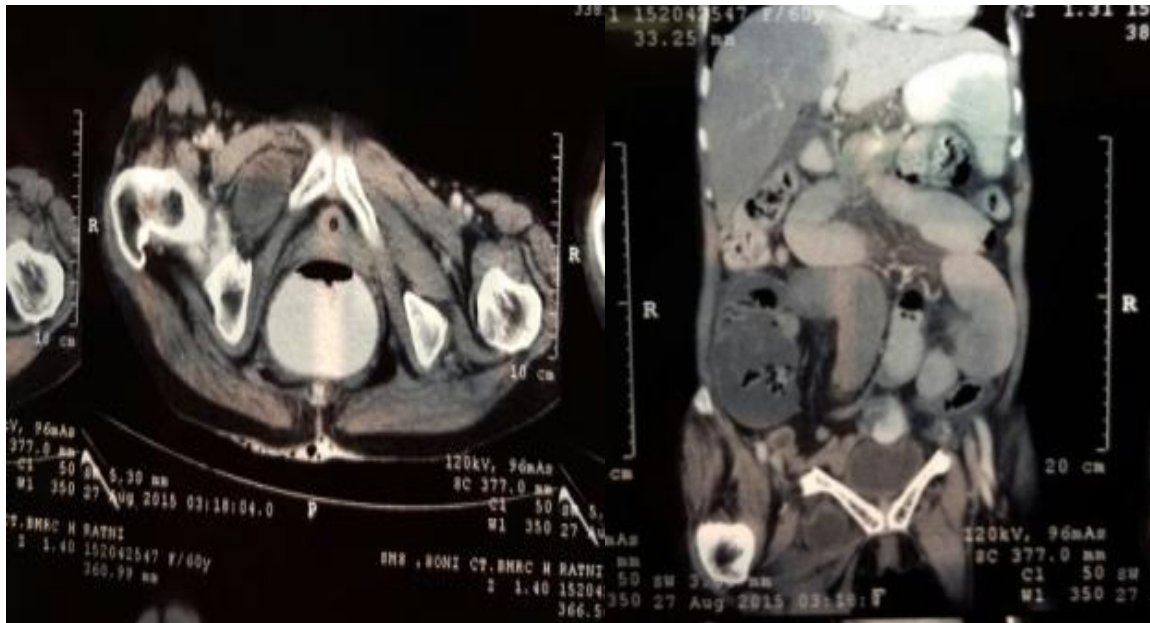


Figure 1: Computed tomography image showing a herniated bowel loop(arrow) in the obturator foramen on the Right

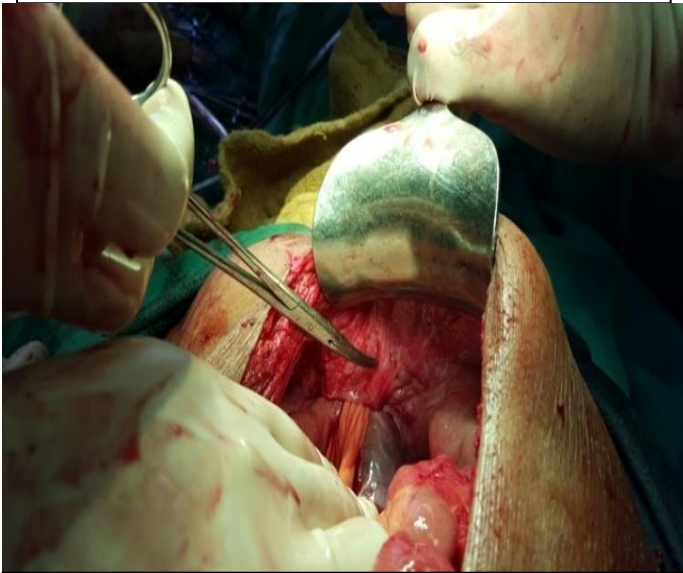


Figure 2: Strangulated small intestinal segment extending through the right obturator foramen

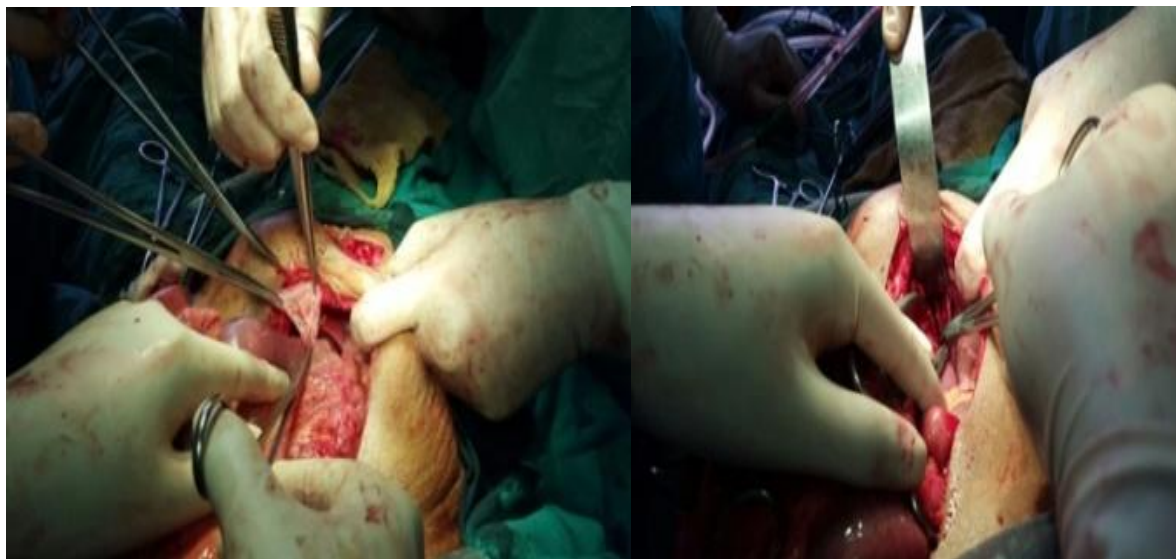


Figure 3: Showing hernia sac through the obturator canal and Showing obturator canal

#### **IV. Conclusion**

Obturator hernia must be kept in mind specially in thin, elderly females and CT scan should be advised as early as possible to reach to the diagnosis so that timely intervention can be done before development of gangrene. There by preventing mortality and morbidity.

#### **References**

- [1]. D. W. Ziegler and J. E. Rhoads Jr., "Obturator hernia needs a laparotomy, not a diagnosis," *American Journal of Surgery*, vol. 170, no. 1, pp. 67–68, 1995.
- [2]. S. W. Gray, J. E. Skandalakis, R. E. Soria, and J. S. Rowe Jr., "Strangulated obturator hernia," *Surgery*, vol. 75, no. 1, pp. 20–27, (1974).
- [3]. R. Ijiri, H. Kanamaru, H. Yokoyama, M. Shirakawa, H. Hashimoto, and G. Yoshino, "Obturator hernia: the usefulness of computed tomography in diagnosis," *Surgery*, vol. 119, no. 2, pp. 137–140 (1996)
- [4]. C. H. Hsu, C. C. Wang, L. B. Jeng, and M. F. Chen, "Obturator hernia," *Surgery, Gynecology & Obstetrics*, vol. 167, no. 3, pp. 217–222 (1988)
- [5]. S. K. Dundamadappa, I. Y. Y. Tsou, and J. S. K. Goh, *Clinics* no. 1, pp. 89–94 (2006)
- [6]. S. S. Chang, Y. S. Shan, Y. J. Lin, Y. S. Tai, and P. W. Lin, "A review of obturator hernia and a proposed algorithm for its diagnosis and treatment," *World Journal of Surgery*, vol. 29, no. 4, pp. 450–454, 2005.
- [7]. C. Y. Lo, T. G. Lorentz, and P. W. K. Lau, "Obturator hernia presenting as small bowel obstruction," *American Journal of Surgery*, vol. 167, no. 4, pp. 396–398, 1994.
- [8]. M. Kammori, K. I. Mafune, T. Hirashima et al., "Forty-three cases of obturator hernia," *American Journal of Surgery*, vol. 187, no. 4, pp. 549–552, 2004.
- [9]. R. A. Sorabella, D. N. Miniati, and M. L. Brandt, "Laparoscopic obturator hernia repair in an adolescent," *Journal of Pediatric Surgery*, vol. 40, no. 12, pp. E39–E41, 2005.