

## Vacterl Association in A Newborn – A Rare Case Report

Dr Ashok<sup>1</sup>, Dr Reddy K.V<sup>2</sup>, Dr Soren.C<sup>3</sup>

Junior Resident<sup>1</sup>, Assistant Professor<sup>2</sup>, Professor & Head<sup>3</sup>

Department Of Pediatrics, Sri Venkata Sai Medical College & Hospital, Mahaboobnagar, India.

**Abstract:** Vacterl association is sporadic non-random co-occurrence of various congenital malformations in a single patient due to defect in structures derived from embryonic mesoderm. Here, we report a newborn baby who had most of the defects described in VACTERL association.

**Keywords:** VACTERL, Hemi-vertebrae, single umbilical artery.

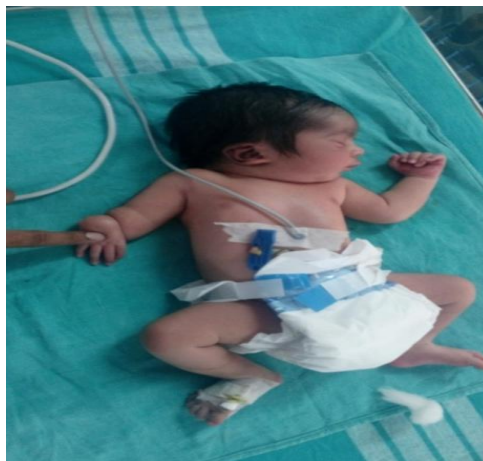### I. Introduction

Vacterl is a useful acronym for a condition characterised by the sporadic, non-random association of various congenital malformations in a single patient. The acronym Vacterl denotes vertebral defects or vascular anomalies, anal atresia, cardiac abnormalities, trachea-esophageal fistula, renal abnormalities and limb anomalies. The incidence is estimated between 1 in 10,000 to 1 in 40,000 live-born infants<sup>[1]</sup>. In this report, we describe a newborn that was born with most of the defects described in Vacterl association.

### II. Case report

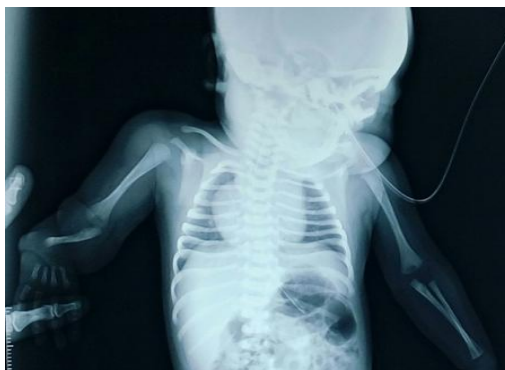A male baby was born at 38 weeks of gestational age through elective lower segment cesarean section to a 30 years old, non-consanguineously married, fourth gravida mother. The baby had apgar score of 8 and 10 at 1 minute and 5 minutes, respectively. First two siblings (both females) were delivered through lower segment cesarean section and are doing well. There was no history of birth defect in family. Mother had regular antenatal check-ups. She received 2 doses of tetanus toxoid and took iron and folic acid tablets. There was no significant history of any infection, drug intake, diabetes mellitus, or radiation exposure during the pregnancy. Mother didn't undergo any antenatal scan.

The birth weight was 2.67kgs with length 48cm and head circumference of 35cm. Baby was active and had normal neonatal reflexes. Clinical examination revealed single umbilical artery, scoliosis towards right side, and absence of radius and thumb on right hand [Figure 1]. Oral and anal orifices are patent.

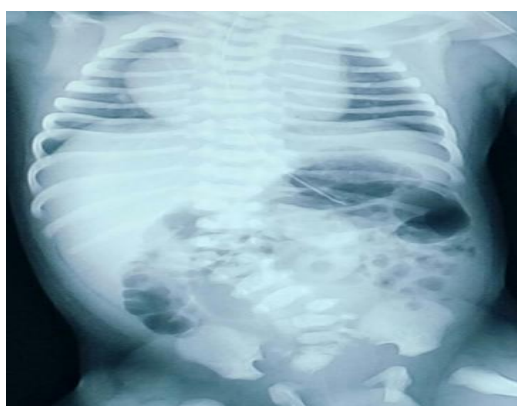


**Figure 1:** Baby showing absence of radius and right thumb

Infantogram of the baby showed hemi-vertebrae, right side scoliosis, and absent of radius and thumb on right side [Figure 2 and 3]. Ultrasonogram of abdomen revealed absence of left kidney. Echocardiogram showed small ventricular septal defect (<5mm). Complete blood picture including platelet count, serum creatinine and serum electrolytes were within normal limits on day 1, 3, 7, and 14. Due to simultaneous occurrence of congenital anomalies including hemivertebrae, single umbilical artery, small ventricular septal defect, left renal agenesis, and absent right radius and right thumb, this baby was diagnosed as a case of VACTERL association.



**Figure 2:** Infantogram showing absence of radius bone (right side)



**Figure 3:** X-ray showing hemivertebrae

### III. Discussion

The acronym VACTERL association describes non-random co-occurrence of birth defect of structures derived from embryonic mesoderm. The VACTERL association is clinically defined by presence of at least 3 of the following congenital malformations: vertebral defects or vascular anomalies (V), anal atresia (A), cardiac abnormalities (C), trachea-esophageal fistula (TE), renal abnormalities (R), and limb anomalies (L)<sup>[2]</sup>. VATER association (without cardiac anomalies) was first described in 1973 by Quan and Smith<sup>[3]</sup>. In 1974, Temtamy and Miller included ventricular septal defect and single umbilical artery<sup>[4]</sup>.

The exact incidence of this association is not known, with the available literature the estimated incidence ranges from 1 in 10,000 to 1 in 40,000 live-born infants. The etiology is not known, but it is believed that multiple genetic and environmental factors may play a part in determining the risk of developing this condition. A disruption in differentiating mesoderm in the first 4–5 weeks may lead to the different malformations of the VACTERL spectrum, including the presence of a single umbilical artery. Mutations in sonic hedgehog pathway genes have been implicated in some cases of VACTERL association.<sup>[5,6]</sup>

Vertebral anomalies are reported in approximately 60 to 80% patients and are often associated with rib anomalies. The vertebral anomalies typically include segmentation defects, such as hemivertebrae, butterfly vertebrae, wedge vertebrae, and vertebral fusions, supernumerary or absent vertebrae and other forms of vertebral dysplasia. Anal atresia or imperforate anus occurs in 50-80% of patients. Cardiac defects are reported in approximately 40-80% patients and common defects include ventricular septal defect, atrial septal defect and tetralogy of Fallot. Tracheo-esophageal anomalies occur in approximately 50-70% of patients. Pulmonary anomalies may co-occur with trachea-esophageal fistula. Renal anomalies are reported in approximately 50-80% patients and include agenesis or aplasia of one or both kidney, horseshoe kidney, and cystic and/or dysplastic kidneys. Sometimes, renal anomalies are associated with ureteral and genitourinary anomalies. Limb anomalies are reported in approximately 40-55% patients and include absent radius, polydactyl and syndactyl<sup>[7]</sup>. About 20-30% of the patients with VACTERL association have a single umbilical artery. In addition to above features, patients may also have other congenital malformations.

The differential diagnoses of VACTERL association includes a wide variety of syndromes, among which are Townes-Brocks syndrome, Fanconi anemia, 22q11.2 deletion syndrome, CHARGE syndrome, TAR syndrome (thrombocytopenia, absent radius), and Pallister-Hall syndrome<sup>[8]</sup>.

Antenatal diagnosis of VACTERL association is challenging, as both skill and experience is needed to interpret scans performed. If suspected in prenatal ultrasonography, MRI scan as well as prenatal echocardiography may help in making the diagnosis.

The management of VACTERL association includes: 1) surgical correction of congenital malformations that are incompatible for life, such as severe cardiac malformations, imperforate anus, and trachea-esophageal fistula; and 2) long-term medical management of the congenital malformations, e.g. renal anomalies and vertebral anomalies<sup>[8]</sup>.

Overall prognosis depends on type and severity of anomalies present. Early detection of the condition as well as early surgical intervention and rehabilitation are necessary to improve the outcome. If detected in-utero viability, termination of pregnancy can be offered.

#### **IV. Conclusion**

Vacterl association is a condition characterised by non-random association of specific birth defects involving multiple organ system. Diagnosis is clinical and based on presence of defect in at least 3 organ systems as described previously. Prenatal diagnosis, early surgical intervention, proper medical management and rehabilitation are needed to improve the outcome.

**Conflict of interest:** None stated

**Funding:** None

**Ethical approval:** Approved by institutional ethics committee of the institute.

#### **References**

- [1]. Padma S, Sundaram PS, Sonik B. A case of VACTERL and non-VACTERL association without the "V and L". *Indian J Nucl Med.* 2014 Jan; 29(1):46-9. doi: 10.4103/0972-3919.125776.
- [2]. Sandal G, Aslan N, Duman L, Ormeci AR. VACTERL association with a rare vertebral anomaly (butterfly vertebra) in a case of monozygotic twin. *Genet Couns.* 2014;25(2):231-5.
- [3]. La Placa S, Giuffrè M, Gangemi A, Di Noto S, Matina F, Nociforo F, et al. Esophageal atresia in newborns: a wide spectrum from the isolated forms to a full VACTERL phenotype? *Ital J Pediatr.* 2013 Jul 10; 39:45. doi: 10.1186/1824-7288-39-45.
- [4]. Bartels E, Jenetzky E, Solomon BD, Ludwig M, Schmiedeke E, Grasshoff-Derr S, et al. Inheritance of the VATER/VACTERL association. *Pediatr Surg Int.* 2012 Jul; 28(7):681-5. doi: 10.1007/s00383-012-3100-z. Epub 2012 May 12
- [5]. Girish Gopal, Gangadhar. B. Belavadi. VACTERL association in the newborn. *Indian J. Pharm. Biol. Res.* 2014; 2(2):96-99.
- [6]. Santos J, Nogueira R, Pinto R, Cerveira I, Pereira S. First Trimester Diagnosis of VACTERL Association. *Clin Pract.* 2013 Feb 5; 3(1):e5. doi: 10.4081/cp.2013.e5. eCollection 2013.
- [7]. Solomon BD, Baker LA, Bear KA, Cunningham BK, Giampietro PF, Hadigan C et al. An approach to the identification of anomalies and etiologies in neonates with identified or suspected VACTERL (vertebral defects, anal atresia, tracheo-esophageal fistula with esophageal atresia, cardiac anomalies, renal anomalies, and limb anomalies) association. *J Pediatr.* 2014 Mar; 164(3):451-7.e1.
- [8]. Solomon BD. VACTERL/VATER Association. *Orphanet J Rare Dis.* 2011 Aug 16; 6:56. doi: 10.1186/1750-1172-6-56