

Mri Evaluation of The Pattern of Involvement in Caries Spine With Clinical Correlation

*Dr Shyam Lal Agarwal, Dr Mrinalkanti Ghosh, Dr Adrija Mandal

1HOD , Professor , Dept of Radiodiagnosis, Burdwan
Medical College, Purba Bardhaman

2Associate Professor , Dept of Radiodiagnosis, Burdwan
Medical College, Purba Bardhaman

3Resident , Dept of Radiodiagnosis, Burdwan Medical
College, Purba Bardhaman

*Correspondence Author: Dr Shyam Lal Agarwa

Abstract

Background /Purpose: Tuberculosis is well known infectious disease .Skeletal Tuberculosis accounts for 10 to 35% of cases of extraskelatal Tuberculosis. Among all modalities MRI has remarkable ability to detect cardinal features of tubercular spondylodiskitis .

Aims and objectives : This study was conducted with the aims towards patients with red flag signs of caries spine so they can be scrutinized on MRI to evaluate radiological signs of this disease, those guide imaging diagnosis as well as differentiating them from similar pathologies.

Materials and methods: 50 sequential adult populations of 15-75 years of age presenting with red flag signs of caries spine were studied over one and half year from February 2016 to August 2017 , after getting appropriate clearance from ethical committee .

Result and Analysis: Clinically most of the patients were presented with low back pain. Thoracolumbar regions was most common site of involvement . MRI with its superior soft tissue resolution and 3D reconstructive ability was found to be superior in nearly every aspect of lesion detection. Cord change was noted in significant number of patients.

Conclusion: MRI assessment helped to assess characteristics of caries spine . It provides well correlation with clinically suspected cases ,thus provide earlier detection and treatment. MRI which is extremely accurate and reliable can be utilized for patients requiring advanced workup and follow up. Overall through this study and through the comparison made from the inferences of previous studies it could be safely concluded that MRI is the best modality to evaluate spinal Tuberculosis.

Keywords : MRI , caries spine , pattern analysis.

Date of Submission: 04-12-2017

Date of acceptance: 03-01-2018

I. Introduction

Infections of spine by tuberculosis is common in developing ,even in developed countries.. Spinal tuberculosis is chiefly a form of extra pulmonary tuberculosis and it is mostly manifested in its secondary form. In a developing country like India, where access to health care institutions is still largely not achievable for the underprivileged sections of the population, coupled along with the tropical conditions of the climate which favor the growth and propagation of the tuberculous bacilli and the general poor awareness among the people, the spread and the prevalence of tuberculous infection of the spine is very serious health hazard. Prevalence of spinal tuberculosis has assumed new pathological dimensions with the increased prevalence of HIV, it being one of the principle causes of suppression of the immune system making the patient susceptible to Tuberculosis.

History of spinal tuberculosis goes a long way back in history , where evidence of spinal Tuberculosis has been documented in the mummies of Egypt , recently being the mummy of Tutankhamen in 133BC [1]. A detailed and scientific approach to the tuberculosis infection of spine began in the 19th century by Sir Percival Pott (British surgeon) in 1779. Tubercular involvement of the spine has the potential to cause serious morbidity, including permanent neurologic deficits and ultimately severe deformities. Combined medical and surgical strategies can control the disease in most patients. Tuberculosis (TB) is one of the top 10 causes of death worldwide. WHO declared Tuberculosis as global public health emergency in 1993[2-5].

According to WHO 9.4 million new cases of Tuberculosis occurred worldwide in 2009, 95% of them in developing countries of Asia (5.2 million), Africa (2.8 million), the Middle East (0.7 million), and Latin America (0.3 million) [6]. In 2015, 10.4 million people fell ill with TB and 1.8 million died from the disease (including 0.4 million among people with HIV). Over 95% of TB deaths occur in low- and middle-income

countries. Tuberculosis is a leading killer of HIV-positive people: in 2015, 35% of HIV deaths were due to Tuberculosis.[8] . The majority (74%) of patients was immigrants from the Indian subcontinent [7]

More recently (since 1987) MRI and CT scans have helped the clinicians to suspect the disease at a pre destructive phase especially at difficult and rare sites, such as craniovertebral region, cervicodorsal spine, sacrum and coccyx. Conventional radiology ,CT scan , MRI , PET scan all these imaging modalities assist in different phases and consequences in proper management of tuberculosis. XRAY is typically useful in detecting bony abnormalities , like change in spinal curvature , vertebral body collapse , joint dislocation ...but information regarding cord and paraspinal soft tissue is far lagging behind than MRI .Still in developing countries where tertiary care is not achievable in villages and districts conventional radiology comes as initial modality of diagnosis , beside at ground level diagnosis even in multispecialty health care level XRAY is the initial mode of investigation along with sputum examination and its it true for both pulmonary Tuberculosis as well as for spinal Tuberculosis .Majority of cases of spinal Tuberculosis is secondary to pulmonary involvement , though chest XRAY may remain negative at the time of spinal involvement. Particularly when patient comes in typical epidemiological and clinical scenario like from endemic country as India , with low back pain or paraplegia and in few cases past history of pulmonary Tuberculosis , XRay of lumbosacral spine is prescribed as an incipient investigation . An experienced radiologist is able to guess differentials among which TB often comes as the first one , especially in our country.The advent of magnetic resonance imaging (MRI), with reported sensitivity and specificity of 100% and 88.2% respectively, for Caries spine has revolutionized the diagnosis of the condition.[8]. It can identify the pathological lesions in the early stages of the disease, correctly demonstrate the extent of the disease involvement and can monitor the response to treatment. However, the usefulness of MRI in diagnosis depends on accurate interpretations of the findings seen. Although MRI is costly investigation , and not available across the country , still due to its extraordinary contribution in diagnosis and management , it is the investigation of choice for caries spine. [9]T1 , T2 , T1FAT SAT C , STIR , GRE are basic sequences for detecting spinal infectious etiologies. MRI findings useful to differentiate tuberculous spondylitis from pyogenic spondylitis include thin and smooth enhancement of the abscess wall and well-defined paraspinal abnormal signal, whereas thick and irregular enhancement of abscess wall and ill-defined paraspinal abnormal signal are suggestive of pyogenic spondylitis. contrast-enhanced MRI appears to be important in the differentiation of these two types of spondylitis. MRI is also most effective for demonstrating neural compression.[10]

II. Objectives

1. To evaluate MRI features of caries spine .
2. To correlate MRI findings with the clinical features.

III. Materials And Methodology

Based on the inclusion and exclusion criteria , 50 cases of caries spine were studied over a in the department of Radiology , Burdwan Medical College and Hospital.Each patient was subjected to clinical examination and MRI evaluation by 2 Tesla MRI machine.

3.1 Inclusion Criteria

1. Both sexes
2. All age groups
3. Low back pain with red flag signs of spinal Tuberculosis.

3.2 Exclusion Criteria

1. Spinal malignancy with paraplegia.
2. Acute traumatic paraplegia.
3. Post operative and post radiation therapy patients with red flag signs and low back pain.

IV. Methodology

The patients attending orthopaedic clinic in Burdwan Medical College and Hospital, proper history and relevant investigations are to be done like blood,sputum for AFB.The consent to be taken and study details is explained to the patients.After fulfilling inclusion and exclusion criteria the patients are included in the study then MRI is done in free of cost for academic purpose. Initially non-contrast T1, T2 ,GRE and STIR sequences were taken in axial , sagittal, coronal planes followed by Gadonilium enhanced FST1 sequence MRI , particularly for disease extension and soft tissue involvement. The characteristic radiological findings were acknowledged as diagnostic of spinal Tuberculosis , but whenever in doubt histopathological examination were considered diagnostic.

1.4 Statistical Method

Table 1.1 Back pain

Back pain	41
Radiological findings	
Epidural abscess	12
Spondylodiskitis	47
Paravertebral abscess	17
Arachnoiditis	8

Figure 1.2

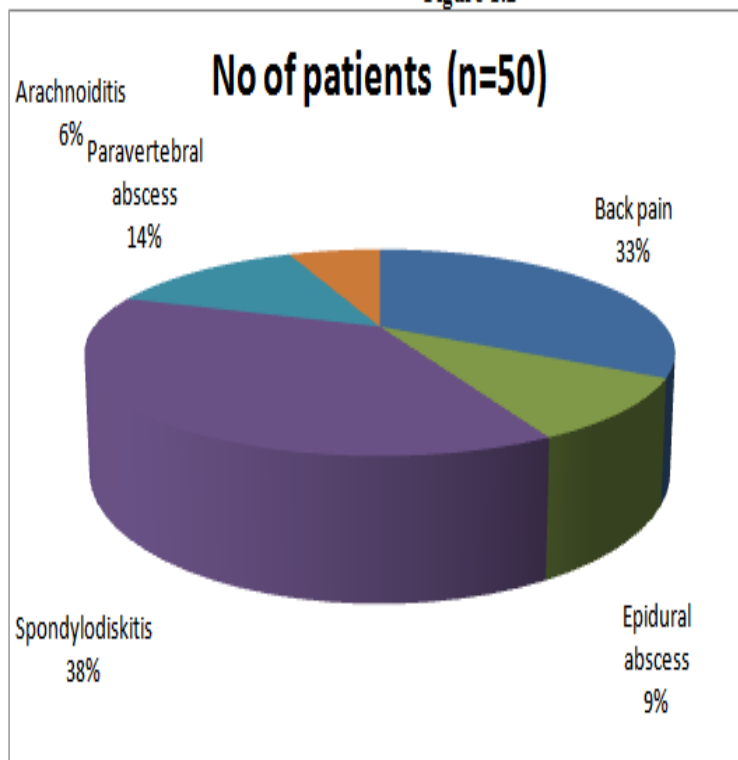


Table 2.1 Neurological deficit (clinically)

Diminished limb reflex	18
Bowel , bladder involvement	8
Gait imbalance	27
Paraparesis	12
Radiculopathy	17

Table 3.1 Radiological findings related to neurological deficit

spondylodiskitis	47
Epidural abscess	12
Paravertebral abscess	17
Cord change	13
Spinal canal stenosis	21
Spinal meningitis	8
Internal gibbus	0

Figure 3.2




Table 4.1 External deformity

Findings	Number of patients (n=50)
Radiological findings	
scoliosis	15
kyphosis	30
External deformity (clinically)	14

Result

The patients were considered irrespective of their sexes and across varied age groups extending from 15 years to 75 years, subdivided over cohorts of 9 years each. Very small (mostly paediatric) patients were kept out of the study. The patients were initially clinically evaluated and then tested radiologically by means of 2 Tesla MRI. This is an analytical style of observational study. Table 1.1 showing correlation between clinically detected back pain and its possible causative imaging features. Back pain was the most common symptom. 41 patients out of 50 were presented with this symptom. Possible causes detected radiologically are epidural abscess (24%), spondylodiskitis (94%), arachnoiditis (16%), psoas abscess (34%). Table 2.1, 3.1 showing different forms of neurological deficits and correlation with MRI findings. Neurological deficits related to spinal Tuberculosis are – radiculopathy, paraparesis, paraplegia, diminished limb reflex, gait imbalance, bladder bowel dysfunction, saddle anaesthesia etc. In our study 27 patients had gait imbalance, 18 showed diminished limb reflex, paraparesis was detected in 12 patients and 8 out of 50 had bowel – bladder disturbance. Radiologically we gathered 47 patients with spondylodiskitis, 17 with paravertebral abscess, 21 with spinal canal stenosis. Table 4.1 showing relation between external deformity detected clinically and on MRI 14 patients were presented to us with external deformity but on MRI we found 30 of them having kyphosis and 15 having scoliosis. The great discrepancy between clinical and radiological findings possibly due to various degree of involvement that minute changes failed to produce detectable external change.

V. Discussion

Tuberculosis is being one of the oldest disease of mankind with significant historical aspects. Even today it is a major health problem in developing countries. We studied 50 patients presented with red flag signs of caries spine, from February 2016 to August 2017. Out of the 50 patients 24 were males that is 48% and 26 were females that is 52%. This finding was consistent with a study conducted by Sajid Ansari, Raj Kumar Rauniyar, Kanchan Dhungel [11]. The patients were also divided into cohorts of 9 years each starting from 15 years to 75 years, the maximum number of patients belonged to the age group of 65-75 years, those were 18 out of 50 that is 36%, while the next most populous cohort was the third decade of 25-34 years which accounted for 14 patients that is 28%. This finding was also found in a study by Yu-Hung Chen^aChih BinLin^bTomor Harnod [12]. Patients were also categorized according to level of involvement, 25 of patients (50%) had dorsal spine involvement, upper lumbar spine was 2nd most common site (44%). Cervical and sacral regions were uncommon sites, we found 2 patients with cervical involvement and only 1 patient with sacral Tuberculosis. Low back pain was most common presenting feature, in 41 patients account for 82%, 2nd most common

symptom was loss of appetite , 35 patients (70%) had been gone through this symptom. Similar study has been reported by Rajeswari R et al, Jain AK et al, Nussbaum ES et al and Alothman A et al [13]. Among 2 patients involved showed features of cervical Tuberculosis had cervical pain , dysphagia , odynophagia , respiratory distress , numbness of extremities. Thoracolumbar Tuberculosis , that was most common site among the study population , had thoracolumbar region pain (87.2%) , numbness (68%) , decreased limb reflexes(36%) , paraparesis (24%) , hip joint pain (21.2%) , gait disturbance (54%) , bowel and bladder dysfunction (16%) .It was evident that thoracolumbar region pain was most frequent was detected in 41 patients.

Radiological features of caries spine was quite obvious on MRI , specially epidural extension and cord change detection was accomplished by using contrast MRI. Radiologically we found four types of involvement in caries spine – Paradiscal , Central , Anterior and Appendicular . Paradiscal types was also the most common variety presented in 42 pt (84%) , central types was next most common in 10 pt (20%) , 5 patient (10%) with appendicular type .8 patients who showed anterior type. These findings were supported by similar study conducted by Ravindra Kumar Garg and Dilip Singh Somvanshi [14]MRI detected vertebral body wedging in 68% of patients , that was consistent with finding in a study conducted by Sajid Ansari1 , Raj Kumar Rauniyar , Kanchan Dhungel , Panna Lal Sah[15]. Out of 50 patients 23 were detected with anterior vertebral body scalloping ,corresponding to 46% . Vertebral body scalloping could be due to subligamentous spread of infection or from lymphadenopathy . vertebral endplates showed prominent changes(unsharpening , irregularity , erosion , sclerosis) , 34 pt (68%) were observed with endplate sclerosis and 40 pt (80%) with erosion .

Disc space involvement is the cardinal feature of tubercular spondylodiscitis , disc space sparing can occur but still it is a atypical finding. Disc space height reduction , obliteration of internuclear cleft , its intensity change and enhancement pattern were detected. Spondylodiscitis well correlate with back pain , observed in 41 patients . MRI also accumulated 41 cases(82%) with disc height reduction , enhancement with gadolinium , intensity change(hypointense on T1 , hyper on T2 and STIR) , 38% cases with margin irregularity and 37 cases(74%) who showed obliteration of internuclear cleft. These findings were also supported by Smith AS et al [16] ,named Imaging analysis of caries spine in urban population.

In the study group spinal Tuberculosis found to involve paravertebral soft tissue and this was more consistent with paradiscal and anterior types. Paravertebral involvement was rare with central and appendicular types. Paravertebral soft tissue involvement is considered to be one of the contributory factors for constant back pain , detected in 41 patients. MRI noted 17 cases(34%) who had paravertebral soft tissue involvement , near similar finding also observed in study by Shashikumar M.R., Basavaraj S.B , Vishwanath V. Joshi et al [17]. Clinically 14 patients had visible external deformity but strikingly 30 patients were found to have kyphotic deformity at thoracolumbar region , only 15 had scoliosis , corresponding to 60% and 30% respectively, on MRI . A study conducted by Sushil Paudel, Teaching Assistant, Department of Orthopaedics, Tribhuvan University Teaching Hospital also noted similar findings[18]. Though uncommon but still very few patients were detected to be presented with atypical signs of spinalTuberculosis ; like skipped lesions , floating disc etc . Number of patients with skipped lesions were 4. Floating disc also was present in 4% of patients. Cases of both anterior and posterior epidural space involvement was present in the study.

MRI noted 12 cases (24%) having epidural extension . Compromised epidural space can cause cord compression as well as narrows lateral recess , thus causing neurological deficits , like paraparesis (12 patients) , diminished limb reflex (18 patients) , gait imbalance (8 Patients) diagnosed clinically. Involved epidural space turned hypointense on T1 , hyper on T2 and STIR sequences and out of 12 around 7 took gadonilium contrast on T1 contrast study. A retrospective study titled Surgical detection of spinal epidural involvement in caries spine by Joaquim Soares Do Brito, MD, Antônio Tirado, MD, and Pedro Fernandes, MD also diagnosed finding consistent with this. [19]. We found that neurological symptoms were present in patients with degree of spinal canal compression exceeding 20% , those with signs of arachnoiditis and cord involvement, epidural extension etc .

Cord change was noted in 13 patients (26%) and 21 patients had spinal canal narrowing. Omari B et al reported similar observation [20]. Out of 36 patients presented with neurological symptoms 8 of them were observed with arachnoiditis on mri and clinically they deteriorated over time. We diagnosed spinal meningitis by using T1 contrast and T2 sequences. There was clumping of nerve roots , wavy nerves , enhancement of nerve roots. Tubercular infection widely infiltrate bone marrow within vertebral body leading to replacement of fatty marrow and more water retention . 48 patients had marrow intensity change on MRI study . Comparable studies have also been reported by J Purseyl, Zaidi H and Andronikou S et al in their study [21].

VI. Conclusion

Caries spine was found to be commonest in the age group of 65-75 years followed by 25-34 years in the study. There was slight female predominance. Most common presenting symptom was low back pain, followed by loss of appetite. Spinal Tuberculosis was found to involve cervical, thoracic, lumbar, sacral segments, but commonest region was Thoracolumbar junction. Among 4 patterns of involvement paradiscal was predominant type in this study. The commonest radiological sign of spinal Tuberculosis detected in 98% patients was vertebral body intensity change. 2nd most common sign was discitis. This finding well correlated with clinically observed back pain. MRI succeeded to detect discitis in good number of patients. Early features of vertebral end plate changes like sclerosis, irregularity and disc space involvement like, enhancement, intensity change were successfully diagnosed on MRI. MRI stands excellent in its soft tissue resolution and detecting minute cord oedema and epidural extension. Few cases of spinal meningitis were observed on contrast MRI. Significant number of patients also had spinal canal stenosis. These all are contributory factors of neurological deficits (in the forms of radiculopathy, paraparesis, diminished limb reflex, gait imbalance etc) detected clinically. The MRI scan is highly sensitive in the detection of numerous aspects of spinal tuberculosis, serves excellent resolution of soft tissue involvement, cord related changes and features of radiculopathy. It stands to be an excellent modality in differentiating spinal Tuberculosis from pyogenic spondylitis. Hence MRI plays grand role in overall management starting from early detection of radiological signs in suspected cases as well as in patients with red flag signs of caries spine, assessment of disease response to treatment, and in differential diagnosis. MRI should be the base investigation in suspecting cases of spinal Tuberculosis.

Bibliography

- [1]. Taylor GM, Murphy E, Hopkins R, Rutland P, Chistov Y. First report of Mycobacterium bovis DNA in human remains from the Iron Age. *Microbiology* 2007;153(4):1243-9
- [2]. World health organization WHO Report 2008. Global Tuberculosis Control Surveillance, Planning, Financing. Geneva 2008.
- [3]. WHO fact sheet on Tuberculosis <http://www.who.int/mediacentre/factsheet/fs104/en/index.html>.
- [4]. Park K. Park's textbook of preventive Social Medicine. K Park; 23rd edition; Banarsi Das Bhanot publishers, Jabalpur, India 2015.
- [5]. Fitzgerald D and Has Dw. Mycobacterium Tuberculosis. In Mandall GL, Bennet JE and Dolin R (editor) Mandell, Douglas, and Bennett's Principles and practice of infectious Disease 6th edition Elsevier Churchill Livingstone. Philadelphia 2005:2852-2886.
- [6]. Harrison principle of internal medicine; 18th edition
- [7]. World Health Organization. 2010/2011 tuberculosis global facts. Facts sheet no 104, 2010 Nov [accessed on 2011 Apr 16]
- [8]. Frieden T. Tuberculosis case detection, treatment, and monitoring questions and answers. WHO, Geneva, 2004
- [9]. Diagnostic Radiology – Musculoskeletal and Breast Imaging
- [10]. Taylor, Huges & Resnik Skeletal Imaging – Atlas of the spine and Extremities, 2nd edition. 2010, 2000 by sundres, an imprint of Elsevier Inc.
- [11]. MR evaluation of spinal tuberculosis, By Sajid Ansari¹, Raj Kumar Rauniyar, Kanchan Dhungel; et al. Department of Radiodiagnosis, Department of Orthopedics, B.P. Koirala Institute of Health Sciences, Dharan, Nepal.
- [12]. Treatment modalities for tuberculosis of the spine: 22 years' experience in east Taiwan by Yu-Hung Chen^a, Chih-Bin Lin^b, Tomor Harnod^c; et al.
- [13]. Pott's Spine: Diagnostic Imaging Modalities and Technology Advancements; by Rajeswari R et al, Jain AK et al, Nussbaum ES et al and Alotman A et al
- [14]. Spinal tuberculosis: A review by Ravindra Kumar Garg and Dilip Singh Somvansh.
- [15]. MR evaluation of spinal tuberculosis Sajid Ansari¹*, Raj Kumar Rauniyar¹, Kanchan Dhungel¹, Panna Lal Sah¹, Pashupati Chaudhary², Kaleem Ahmad¹ and Md. Farid Amanullah².
- [16]. Smith AS, Weinstein MA, Mizushima A, Coughlin B, Hayden SP, Lakin MM, et al. MR imaging characteristics of tuberculous spondylitis vs vertebral osteomyelitis. *AJR Am J Roentgenol*, 1989; 153:399-405.
- [17]. Role of MRI in the evaluation of spinal tuberculosis by Shashikumar M.R., Basavaraj S.B., Vishwanath V. Joshi; et al.
- [18]. Kyphotic deformity in Pott's spine Poudel S, Sushil Paudel, Teaching Assistant, Department of Orthopaedics, Tribhuvan University Teaching Hospital, Kathmandu, Nepal
- [19]. Surgical detection of spinal epidural involvement in caries spine by Joaquim Soares Do Brito, MD, António Tirado, MD, and Pedro Fernandes, MD
- [20]. Omari B, Robertson JM, Nelson RJ, Chiu LC. Pott's disease. A resurgent challenge to the thoracic surgeon. *Chest*, 1989; 96:955-6
- [21]. J Pursey J, Zaidi H, Andronikou S et al; Magnetic resonance imaging of tuberculous spondylitis. 1990;128:989-505.

*Shyam Lal Agarwal. "Mri Evaluation of The Pattern of Involvement in Caries Spine With Clinical Correlation." *IOSR Journal of Dental and Medical Sciences (IOSR-JDMS)*, vol. 16, no. 12, 2017, pp. 29-34.