

Laparoscopic Redo Cholecystectomy in Stump Cholecystitis.

¹*Dimple Thakkar, ²Vishakha Kalikar, ³Sachin Wanisharad Gurav,⁴
Roy V Patankar

Abstract: Stump Gall Stones Can Present As Abdominal Pain Or Jaundice, Months To Years Later After Cholecystectomy. Remnant Stump Of Gall Bladder (With Stones) Left During Difficult Cholecystectomy, Frozen Calots With Subtotal Cholecystectomy Or Inexperienced Lap Surgeon Is Usually The Cause. These Cases Are Extremely Difficult To Diagnose By Routine Imaging. We Describe Redo Cholecystectomies In 9 Such Patients.

Keywords: Laparoscopic, Redo, Stump

Date of Submission: 05-04-2017

Date of acceptance: 19-12-2017

I. Introduction

With Advent Of Laparoscopy, More And More Surgeons Are Doing Laparoscopic Cholecystectomy. Inexperienced Laparoscopic Surgeons Tend To Do Subtotal Lap Cholecystectomy Leaving Behind Large Stumps. Also Large Stumps Are Left During Subtotal Cholecystectomy In Frozen Calots Triangle. Some Patients Come Back With Post Cholecystectomy Pain, Where Stones In The Remnant Stump Are The Cause. These Cases Are Extremely Difficult To Diagnose By Routine Imaging. All These Redo Cholecystectomies Are Now Increasingly Being Done Laparoscopically. We Describe Redo Cholecystectomies In 9 Such Patients.

II. Materials And Methods

Patients Underwent Cholecystectomy – 7 Laparoscopic And 2 Open Between 2001 And 2010. 5 Male, 4 Female. Median Age Was 45 Years (Range 35-60 Years). They Presented With Dyspepsia, Pain Or Jaundice (1 Patient Had CBD Stones And 1 Patient Had Altered LFT). The Time Of Presentation Ranged From 1 Month To 4 Years Post Cholecystectomy. They Were Diagnosed On Imaging (USG And MRCP) With Stump Cholecystitis. Preoperative ERC, CBD Clearance Was Done In Patients With CBD Stones. ERC Stenting Was Done In All Patients Irrespective Of CBD Stones To Identify CBD And Prevent Intraoperative Injury To CBD. Revision Cholecystectomy Was Completed Laparoscopically In All Patients Except One Conversion. The Mean Operating Time Was 90 Minutes. Mean Blood Loss Was 100 ml. On Follow Up At 1 Yr, They Were All Asymptomatic.

III. Imaging In Stump Cholecystitis

Diagnosing Stones In Surgical Remnants Of The Cystic Duct Or Gallbladder Can Be Difficult. The Sensitivity Of Abdominal Ultrasonography In Detecting Cystic Duct Stones Is Low - Only 27% In One Study, With A Specificity Of 100% And An Accuracy Of 75%. MRCP Is The Modality Of Choice.

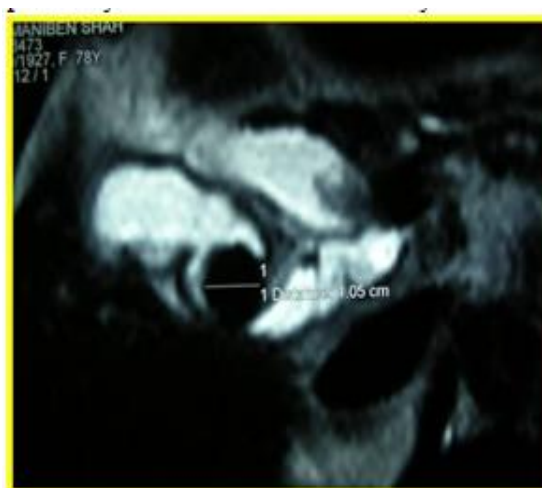

Fig 1: Stone In Remnant GB Stump

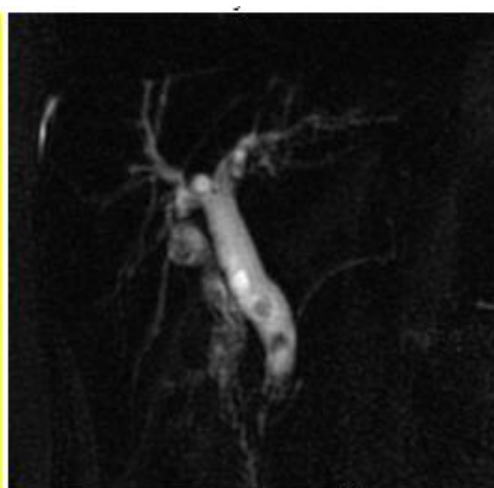

Fig 2: CBD Stones With GB Stump

IV. Operative Steps

1. Initial Port At Umbilicus By Open Technique.
2. After Previous Cholecystectomy, Remnant Stump Is Embedded In Inflamed Scar Tissue.
3. Adhesions Were Removed With Ultrasonic Scalpel
4. The Remnant GB Was Identified And Excised And The Cystic Duct Was Ligated.
5. In All Patients Cystic Artery Could Be Dissected And Clipped Separately.

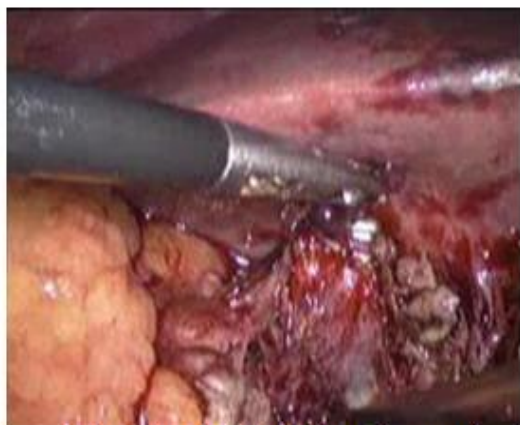


Fig 3:Fundus First Being Dissected

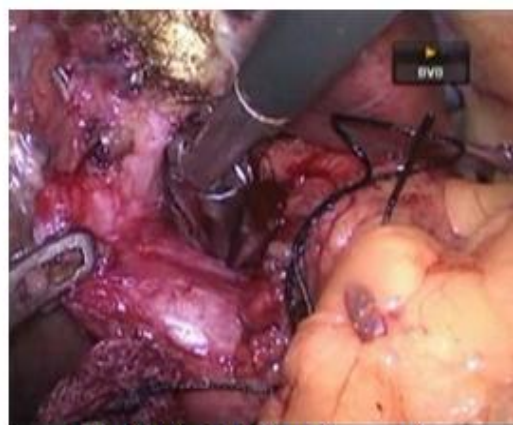

Fig 4:Calot's Being Dissected

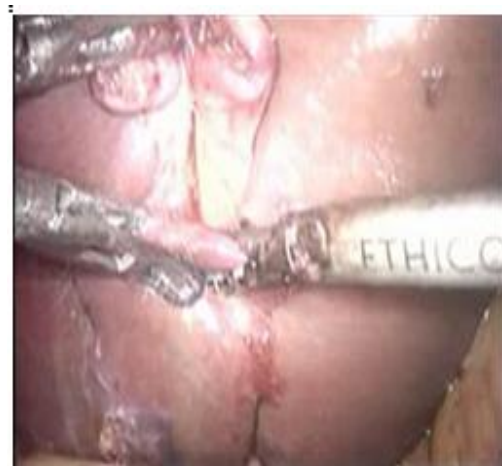

Fig 4:Liver Dissected To View The GB

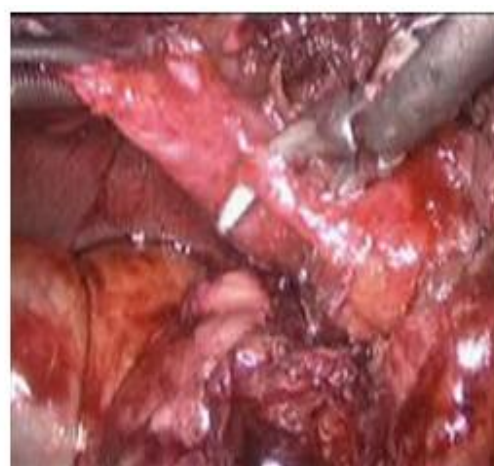

Fig 5:Cystic Artery Being Dissected

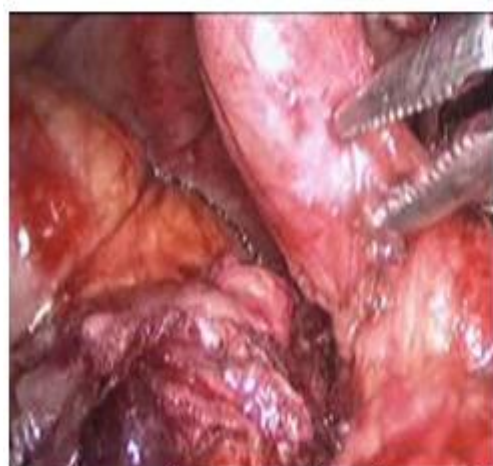

Fig 6:Cystic Artery Being Dissected

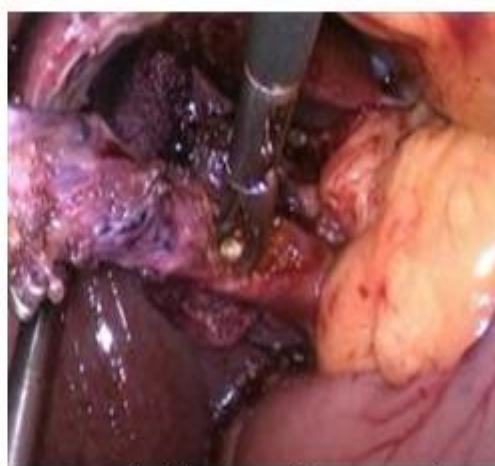

Fig 7: Calculi Extracted From Cystic Duct

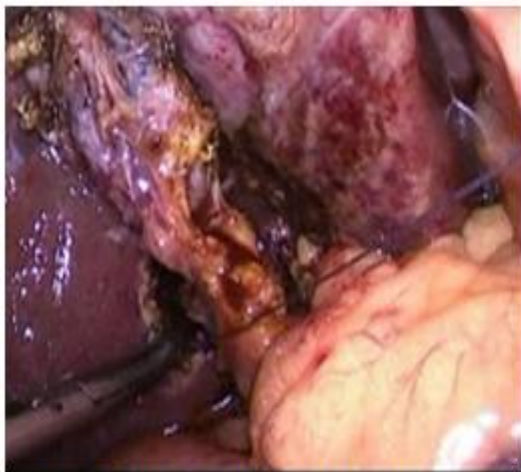

Fig 8: Cystic Duct Being Ligated

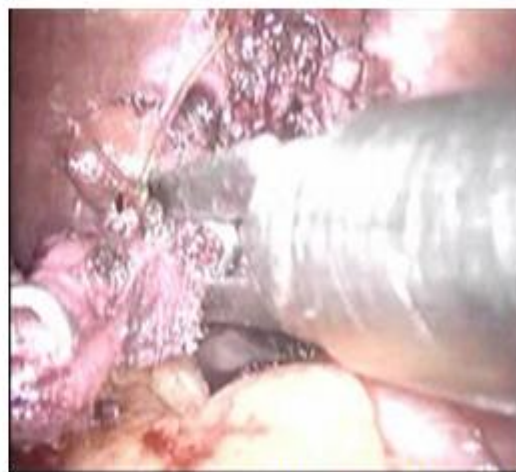

Fig 9: Cystic Duct Being Clipped

V. Discussion

1. The First Case Of Cystic Duct Remnant, The So-Called Reformed Gallbladder Containing Stones, Was Described In 1912 By Flörcken. ⁽¹⁾ Cystic Duct Remnant Is Defined As Cystic Duct Greater Than 1 Cm In Length With Or Without Stones. ^(2,3) Surgical Risk Was Considered To Be Too High In Redo Cholecystectomy To Be Attempted Laparoscopically. Clemente And Chaubey Both Have Demonstrated Feasibility Of Lap Redo Cholecystectomy. ^(4,5)
2. Care Should Be Taken To Prevent Long Stumps. If Subtotal Cholecystectomy Is Done GB Mucosa Should Be Cauterized With Bipolar Energy And Stump Lumen Obliterated. ERC Stenting Prior To Redo Surgery Should Be Done To Prevent CBD Injury.

VI. Results

All 9 Procedures Were Completed Laparoscopically Except One Conversion Due To Excessive Adhesions. All Patients Were Asymptomatic At 1 Yr Follow Up.

VII. Conclusion

Long Stump Must Be Avoided During Cholecystectomy. Preoperative MRCP Is The Optimal Choice For Diagnosis And Absolutely Imperative. ⁽²⁾ Preoperative ERC Stenting Helps In Preventing CBD Injury During Revision Surgery. Laparoscopic Surgery Can Safely Be Done In Patients With Stump Cholecystitis

References

- [1]. Flörcken H. Gallenblasenregeneration Mit Steinrecidiv Nach Cholecystectomie. *Deutsch Z Chir* 1912; 113:604.
- [2]. Shaw C, O'Hanlon DM, Fenlon HM, McEntee GP. Cystic Duct Remnant And The Post-Cholecystectomy Syndrome. *Hepatogastroenterology*. 2004;51:36-8.
- [3]. Rogy MA, Fugger R, Herbst F, Schulz F. Reoperation After Cholecystectomy: The Role Of The Cystic Duct Stump. *HPB Surg*. 1991;4:129-34.
- [4]. Clemente G, Giuliani F, Cadedu F, Nuzzo G. Laparoscopic Removal Of Gall Bladder Remnant And Long Cystic Stump. *Endoscopy*. 2001;33:814-5.
- [5]. Chowbey PK, Bandyopadhyay SK, Sharma A, Khullar R, Soni V, Baijal M. Laparoscopic Reintervention For Residual Gallstone Disease. *Surg Laparosc Endosc Percutan Tech*. 2003;13:31-5.

*Dimple Thakkar. "Laparoscopic Redo Cholecystectomy in Stump Cholecystitis." *IOSR Journal of Dental and Medical Sciences (IOSR-JDMS)* 16.12 (2017): 55-57