

An Unusual Presentation of Cysticercosis Infestation As Isolated Bilateral Breast Lump: A Case Report

Dr. Manoj Kumar Paswan¹, Dr. Anshu Jamaiyar², Dr. Sulekha Swarnakar³,
Dr M.A. Ansari .

¹Assistant Professor, Department Of Pathology, Rajendra Institute Of Medical Sciences, Ranchi (Jharkhand).

²Assistant Professor, Department Of Pathology, Rajendra Institute Of Medical Sciences, Ranchi (Jharkhand).

³Junior Resident, Department Of Pathology, , Rajendra Institute Of Medical Sciences, Ranchi (Jharkhand).

⁴Assistant Professor, Department Of Pathology, Rajendra Institute Of Medical Sciences, Ranchi (Jharkhand).

Abstract: Human cysticercosis is an infection which is caused by the larvae of the pork tapeworm, *Taenia solium*. They can affect any part of the body, the most common sites being the muscle, the CNS and the subcutaneous tissues. It is unusual for cysticercosis to occur in the substance of the breast. In this report, we present a case of 42-year old female who came with the history of painless mobile lump in both breasts in which excision biopsy was carried out. Histopathologically, it revealed the presence of typical cysticercus larva, along with giant cell foreign body reaction and a definitive diagnosis of bilateral breast cysticercosis was made. Although it is rare, cysticercosis should be considered as a differential diagnosis for a mass in the breast and in the areas of a greater prevalence.

Keywords: Cysticercosis, Breast, lump, Histopathology, Fibroadenoma, Parasitic infestation.

I. Introduction

Cysticercosis (*Cysticercus cellulosae*) is a zoonotic disease caused by the larval form of the nematode *Taenia solium* or pork tapeworm. Humans harbour the tapeworm in the intestine and are the definitive hosts in the parasite's life cycle. Infection occurs after ingestion of undercooked pork or by ingestion of its eggs in contaminated food or water. Cysticercosis is a public health problem and is endemic in several developing countries of Asia, Central Africa and South America. However, due to frequent migration and changes in travel patterns, it is now increasingly seen in developed nations also. The commonest site for cysticercosis is the central nervous system. The breast is an uncommon site for cysticercosis, with only a few cases having been reported in the literature^{1,2}. The patients commonly present with a cyst or a lump in the breast. This report illustrates one such case from India, where a middle age woman presented with a breast lump and diagnosis of cysticercosis was made after FNAC and histopathological examination.

II. Case Report

A Muslim 42-yr-old woman came to the surgery department for evaluation of the breasts. She complained of a lump in the both breast for the past 2 months associated with intermittent pain. She gave no history of fever or nipple discharge. Examination revealed a firm, nontender mobile lump in the right breast in the lower inner quadrant and outer upper quadrant in the left breast. The average size of lump was 3x2cm in size, hard in consistency and was free from the underlying skin. The clinical differential diagnosis of fibroadenoma or fibrocystic disease of the breast was made. The general physical and systemic examination was within normal limit. The patient came for FNAC in pathology department.

FNAC revealed clear fluid, the cytology of which demonstrates macrophages and eosinophils. Since no conclusion was made, the surgeon planned wide local excision of the both breast lump. We received specimen for histopathological examination. Microscopic examination showed complex branching of the bladder wall displaying a tegumental layer, subtegumental nuclei and loose connective tissue. Suckers and hooklets were not seen (H and E ×100). Based on the above findings of gross and microscopic examination, a diagnosis of racemose cysticercosis was made. The patient was put on albendazole 400 mg for 7 days.

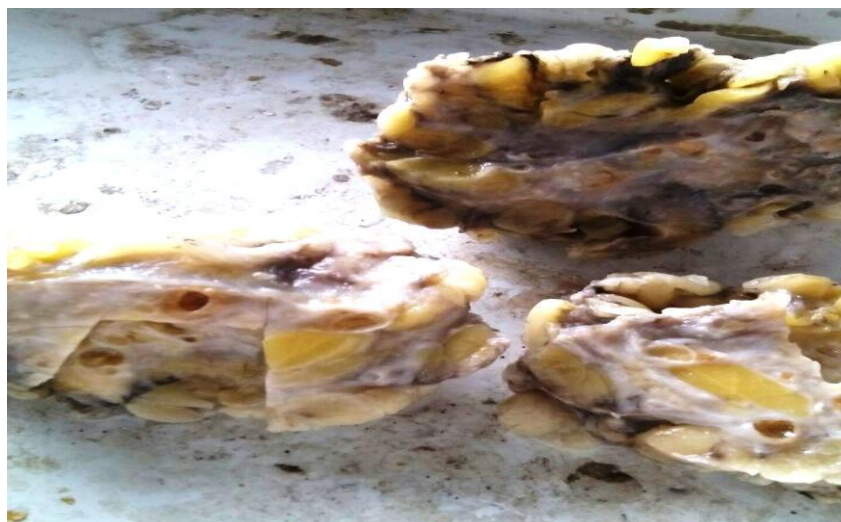

Fig.1: Gross specimen: Showing cysts and calcified nodules of varying sizes.

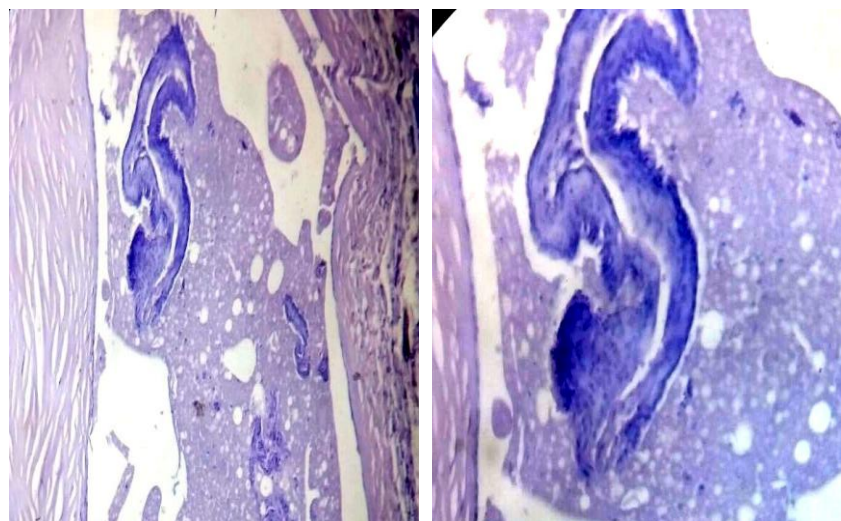


Fig.2 Left (H&E LP): Section of proliferating bladderwall of racemose cysticercus, demonstrating multiple layers.

Right (H&E HP): Shows the wall of cysticercus lined by three layers: Cuticular layer, thin middle layer and thick inner layer of loose connective tissue with inflammatory response.

III. Discussion

Cysticercosis, although common in developing nations, is an uncommon cause of a breast lump. Cysticercosis is caused by the larval stage of the human tape worm, *Taenia solium*. It continues to be a major public health problem in the developing countries, where open air defaecation and a lack of hygiene are rampant. It is present world-wide, but is most prevalent in Mexico, Africa, South-East Asia, Eastern Europe, and South America³. The cysticercus can be found in any organ, but is especially common in skeletal muscle, subcutaneous tissue, brain and eyes.

Humans are the definitive hosts of *T. solium*. There is an intermittent fecal shedding of egg containing pro-glottids or free *T. solium* eggs, which are ingested by pigs (the intermediate host) in contaminated food or water. Embryos of *T. solium* penetrate the gastrointestinal mucosa of the pig with subsequent hematogenous spread to peripheral tissues with formation of larval cysts-cysticerci. When humans consume undercooked pork, an intestinal tapeworm will be formed, and the life cycle of the worm is completed⁴. Ingestion of *T. solium* eggs present in contaminated food or water or unwashed hands or by means of an autoinoculation resulting from reverse peristalsis leads to cysticercosis in humans⁵. Cysticerci can remain viable at this stage for as long as 10 years in humans. No inflammation is elicited by living larvae. When larval death occurs, there is a vigorous inflammatory response, which produces symptoms based on the anatomic location⁶.

Amatya and Kimula reported 62 cases of histologically diagnosed cysticercosis, five of which were found in the breast substance⁷. In this case, an initial diagnosis of fibroadenoma of the breast was made, due to

its typical feature of a painless, firm and a freely mobile mass⁸. Thus, a diagnosis of cysticercosis in the unusual sites may be clinically difficult.

Cysticercosis of the breast is difficult to differentiate from neoplastic lesion on clinical grounds alone⁹. The cytomorphological identification of larvae in FNAC smears has widened the diagnostic utility of FNAC. Suspicion about parasitic lesion starts whenever clear fluid with the presence of eosinophils, neutrophils, palisading histiocytes and giant cells are aspirated¹⁰. The diagnosis of cysticercus is made when fragments of larval cuticle and parenchyma are identified. FNAC is useful in diagnosing parasitic infections. Hooklets and fragments of wall along with inflammation are required for the definitive diagnosis of *C. cellulosae*. Whenever clear fluid with eosinophilic prominence is aspirated, a search for hooklets should be made¹¹.

Patients with cysticercosis of the breast present with a nontender breast lump. High-frequency sonography can accurately diagnose the condition. The salient diagnostic feature of a cysticercus granuloma is the presence of an oval or rounded well-defined cystic lesion with an eccentric echogenic nidus within. This feature has been reported in sonography of cysticerci in the breast, skeletal muscle, subcutaneous tissue, and eye¹². The average size of cysticerci reported has been 19 mm in diameter¹³. The calcified larvae can be readily seen on X-ray examination. CT scans or MRI may reveal the presence of lesions in the brain.

The presence of clear, paucicellular fluid background, few inflammatory cells including lymphocytes, and eosinophils, and histiocytes must alert the cytopathologist to search carefully for fragments of parasites. In the absence of a parasitic fragment in the first attempt, it is prudent to perform a repeat aspirate which is likely to yield parasitic fragments and establish a diagnosis on FNAC alone.

If FNAC is inconclusive, excision biopsy of the swelling is carried out, along with a histopathological examination. Microscopic findings have been well described by Agnihotri et al. in a case of cysticercosis of the breast. They showed that the wall of the cysticercus was lined by three layers. These included a corrugated cuticular layer with hair-like protrusions in contact with host tissue, a thin middle layer, and a thick inner layer containing a loosely packed network of small canaliculi with infiltration of lymphocytes, plasma cells, and eosinophils. Multinucleate giant cells and foreign body granulomas were seen in the wall of the cyst.

The introduction of new drugs for cysticercosis has significantly changed the approach to patient management. Two drugs, praziquantel and albendazole, are effective against the cysticerci. Surgical removal is recommended when possible. Prevention involves awareness of the infection route and the use of good sanitary and personal hygiene measures. The ingestion of vegetables fertilized with sewage should also be avoided. Adequate requirements for human sewage disposal should be followed. One of the most important means of prevention is the adequate cooking of pork and pork products.

IV. Conclusion

Cysticercosis is a parasitic infestation that is commonly seen in developing nations. When breast tissue is involved, the patient presents with a firm, nontender breast lump. It is an uncommon cause of a breast lump. However, it should be kept in the differential diagnosis of breast lumps, especially in endemic areas. Clinically, it may mimic a breast tumour. Imaging features are helpful in pre-operative diagnosis. Definitive diagnosis is possible after the histological examination of the parasite. Due to widespread travel of people between countries and continents, the clinician should be aware of this rare but potentially serious breast disease.

References

- [1]. Kunkel JM, Hawksley CA. Cysticercosis presenting as a solitary dominant breast mass. *Hum Pathol*.1987; 18:1190–91. [[PubMed](#)].
- [2]. Sah SP, Jha PC, Gupta AK, et al. An incidental case of breast cysticercosis which was associated with a fibroadenoma. *IJPM*. 2001; 44(1):59–61. [[PubMed](#)]
- [3]. Jain BK, Sankhe SS, Agrawal MD, Naphade PS. Disseminated cysticercosis with pulmonary and cardiac involvement. *Indian J Radiol Imaging*. 2010; 20:310–3. [[PMC free article](#)] [[PubMed](#)].
- [4]. Tenzer R, Blumstein HA: Cysticercosis. <http://www.emedicine.com/emerg/TOPIC 119.HTM>.
- [5]. Arora PN, Sanchette PC, Ramakrishnan KR, Venkataram S: Cutaneous, mucocutaneous and neurocutaneous cysticercosis. *Indian J Dermatol Venereol Leprol* 1990; 56:115–118.
- [6]. Mittal A, Das D, Iyer N, Nagaraj J, Gupta M: Masseter cysticercosis: a rare case diagnosed on ultrasound. *Dentomaxillofac Radiol* 2008; 37:113–116.
- [7]. Amatya BM, Kimula Y. Cysticercosis in Nepal; A histopathologic study on sixty two cases. *Am J Surg Pathol*.1999; 23:1276–79. [[PubMed](#)]
- [8]. Geetha TV, Krishnanand BR, Pai CG. Cysticercosis of the breast: A rare presentation. *J. Nep Med Assoc*.2000; 39:184–85.
- [9]. Oh KK, Jeon TJ, Jeong WH: Cysticercosis of breast: a case report. *J Korean Radiol Soc* 1995; 32:835–840.
- [10]. Vijayaraghavan SB: Sonographic appearances in cysticercosis. *J Ultrasound Med* 2004; 23:423–427.
- [11]. Patnayak R, Kalyani D, Rao IS, Prayaga A, Sundaram C, Jena A: Cysticercosis: the hidden parasite with short review of literature. *Internet J Infect Dis* 2007;6(1).
- [12]. Mittal A, Das D, Iyer N, Nagaraj J, Gupta M: Masseter cysticercosis: a rare case diagnosed on ultrasound. *Dentomaxillofac Radiol* 2008; 37:113–116.
- [13]. Amatya B, Kimula Y: Cysticercosis in Nepal: a histopathologic study of sixty-two cases. *Am J Surg Pathol*1999; 23:1276.