

## Oral Manifestations And Intra-Oral Periapical Radiographic Changes In Patients with Chronic Renal Failure - An Observational Study

Mukta B. Motwani<sup>1</sup>, Sunil A. Baghel<sup>2</sup>, Anuraag B. Choudhary<sup>3</sup>

<sup>1</sup>Professor & Head, Department of Oral Medicine & Radiology, VSPM's Dental College & Research Centre, Nagpur, India

<sup>2</sup>Post graduate Student, Department of Oral Medicine & Radiology, VSPM's Dental College & Research Centre, Nagpur, India.

<sup>3</sup>Associate Professor, Department of Oral Medicine & Radiology, VSPM's Dental College & Research Centre, Nagpur, India

---

### Abstract

**Aim:** To study the oral manifestation and intra-oral periapical radiographic changes in patients with Chronic renal failure (CRF).

**Materials and Methods:** 30 subjects were selected with CRF and oral mucosa was examined in details for any changes. Intraoral periapical radiographs using bisecting angle technique were taken in the region of 46, 47, 48 and 16, 17, 18 using digital radio-visuography system.

**Result:** Oral manifestations like halitosis was present in 30 subjects (100%), altered taste was present in 29 subjects (97%), erosions were present in 27 (90%) subjects and caries were absent in 25 (86%) subject. Intra-oral periapical radiograph showed significant changes in maximum patients.

**Conclusion:** Majority of the patients had positive oral manifestation and radiographic findings which can be one of the diagnostic markers in CRF patients.

**Keywords:** Chronic renal failure, halitosis erosions

---

### I. Introduction

Although there has been an increase in renal failure cases in our country but the advances in the field of medicine has decreased the mortality and increased the life span of such patients. Dental management of patients undergoing dialysis and transplant is always a challenge as there are various systemic changes associated with it<sup>1</sup>. Chronic Renal Failure (CRF) is the result of progressive and chronic deterioration of nephrons which makes it necessary to employ extra-renal blood filtering techniques, mainly hemodialysis. Chronic renal failure occurs when the glomerular filtration rate (GFR) is reduced by at least 50ml/min<sup>2</sup>. 90% of all patient with CRF suffer oral sign and symptom affecting the bone, soft tissue structure and salivary glands . The systemic complications and oral changes that will appear in patients with chronic renal failure depends not only on the etiological factors , but also of the type of therapy that they receive from usual measures of dietary restriction, various forms of dialysis, and to renal transplantation<sup>3</sup>. Oral manifestations secondary to CRF include decreased salivary flow and unpleasant odour in the mouth, severe erosions in lingual surfaces of teeth may occur due to frequent regurgitation and vomiting induced by uremia. Impaired calcium and phosphorus balance can cause narrowing of pulp chamber and increasing the incidence of calculus. Oral manifestations in CRF patients include delayed eruption of permanent teeth in children, enamel hypoplasia of primary and permanent teeth<sup>2</sup>.

Radiographic features of renal osteodystrophy (ROD) in mandible or maxilla are bone demineralization, loss of trabeculation, ground glass appearance, total or partial loss of lamina dura, abnormal socket healing, giant cell lesions or brown tumors and metabolic calcifications. These changes appear most commonly superior to the mandibular canal or in molar region<sup>4</sup>. Radiographic abnormalities in the hand, shoulder, and pelvis were found in 51% of dialysis patients in one of the studies<sup>2</sup>. The compact bone of jaw may become thinned and eventually disappear. This may be evident as loss or thinning of lower border of mandible, the cortical margins of inferior dental canal, floor of antrum and loss of lamina dura. The aim of our study was to evaluate the oral manifestation and radiographic changes in chronic renal failure patients. As oral manifestations and radiographic alterations of the jaw bones in CRF are common and are the result of renal osteo-dystrophy (ROD) which are the spectrum of histologic changes that occur in bone architecture of patients with CRF. The kidney is the primary site for phosphate excretion and 1- $\alpha$ -hydroxylation of Vitamin D. CRF patients develop hyperphosphatemia as a result of inadequate 1,25 dihydroxyvitamin D levels that reflect reduced synthesis from parenchymal scarring. In addition, renal phosphate excretion is reduced. Together, both

processes cause serum calcium levels to fall resulting in increased secretion of parathyroid hormone (secondary HPT). Changes in bone architecture can be caused by either a high-bone turnover state or a low-bone turnover state<sup>7,8,9</sup>.

## **II. Methods**

This study was carried out in the Department of oral medicine and radiology after taking patient consent and ethical clearance from VSPM Dental college ethical committee. Total 30 subjects referred from General Medicine having chronic renal failure were selected who were willing for participation in the age group of 35-70 years, with creatinine levels more than 2 mg/dl. Oral mucosa was examined in details for any changes with the help of diagnostic instrument. Intraoral periapical radiographs using bisecting angle technique were taken in the region of 46, 47, 48 and 16, 17, 18 using digital radiovisiography system (DiagoraOptime:software DFW2.8) Interpretation of the radiographs and grading was done by 2 observers(Senior lecturer / Reader and PG student).Radiographic interpretation was done based on the appearance of lamina dura, trabecular pattern, radiographic density, and the pulp chamber size. The grading was done based on the 7 system protocol proposed by William H. Kelly et.al<sup>6</sup>. which are as follows:-

### **1. Lamina dura**

- +2 – Entire lamina dura thickened
- +1 – Portions of lamina dura thickened.
- 0 – Within normal limits.
- 1 – Lamina dura substantially thinned, missing in some areas.
- 2 – Lamina dura absent.

### **2) Trabecular Pattern**

- +2 – All trabeculae substantially coarser.
- +1 – Some coarser trabeculae, mild degree.
- 0 – Within normal limits.
- 1 – Delicate, finely meshed trabeculations.
- 2 – Granular homogenous pattern, individual trabeculae absent.

### **3) Radiographic Density**

- +2 – Severe increase in Radiographic density.
- +1 – Mild to moderate increase.
- 0 – Within normal limits.
- 1 – Mild to moderate decrease.
- 2 – Severe decrease

### **4) Pulp Calcification**

- +2 - Severe increase in pulp chamber size
- +1 – Mild to moderate increase
- 0 – Within normal limits
- 1 – Mild to moderate decrease
- 2 – Pulp chambers absent<sup>6</sup>

## **III. Results And Statistical Analysis**

Chronic renal failure disorder parameters were presented as Mean  $\pm$  SD. Categorical variables ( lamina dura, altered taste, Ground glass appearance etc) were expressed in actual numbers and percentages. Categorical variables were compared between maxilla and mandible by performing chi-square test. For small numbers, Fisher exact test was used wherever applicable. Statistical software STATA version 13.1 was used for data analysis. Baseline characteristic of our study subjects was hemoglobin, creatinine, urea, sodium, potassium level(Table 1).Oral manifestations like halitosis was present in 30 subjects (100%)(Graph 1),altered taste was present in 29 subjects(97%)(Graph 2),Erosions were present in 27(90%)(Graph 3)subjects and 25(86%) subjects did not show any carious lesion(Graph 4). Radiographic changes were noted according to 7 system protocol proposed by William H. Kelly et.al. Substantial thinning or partial absence of lamina dura(Figure 1) was noticed in 70% of the cases in maxilla, and mandible(Graph 5) .Ground glass appearance was seen in 30% subjects in maxilla and 15% subjects in mandible(Graph 6). Granular homogenous pattern, individual trabeculae(Figure 2) absent in 30% subject of maxilla and delicate, finely meshed trabeculations were seen in 26% subjects in both maxilla and mandible(Graph 7). Mild to moderate decrease in pulp chamber(Figure 3) was seen in 40% subject in maxilla and mandible(Graph 8). Mean inter-dental radiographic density in between 1<sup>st</sup> and 2<sup>nd</sup> molar was 123.1 for maxilla and 119 in mandible.

**IV. Discussion**

Chronic renal failure is a life threatening disorder that may result from a number of causes, many of which ultimately compromise renal function to the extent that patient will require either a kidney transplant or hemodialysis. CRF patients exhibit oral manifestations and radiographic changes recognition of which is important since they may be indicators of the presence or extent of the disease. In our study most frequent oral symptom among patient was bad breath (100%) and unpleasant metallic taste (97%) which is due the oral dryness in individuals under immunosuppressive therapy. In a way dry mouth is additional cause for the uremic bad odour and unpleasant taste .Low oral hygiene status ,dental plaque accumulation due to demotivation from the patients who are in this condition are additional factors. In this study we found 90% patient were suffering from dental erosion. Xerostomia may be a significant contributor to erosion in CRF patients because saliva and its components protect the dentition through various mechanisms. In the normal protective processes that occur, increased salivary flow helps dilute acids in the mouth; salivary buffers partially neutralize the acids in the oral fluid and salivary mucins and other organic components form a pellicle on the tooth surface, which inhibits or slows mineral loss during acid dissolution. Sampson and Meister suggested that tooth erosion may be linked to regurgitation during dialysis. This study also shows low incident of caries (14%) in CRF patient. The findings of a previous study by Kho H et.al<sup>10</sup> showed that the pH of the saliva of End Stage renal Disease (ESRD) patients was alkaline because of the high concentration of ammonia as a result of ureal hydrolysis. Such an elevated salivary phosphate concentration could also contribute to increase in the buffer capacity and partially explain the low caries incidence. Nevertheless, Klassen and Krasko<sup>11</sup>, in a study evaluating the dental health status of dialysis patients, found that the renal patients had worse oral hygiene than the healthy control patients, presenting larger number of caries lesions which is contradictory to present study.

When compared to the study of William H. Kelly et.al<sup>6</sup>, the present study shows Substantial thinning or partial absence of lamina dura was noticed in 70% of the cases in maxilla and mandible where as in his study it was in 50% in maxilla and 65% in mandible. Similarly, granular homogenous pattern, individual trabeculae absent in 30% subject of maxilla and delicate, finely meshed trabeculations seen in 26% subject in both maxilla and mandible where as 53% and 56% in maxilla and mandible respectively. In our study ,mild to moderate decrease in pulp chamber seen in 40% subject in maxilla and mandible where as in William H. Kelly et.al<sup>6</sup>. study it was 60% in maxilla and 53% in mandible. Davidovich<sup>12</sup> and Reddy *et al*<sup>2</sup>. in their studies stated that pulpal calcification is common in patients with end stage renal disease. Handa *et al*<sup>13</sup>. also found that significantly higher percentage of CRF patients presented with pulp calcification than the controls. The direct correlation between pulp obliteration and duration of renal failure and dialysis suggests that pulp obliteration is related to disturbances in calcification processes and altered serum calcium-phosphate (CaP) ratio due to parathyroid disturbances in CRF patients.

Previous study by P Rai et al<sup>9</sup> and Damm *et al*<sup>12</sup>, who discussed that radiographic alterations of the jaw bones in CRF are the result of ROD. In our study, ground glass appearance seen in 30% subject in maxilla and 15% subject in mandible and also changes noted in radiographic density where as blurring of anatomic landmarks 16 (32%), alteration in bony trabeculae 16 (32%), and reduced bone density 15 (30%) were the important findings in there study which is in accordance with the cases published by De Lacerda *et al* and Benmoussa<sup>14</sup>. Radiographic examination of a 38year old woman with osteodystrophy by De Lacerda *et al*<sup>15</sup>. demonstrated a mixed radiolucent/ radiopaque lesion in the mandible while in the maxilla, the tumor presented a ground glass appearance.

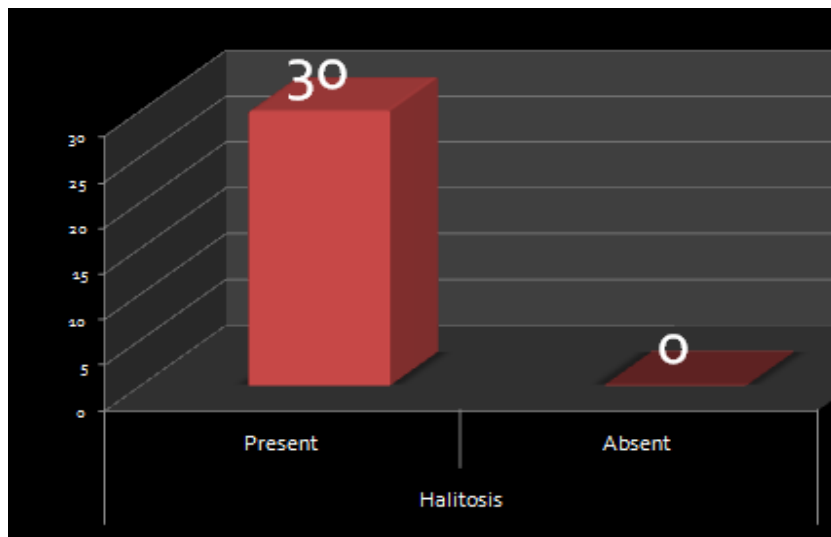
**Figures and Tables**

Tables

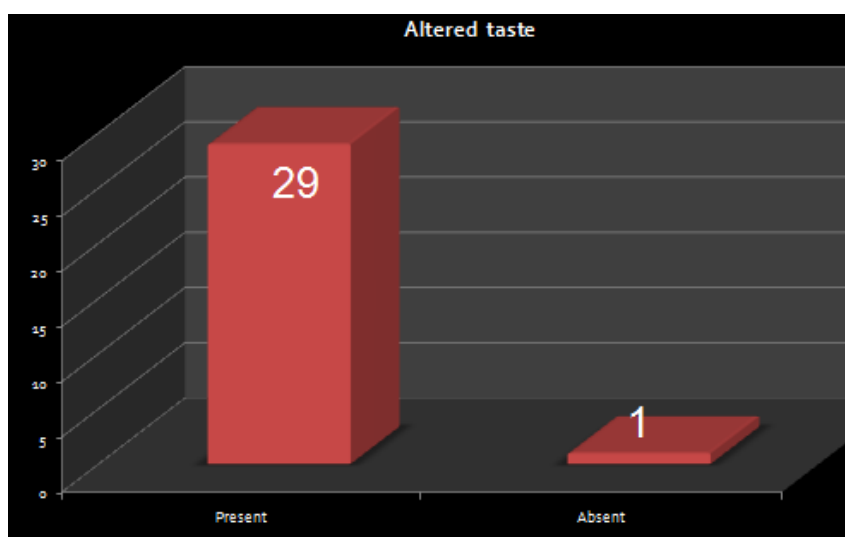
Parameter	Mean	SD	Range
Hb	10.07	1.59	6.4 – 12.0
Creatinine	6.12	2.57	2.1 – 14.8
Urea	98.07	29.73	10.5 – 137.9
Sodium	130.16	7.01	118 – 141
Potassium	5.15	1.45	2.2 – 7.7

**Table 1:** Baseline characteristic of the study subjects

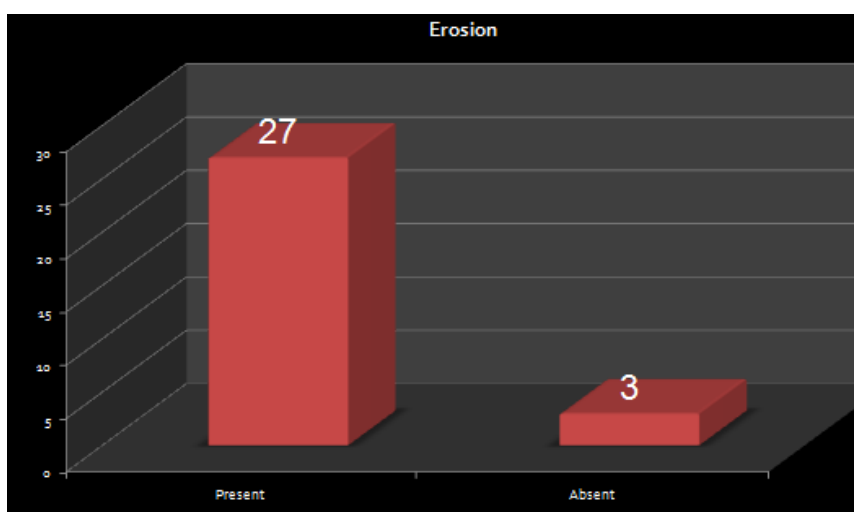
Graphs



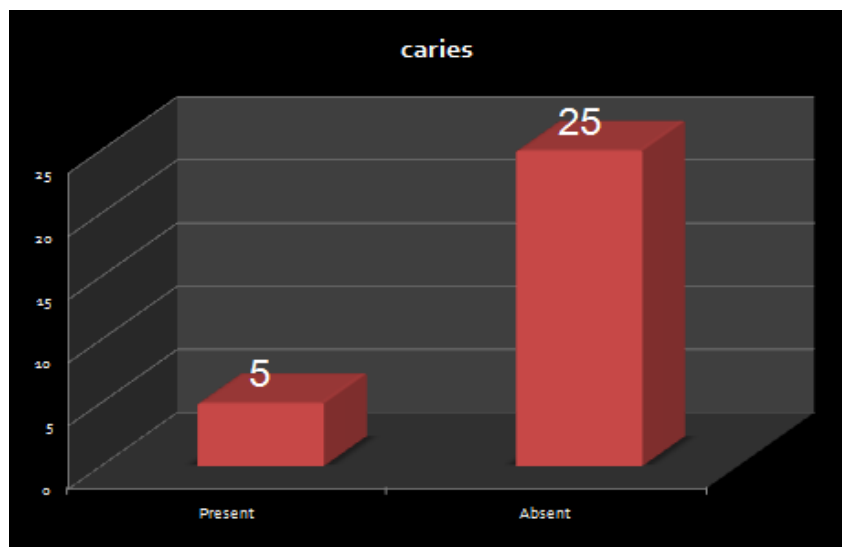
**Graph 1:** Halitosis were observed in all the subjects



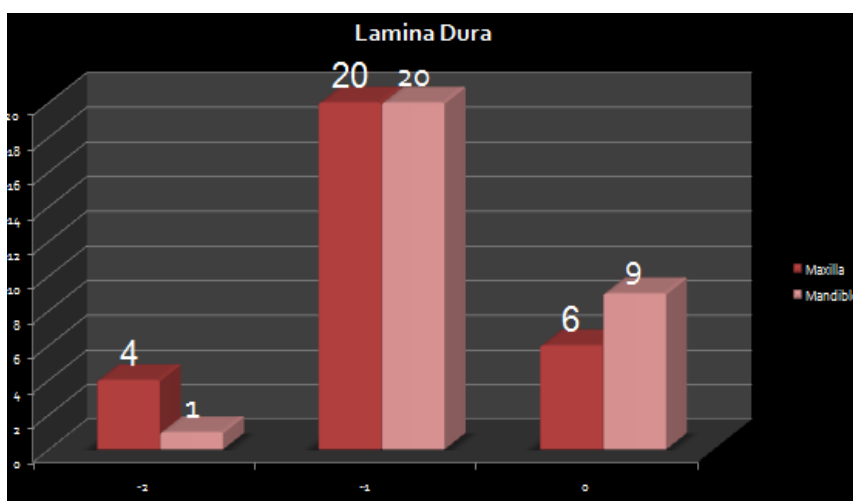
**Graph 2:** Altered taste(metallic taste) wear present with 29 subjects



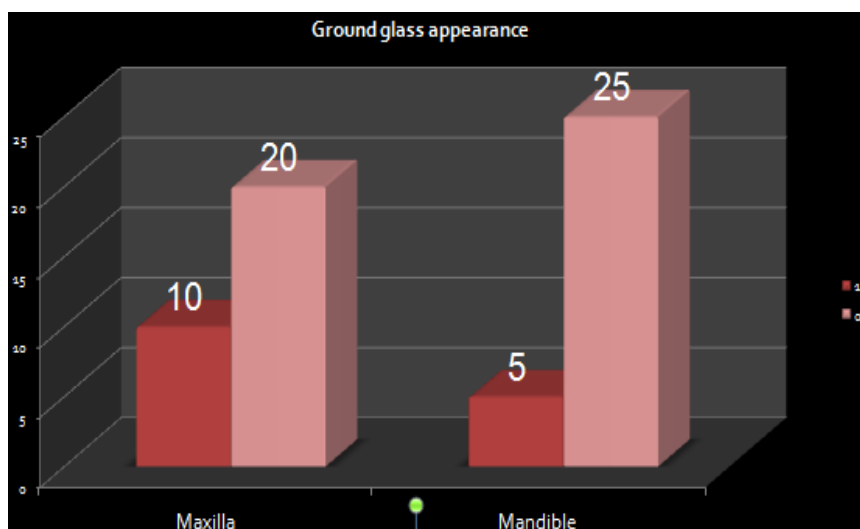
**Graph 3:** Erosion were present in 27(90%)subjects.



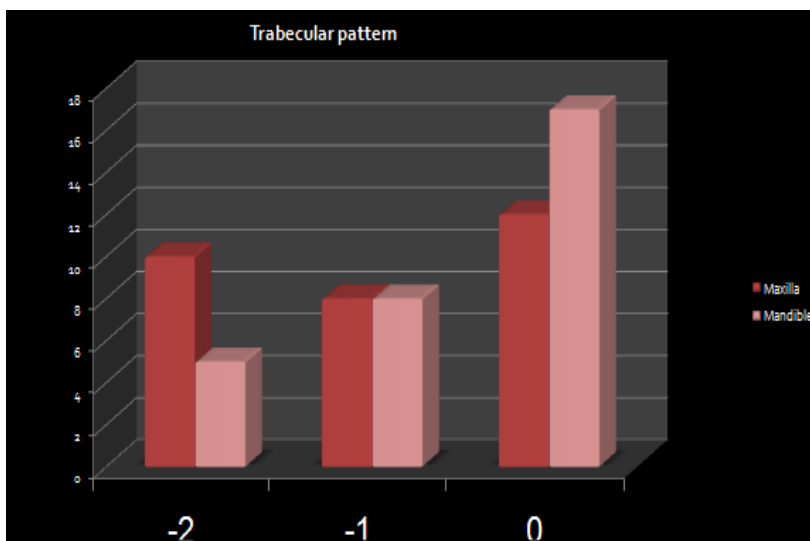
**Graph 4:** Caries were absent in 25(86%) subject.



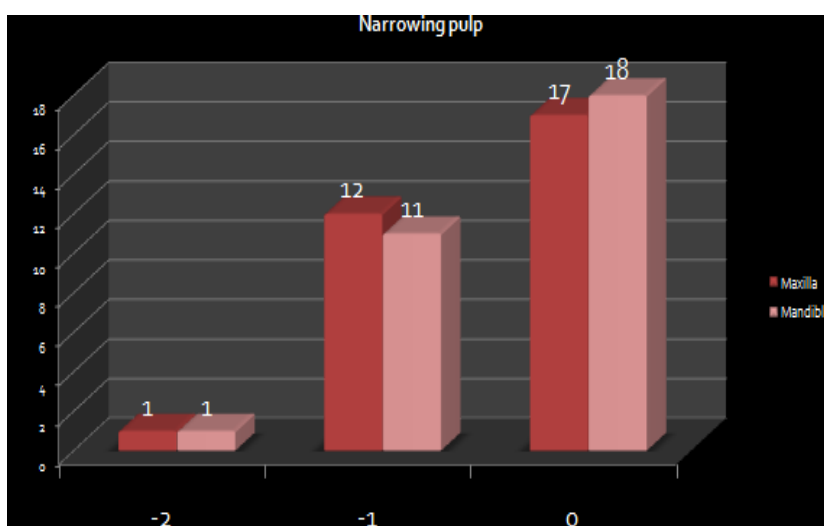
**Graph 5:** Substantial thinning or partial absence of lamina dura was noticed in 70% of the cases in maxilla , and mandible



**Graph 6:** Ground glass appearance seen in 30% subject in maxilla and 15% subject in mandible

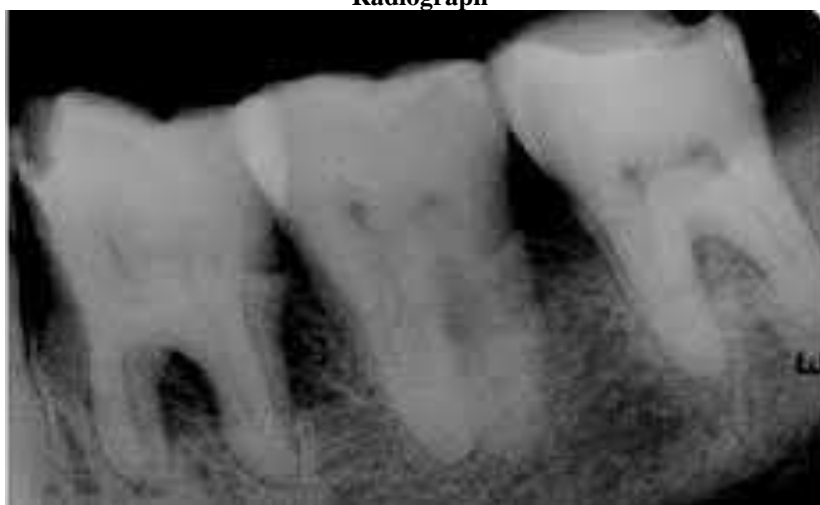

**Graph 7:** Granular homogenous pattern, individual trabeculae absent in 30% subject of maxilla and Delicate, finely meshed trabeculations seen in 26% subject in both maxilla and mandible.

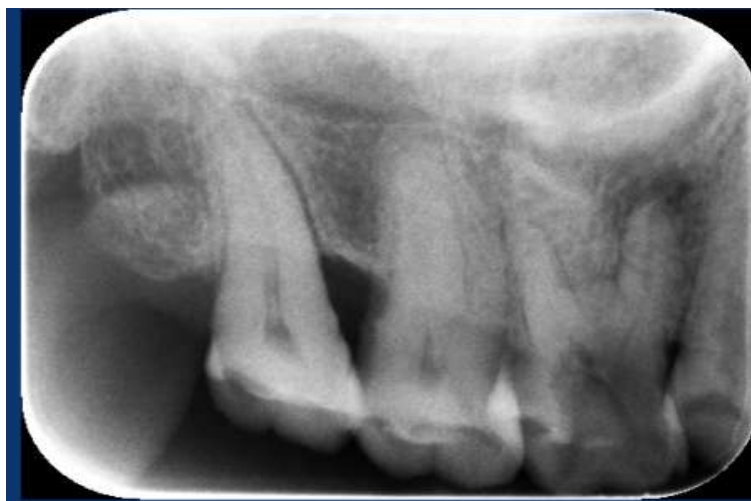

**Graph 8:** Mild to moderate decrease in pulp chamber seen in 40% subject in maxilla and mandible.

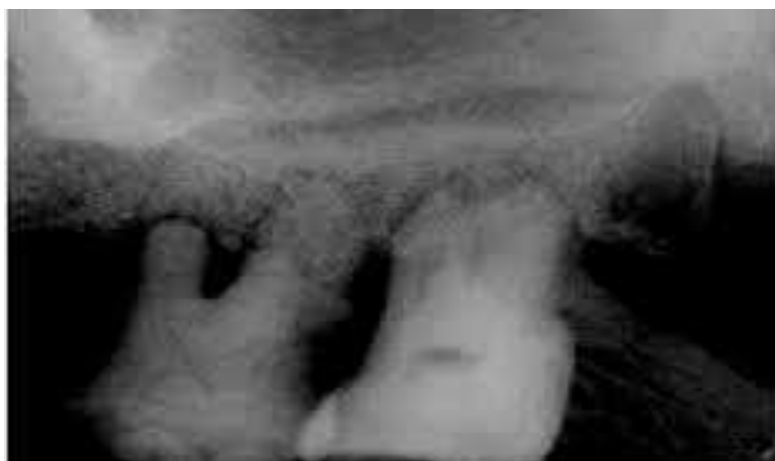### Radiograph



**Figure 1:** Loss of lamina dura



**Figure 2:** Showing loss of bony trabecule



**Figure 3:** Narrowing of pulp chamber

## V. Conclusion

The incidence of CRD continues to rise worldwide and, as a consequence increasing numbers of individuals with such disease will probably continue to require oral health care. In such a scenario, the dentists are frequently encountered with patients who have oral manifestations and radiographic changes due to renal disease. So, the systemic evaluation of the patient should be done before diagnosing the oral lesions. We can avoid the potential complications that may arise when we treat such patients and provide them good oral hygiene. Hence, we conclude that oral manifestations of systemic diseases and Intraoral Periapical Radiograph scan be used as a good prognostic tool for the assessment and management of chronic renal failure patients.

## References

- [1]. AP Nirmal, Thomas M, Utappa R, Kumar S. Oral manifestations of chronic renal failure and its management. *J Res Adv Dent*, 2015;4:1s2:7-13.
- [2]. Reddy MS, Kannan N, Patil R. Intra-oral periapical radiographic changes in patients with chronic renal failure - An observational study. *Journal of Research and Advancement in Dentistry*, July- Oct 2012;1(3):75-80.
- [3]. Belazelkovska A, Popovska M, Spasovski G, Belazelkovska Z, Minovska A, Mitic K. Oral changes in patient with chronic renal failure. *Romanian Journal of Oral Rehabilitation*, April - June 2013;5(2):104-112.
- [4]. De Rossi S, Diamond MJ. Renal disease. *Burket's oral medicine* 12<sup>th</sup> edition, 411- 434.
- [5]. Santosh P. *Oral health dent manag*. 2012 sep;11(3):100-6
- [6]. William H. Kelly et.al. Radiographic changes of the jaw bones in end stage renal disease. *Oral Surg Oral Med Oral Pathol* Vol-50, Issue-4:1980; 372-381.
- [7]. Mohanv, GuptaS. Dental health of patient undergoing hemodialysis. *Journal of Indian academy of oral medicine and radiology* 2011;23(3):208-210.
- [8]. Anuradha BR, Oral and salivary changes in patients with chronic kidney disease: A clinical and biochemical study *J Indian SocPeriodontol*. 2015 May-Jun; 19(3): 297-30.
- [9]. Rai P *et al.*: Radiographic manifestations in chronic renal failure. *Journal of Indian Academy of Oral Medicine & Radiology*. 2016( 28) 1:2-6.
- [10]. Kho HS, Lee SW, Chung SC, Kim YK. Oral manifestations and salivary flow rate, pH, and buffer capacity in patients with end-stage renal disease undergoing hemodialysis. *Oral Surg Oral Med Oral Pathol Oral Radiol Endod*. 1999;88:316-9.

- [11]. Klassen JT, Krasko BM. The dental health status of dialysis patients. *J Can Dent Assoc.* 2002;68:34–8.
- [12]. Damm DD, Neville BW, McKenna S, Jones AC, Freedman PD, Anderson WR, *et al.* Macrognathia of renal osteodystrophy in dialysis patients. *Oral Surg Oral Med Oral Pathol Oral Radiol Endod* 1997;83:489- 95.
- [13]. Handa S, Bhayana G, Atreja G. Oral manifestation in renal diseases and its related complication. *Int J Clin Cases Investig* 2015;6:6- 12.
- [14]. Benmoussa L, Renoux M, Radoï L. Oral manifestations of chronic renal failure complicating a systemic genetic disease: Diagnostic dilemma. Case report and literature review. *J Oral Maxillofac Surg* 2015;73:2142-8.
- [15]. De Lacerda JC, Gomes CC, Oliveira CS, Gomez RS. Osteodystrophy and brown tumour causing localised jaw enlargement. *Oral Surg* 2008;1:149- 52