

## A Study on the Clinical Profile and Treatment Modalities of Otitis Media with Effusion

\*Nicola C Lyngdoh<sup>1</sup>, Ishank Jaiswal<sup>2</sup>, Oinam Priyokumar Singh<sup>3</sup>,  
Dr Rituparna Saha<sup>4</sup>, Thongam Kalpana Devi<sup>5</sup>, Gyan Ranjan Singh<sup>6</sup>,  
Manvee Tomar<sup>7</sup>

<sup>1</sup>Associate Prof, Department Of E.N.T, RIMS, Imphal

<sup>2</sup>Post Graduate Trainee, Department Of E.N.T, RIMS, Imphal

<sup>3</sup>Asst. Prof, Department Of E.N.T, Rims Imphal

<sup>4</sup>Post Graduate Trainee, Department Of E.N.T, RIMS, Imphal

<sup>5</sup>Senior Resident, Department Of E.N.T, RIMS, Imphal

<sup>6</sup> Post Graduate Trainee, Department Of E.N.T, RIMS, Imphal

<sup>7</sup> Post Graduate Trainee, Department Of E.N.T, RIMS, Imphal

Corresponding author: \*Ishank Jaiswal

**Abstract:** Our objective was to study clinical profile and comparatively evaluate surgical and medical management of otitis media with effusion (OME). Fifty cases of OME were treated at department of ENT, Regional Institute of Medical Sciences, Imphal (Manipur) during a two years period between June 2015 and May 2107. They were evaluated for the clinical profile, laboratory findings and results of medical and surgical managements. Diagnosis was made from findings of pure tone audiometry (PTA) and the impedance audiometry. 23 cases (46%) were treated medically while 27 cases (54%) were managed surgically. The surgical treatment included myringotomy, Grommet insertion and adenotonsillectomy.

Hearing loss was the main presenting complaint. Tympanogram showed B type of curve in all the cases. Surgical treatment was employed in 27 cases (54%), of which grommet insertion was done in 18 cases (36%), myringotomy in 7 cases (14%) and adenotonsillectomy in 2 cases (4%). 23 cases (46%) were treated medically. Post treatment PTA showed improved hearing in 35 cases (70%) while 15 cases (30%) still had residual hearing loss. Out of the 27 cases treated surgically, 22 cases (81%) showed good response while 5 cases did not show any change. Out of the 23 cases treated medically, only 13 cases (56.5%) showed clinical improvement. Therefore surgical treatment is preferred in those cases refractory to medical therapy.

**Keywords:** Otitis media with effusion, Grommet, Myringotomy.

### I. Introduction

Otitis media with effusion is one of the most common diseases of the middle ear with an intact tympanic membrane. Presence of fluid in the middle ear, a primary feature of OME, is associated with a conductive hearing loss of up to 30-35 dB mainly due to the mass effect of the fluid to the tympanic membrane, an increase in the middle ear impedance resulting from reduced middle ear air volume and possibly from negative middle ear static pressure. OME is one of the leading causes of hearing loss in children [1]. It is an inflammatory condition of the middle ear accompanied by collection of fluid in the middle ear cleft without the signs and symptoms of acute infection such as otalgia, fever and a red or white tympanic membrane that is full and bulging. The tympanic membrane is slightly or moderately retracted with decreased mobility, opaque appearance and abnormal colour. Occasionally, an air-fluid level or bubbles can be visualized behind an intact tympanic membrane. The etiology of the OME is not known, but is commonly believed to be either persistence of effusion following an acute otitis media episode or Eustachian tube dysfunction with or without upper respiratory tract infection [2]. The effusion may be serous, mucoid (a thick, viscid, mucous like liquid), purulent (a pus like liquid), or a combination of these. The effusion may be acute (<3 weeks), sub acute (3 weeks to 3 months) or chronic (>3 months). Many sequential studies have reported that 20% to 50% of children will have an episode of OME sometime between the ages of 3 and 10 years. Latent or overt hearing loss is the usual symptom, which often fluctuates in severity, recognized by the parents or the school teachers from the child's speech development or slow educational process [3].

Diagnosis of OME is made from history, clinical examination including pneumatic otoscopy and tuning fork tests, laboratory tests such as pure tone audiometry (PTA) and impedance audiometry, and surgical procedure like myringotomy [4]. PTA can provide the type and degree of hearing loss but it does not identify OME. Impedance audiometry is the diagnostic test showing a "B" type flat curve usually bilaterally.

Management of OME is a controversial topic in otology. Medical treatment is directed towards controlling infection and allergy, reducing oedema and inflammation of the Eustachian tube, nasopharynx and nose, and improving middle ear ventilation. Surgical treatments are usually reserved for those cases refractory to medical treatment. Myringotomy and grommet insertion are standard treatments today. Adenotonsillectomy is done in selected cases when these normal anatomical structures become abnormally enlarged. Nowadays, in younger children, adenoidectomy together with the use of ventilating tubes is done to effect lasting results [5]. The purpose of this research work is to study the clinical profile, to diagnose accurately, and to study the effectiveness of different treatment modalities of OME at an institutional setup in order to detect early and treat effectively of such a common and refractory disease process.

## II. Materials and Methods

The present prospective study was carried out in the department of Otorhinolaryngology, Regional Institute of Medical Sciences, Imphal (Manipur) during the period between June 2015 and May 2017. Fifty consecutive patients diagnosed as cases of OME, who attended the Outpatient Department and/or were admitted in the ward irrespective of age, sex and socioeconomic status formed the study group.

A detailed history was obtained for each case followed by a complete physical examination of the ear, nose and throat. Apart from the routine investigations, special investigations including PTA, impedance audiometry, X-ray PNS and mastoids were done for each and every case. The clinical findings and the results of PTA and impedance audiometry were recorded.

Medical treatment was given to those cases with mild disease or those who refused surgical interventions. Medical treatments included systemic antibiotics, decongestants, antihistamines and mucolytics (Acetyl Cysteine) for a period of 2 weeks. Surgical treatments were performed in those cases with severe signs and symptoms, or those refractory to previous medical treatment. Surgical interventions included myringotomy, grommet insertion and adenotonsillectomy. Myringotomy and grommet insertions were done either under local or general anaesthesia under endoscopic guidance using a rigid endoscope, whereas adenotonsillectomy was done traditionally under general anaesthesia only. A minimum follow up period of one year at 3 months, 6 months, 9 months and 1 year was done in all the cases. The criteria for improvement were taken as hearing loss of less than 20 dB, normal looking tympanic membrane and alleviation of symptoms.

## III. Results

Fifty patients of OME were included in the present study. The characteristics of this group of patients are indicated in Tables I and II.

**Table I. Age distribution**

Age (Years)	Number of patients	Percentage
2-4	4	8%
5-8	27	54%
9-16	6	12%
17-30	4	8%
>30	9	18%
<b>Total</b>	<b>50</b>	<b>100%</b>

The age of the patients ranged from 4 years to 50 years. Majority of the patients (54% of the cases) were between 5 and 8 years of age. The youngest age was 4 years and the oldest 50 years of age.

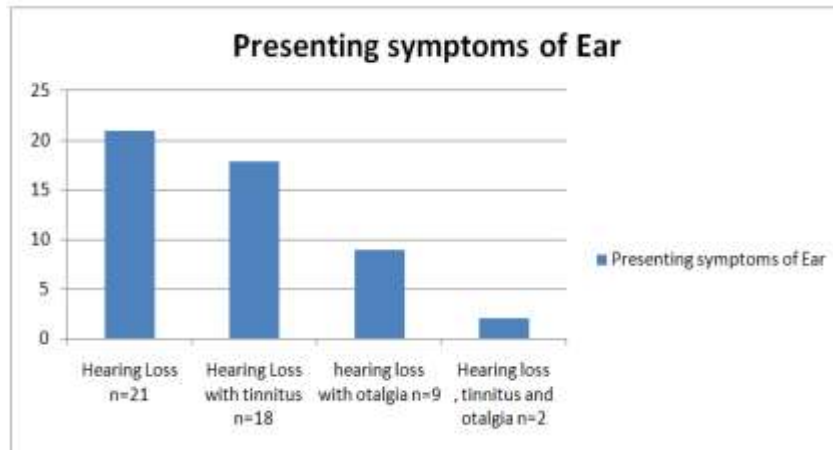
**Table II. Sex distribution**

Sex	Number of cases	Percentage
Male	30	60%
Female	20	40%
<b>Total</b>	<b>50</b>	<b>100%</b>

Males outnumbered females at a ratio of 3:2 (males=30, females=20).

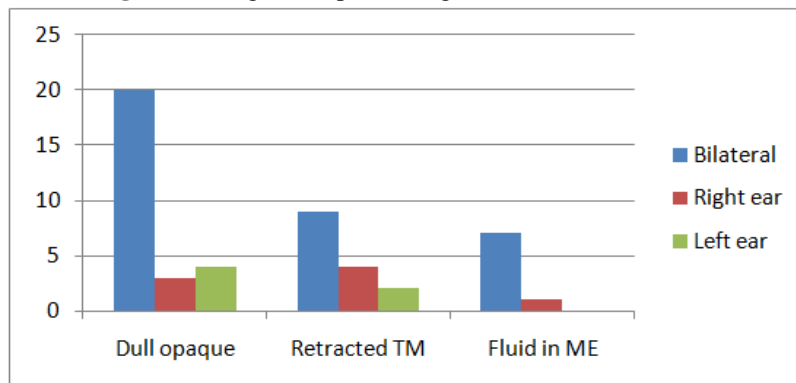
Hearing loss was the main complaint in all the cases; 21 cases (42%) complained of hearing loss alone, 18 (36%) complained of hearing loss with tinnitus, 9 cases (18%) with hearing loss and otalgia and 2 patients (4%) complained of all the above three symptoms (Fig 1). Nasal obstruction is the second commonest symptom (18 cases) followed by neck nodes (8 cases) and sore throat (7 cases).

**Fig 1.** Showing presenting complaints of OME pertaining to ear symptoms.



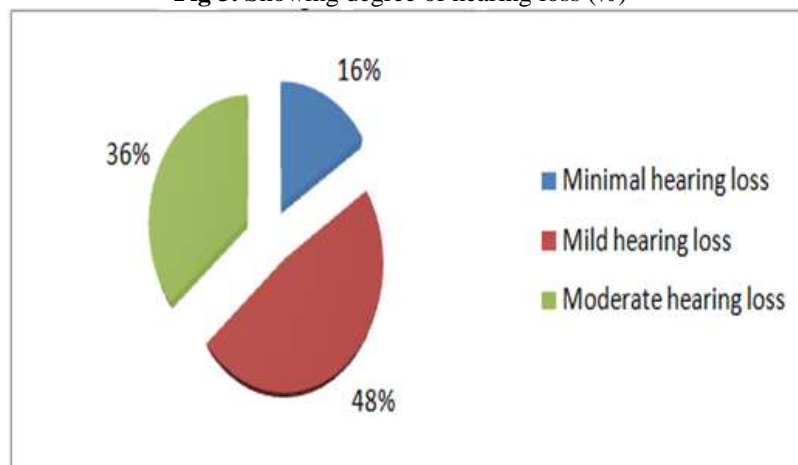
Tympanic membrane (TM) was dull opaque in 27 cases (54%) and retracted in 15 cases (30%). 8 cases (16%) had fluid in the middle ear. Out of 50 pairs of ear examined, 36 ears had bilateral involvement and 14 ears had unilateral involvement (8 in the right ear and 6 in the left ear). 20 patients (40%) had dull opaque TM bilaterally, 3 patients (6%) had dull opaque TM in right ear and 4 patients (8%) had dull opaque TM on left ear. Retracted TM was seen bilaterally in 9 patients (18%), in the right in 4 patients (8%) and in the left ear in 2 patients (4%). Middle ear fluid was seen bilaterally in 7 patients (14%) and in the right ear in 1 patient (2%). (Fig 2)

**Fig 2.** Showing otoscopic findings with the side involved.



Minimal hearing loss (16-25 dB) was present in 8 patients (16%), mild hearing loss (26-40 dB) in 24 cases (48%) and moderate hearing loss (41 to 55 dB) in 18 patients (36%). (Fig 3)

**Fig 3.** Showing degree of hearing loss (%)

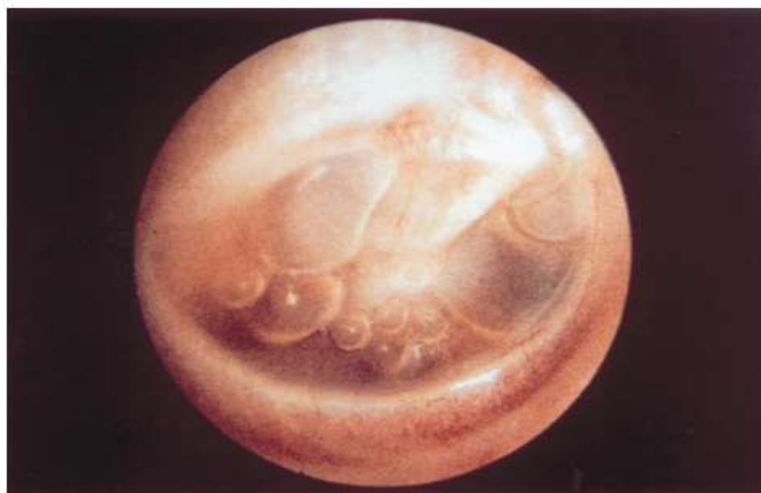

Tympanogram revealed B type curve in all the cases; bilateral in 36 cases (72%), unilateral in 14 patients (28%). (Table III)

**Table III.** Types of Tympanogram Curve.

Type of Tympanogram curve	Number of patients	Percentage
'B' type - Bilateral	36	72%
'B' type – Right side	8	16%
'B' type – Left	6	12%
<b>Total</b>	<b>50</b>	<b>100%</b>

**Figure 4** showing endoscopic view of OME noted by presence of bubbles.



Out of the 50 cases, 23 cases (46%) were treated medically and 27 (54%) were treated surgically. Grommet insertion was done in 18 cases (36%), myringotomy only in 7 patients (14%) and adenotonsillectomy in 2 young patients (4%). (Table IV).

**Table IV.** Treatment methods

Treatment	No. of Patients	Percentage
<b>Surgical</b>	<b>27</b>	<b>54%</b>
• Grommet insertion	18	36%
• Myringotomy	7	14%
• Tonsillectomy	2	4%
<b>Medical</b>	<b>23</b>	<b>46%</b>
<b>Total</b>	<b>50</b>	<b>100%</b>

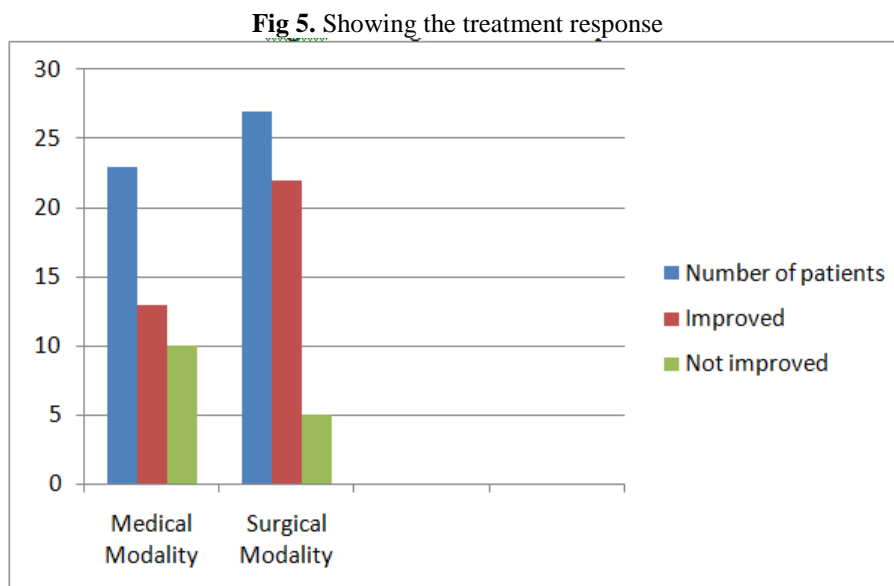
Follow up was done for all the patients for a minimum period of one year at 3 months, 6 months, 9 months, and 1 year. During the follow up, PTA, otoscopic and endoscopic examination was done in all the patients. PTA results indicated that 35 patients (70%) had improved hearing (<20 dB) and 15 patients (36%) still had residual mild hearing loss. The TM was normal in 35 cases (70%), dull and opaque in 9 cases (18%) and slightly retracted (1<sup>st</sup> degree) in 6 cases (12%). There was not a single case of fluid in the middle ear on follow up. (Table V)

**Table V.** Follow up otoscopic appearance of TM and PTA Results.

Follow up findings	No. of cases	Percentage	Total
<b>Otosopic findings of TM</b>			
Normal	35	70%	<b>50 (100%)</b>
Dull grey	9	18%	
Retracted	6	12%	
<b>PTA results</b>			
Normal hearing	35	70%	<b>50 (100%)</b>
Mild hearing loss	15	30%	

Out of the 23 patients treated medically, 13 patients (56.5%) showed clinical improvement and 10 patients (43.5%) showed no change. In the surgically treated group (27 patients), 22 patients (81%) showed good response and 5 cases did not have any improvement. Out of these 5 patients, 2 were from the group of grommet insertion; in the first case, grommet had to be removed due to medialisation of the tube, and the second

case, the grommet was removed due to persistent otorrhoea. Three patients were from the myringotomy group. (Fig 5)



#### IV. Discussion

Otitis media with effusion is mainly a disease of childhood. In the present study, out of 50 cases, 27 cases (54%) were in the age group of 5-8 years. In the UK 50% incidence of OME is seen in children aged 5-7 years, while in USA, a higher incidence in the range of 53% - 61% in children between 2 and 6 years of age have been reported [6]. Male preponderance is noted in OME. In the present study, the males were affected more than females at the ratio of 3:2 (30 males and 20 females). Lee et al. in the study of 51 patients reported that 33 patients were males and 18 patients were females [4]. In a study by Khan et al out of 87 patients suffering from OME, 58 (66.6%) were males and 29 (33.3%) were females and majority of the patients, 54 (62%) cases were between 5-8 years of age [7].

Hearing loss of conductive type is the dominant symptom in the present study. All the patients complained of hearing loss in 18 cases (36%) associated with tinnitus and in 9 (18%) it was associated with otalgia. Nasal obstruction is the second commonest symptom (18 cases) followed by neck nodes (8 cases) and sore throat (7 cases). A study by Reddy V showed that hearing loss was the presenting symptom in 74% of the cases, nasal obstruction in 38% and neck swelling in 8% of the cases [8]. Bilateral involvement is more common than the unilateral involvement in OME. In the present study, bilateral involvement was seen in 36 cases (72%). A similar finding was also reported by Khan et al. with 65.5% of the cases affecting both ears [7]. In the present study, the TM was found to be dull opaque in 54% of the cases and retracted in 30% of the cases. Middle ear fluid was seen in 16% of the cases. The present study is also similar to a study by Reddy V where he found dull grey and retracted TM to be the most common otoscopic finding [8].

In OME, deafness is of conductive type and the degree of hearing loss ranges from mild to moderate. In the present study, majority of the patients showed mild conductive hearing loss (26-40 dB). 48% of the cases had mild (26-40 dB), 16% of the cases had minimal (16-25 dB) and 36% had moderate (41-55 dB) conductive hearing loss. The findings were different from the finding of Reddy V where he found mild conductive hearing loss in 70% of the cases, minimal in 27% and moderate in only 3% of the cases [8]. A study by Raza et al showed that hearing loss ranged from mild to moderate (25-55 dB) where 50% of cases had 35 dB hearing loss and 10% of the cases having hearing loss exceeding 45 dB [9].

In the present study, Tympanogram of all the patients showed B type curve; bilateral in 72% and unilateral in 28% of the cases. Raza et al showed that tympanometry in 98.6% of the cases showed flat B type of curve [9]. Thus, the flat B type curve in Tympanogram is a consistent finding in OME and is diagnostic of the disease. In our study, out of 27 patients with surgical interventions in the ear, the nature of fluid in the middle ear was thick and viscid in 14 cases (52%), the and serous in 33% and mucoid in 15% of the cases. Khan et al also reported thick and viscid fluid in 86% of the cases and serous fluid in 13% of the cases [7]. Thus, in OME the fluid present in the middle ear is mainly of glue type.

In our present study, 27 cases underwent surgical treatment. Surgical treatment was give to those patients with more severe symptoms and those who are refractory to previous medical treatment. Grommet insertion was done on 18 patients (66.7%) where the effusion was thick and viscid and present in large quantities, myringotomy on 7 patients (26%) having no obvious predisposing factors and the fluid was thin and

serous and adenotonsillectomy in two patients (7.4%) who had recurrent attacks of upper respiratory tract infections. In a study conducted by Khan et al out of 87 patients, 57 patients underwent surgical procedures of which myringotomy alone was done in 12.3% of the patients, tympanostomy tube insertion in 29.8%, adenoidectomy in 17.5%, adenotonsillectomy in 21% and antral lavage in 5.3% [7].

In the present study, patients were followed for a minimum period of 1 year at 3, 6, 9 and 12 months. On otoscopy, TM was normal in 70% of the cases, dull and opaque in 18% and retracted in 12% of the cases. No fluid was present in the middle ear. Out of the 23 patients who underwent medical treatment, 13 (56.5%) showed clinical improvement and 10 patients showed no change. A study by Reddy V showed that out of 256 cases, 58 cases (23%) showed response to medical treatment [8]. Khan et al (2006) showed that 34.5% of the cases had improvement [7]. The rationale for antimicrobial therapy of OME is based on a 30% prevalence of viable bacteria in aspirated effusions and an 80% prevalence of bacterial genomic material [10]. Safak et al in a study found that azithromycin prophylaxis of OME for 12 weeks improved middle ear pressures versus decongestant alone, but the clinical relevance is unclear, and the duration of benefit (if any) beyond the prophylactic period was not studied [11]. Antimicrobial agents are not indicated for initial treatment of sporadic OME, as noted appropriately by the American Academy of Pediatrics and Centers for Disease Control and Prevention [12]. Because of the difficulty in obtaining viral cultures, fewer specific data are available regarding their occurrence in patients with OME. However, respiratory syncytial virus accounts for a majority of the viral infections of the middle ear space [13].

Out of the 27 patients treated surgically, 22 patients (81%) showed good response and 5 patients did not show any improvement. Out of this 5 cases, 2 were from the group of Grommet insertion; in one case repeat myringotomy had to be done as the Grommet was displaced medially into the middle ear cavity and in the other case the tube had to be removed due to infection and persistent otorrhoea. Kumar et al. in a study reported medial displacement of tube in 3 cases [14]. Khan et al reported no recurrence in the tympanostomy group but infection of the middle ear with otorrhoea occurred in 6.1% of the cases [7].

Those cases that underwent myringotomy showed immediate improvement in hearing but for a shorter duration as the incision healed rapidly and 3 patients (42%) showed recurrence with residual hearing loss. Shahedin et al showed similar results that 42.8% of myringotomy showed recurrence [15]. The beneficial effect of adenotonsillectomy could be due to reduction of bacterial reservoir, ascending and relieving obstruction of the nasopharyngeal end of Eustachian tube leading to better ventilation. In our study, there was no recurrence of effusion in the two patients who underwent adenotonsillectomy. Khan et al also showed that there was no recurrence in their group where tonsillectomy was done [7]. Gates demonstrated greater long-term efficacy in the treatment of OME in children 4 to 6 years of age when adenoidectomy was added to tympanostomy tube placement or myringotomies even if this was the first surgical intervention in a child [16]. Paradise et al on the other hand, recommend adenoidectomy only if a child fails initial tympanostomy tube placement [17]. From these findings, it is clear that surgical treatment is more effective than the medical treatment for OME.

## V. Conclusion

OME is more prevalent in the young age group. Conductive hearing loss is the main symptom of the disease which can range from mild to moderate degree (26-55 dB). Flat B type Tympanogram is a consistent finding in OME and is diagnostic of the disease. Medical and surgical treatments are employed in the management of OME. Surgical treatment is preferred in those cases refractory to medical therapy. Grommet insertion is the most reliable technique with the least recurrences. However, persistent otorrhoea is a common complication of Grommet insertion. Early diagnosis and timely intervention are important as the disease tends to persist from months to years leading to multiple hospital visits, which in turn leads to loss of school days for the children and undue apprehension of the parents.

## References

- [1]. Merchant SN and Rosowski JJ: Auditory physiology, Glasscock-Shambaugh Surgery of the Ear, BC Decker: Elsevier, Ontario, 5<sup>th</sup> Edition, 59-82, 2005.
- [2]. Casselbrant ML, Brostoff LM, Flaherty MR, Bluestone CD, Cantelkin EI, Doyle WJ and Fria TJ: Otitis media with effusion in pre-school children, *Laryngoscope*; 95: 428-436, 1985.
- [3]. Maw RA: Otitis media with effusion, Scott-Brown Paediatric otolaryngology, Alan G Kerr: Butterworth-Heinemann, London, 6<sup>th</sup> Edition, 6/7/1-23, 1997.
- [4]. Lee DH and Yeo SW: Clinical diagnostic accuracy of otitis media with effusion in children, and significance of myringotomy: Diagnostic or Therapeutic? *J Korean Med Sci*; 19: 739-743, 2004.
- [5]. Deka RC: Middle ear effusion on children, *Indian Journal of Otolaryngology*: Vol. 2, No. 1: 1-3, 1996.
- [6]. Moller P and Dingsor G: Otitis media with effusion, *Journal of Laryngology*; 104: 200-202, 1990.
- [7]. Khan F, Asif M, Farooqi GH, Shah SA, Sayed T and Ghani R: Management outcome of secretory otitis media, *J. Ayub Med Coll*; 18 (1): 6-10, 2006.
- [8]. Reddy V: Secretory otitis media, *Indian Journal of Otolaryngology*; Vol. 4, No. 4: 157-160, 1998.
- [9]. Raza M, Jilil J, Shafique M and Ghafoor T: Frequency of otitis media with effusion in recurrent URTI in children, *Journal of the College of Physicians and Surgeons Pakistan*; Vol. 18 (4): 226-229, 2008.

- [10]. Hendolin PH, Markkanen A, Ylikoski J, Wahlfors JJ. Use of multiplex PCR for simultaneous detection of four bacterial species in middle ear effusions. *J Clin Microbiol* 1997; 35:2854–8.
- [11]. Safak MA, Kilic R, Haberal I, et al. A comparative study of azithromycin and pseudoephedrine hydrochloride for otitis media with effusion in children. *Acta Otolaryngol (Stockh)* 2001; 121:925–9.
- [12]. Dowell SF, Marcy M, Phillips WR, et al. Otitis media—principles of judicious use of antimicrobial agents. *Pediatrics* 1998; 101Suppl:165–71.
- [13]. Mein JO, Teele DW. Isolation of viruses and mycoplasmas from middle ear effusions: A review. *Ann Otol Rhinol Laryngol* 1976; 85 Suppl 25:140–4.
- [14]. Kumar M, Khan MA and Davis S: Medial displacement of grommets, an unusual sequel of grommet insertion, *J Laryngol & Otol*; 114: 448-449, 2000.
- [15]. Shahedin , Raza A , Khan N S, Sattar F, Jan A. Management of secretory otitis media in children *JPMI* 2005;19 ((01): 106-110.
- [16]. Gates GA. Adenoidectomy for otitis media with effusion. *Ann Otol Rhinol Laryngol* 1994; 103:54–8.
- [17]. Paradise JL, Bluestone CD, Rogers KD. Efficacy of adenoidectomy for recurrent otitis media: results from parallel random and non random trials. *PediatrRes* 1987; 21:286–91.

\*Nicola C Lyngdoh. "A Study on the Clinical Profile and Treatment Modalities of Otitis Media with Effusion." *IOSR Journal of Dental and Medical Sciences (IOSR-JDMS)* 16.7 (2017): 60-66.