

Study of Anatomical Variation of The Segmental Branches of Splenic Artery in The Population of Jharkhand

*Dr Meet Krishna¹, Dr Sukhdeo Oraon², Dr Narendra Thakur³
Junior Resident^{1,2}, Professor³
Department Of Anatomy, Rajendra Institute Of Medical Science, Ranchi, Jharkhand
Corresponding author: *Dr Meet Krishna

Abstract

Introduction : The blood supply to spleen is made by a splenic artery which is the largest branch of the celiac trunk and its course is among the most tortuous in the body. The splenic artery lies anterior to the left kidney and left suprarenal gland and runs in the lienorenal ligament posterior to the tail of pancreas. It divides into two or three terminal branches before entering the hilum of spleen. These terminal branches are named as the superior, middle, and the inferior primary or lobar branches.

Material and Methods : 15 human spleens were taken from the cadavers. The distance from the point of primary division of splenic artery to the point of hilum was measured. Any variation in the form of number of lobar branches if present was noted.

Observations: In the present study 73.3% cadavers belonged to males and 26.6% cadavers were of females. Male and female ratio was almost 3:1. The source of origin of Splenic artery was from celiac trunk in 100% cases. The supr-apancreatic course was seen in 93.33% and intrapancreatic course seen in 6.66% cases.

Conclusion : knowledge of variational anatomy of the splenic artery and its branches is indispensable to the Surgeon in Splenectomy, resection of tumours, extirpation of cyst.

Keywords: Splenic artery, Cadaver, lobar branch

I. Introduction

The blood supply to spleen is made by a splenic artery which is the largest branch of the coeliac trunk and its course is among the most tortuous in the body. The splenic artery lies anterior to the left kidney and left suprarenal gland and runs in the lienorenal ligament posterior to the tail of pancreas. The splenic artery divides into two or three main branches or lobar branches before entering the hilum of spleen. These branches enter the hilum and they divide further into four or five segmental arteries. In some cases the splenic artery itself or its primary branch gives an artery which does not pierce the hilum, but goes to one of the poles of the spleen. It can be named as the superior or the inferior polar branch. Now a days partial splenectomy is preferred over total splenectomy after splenic injury. During partial splenectomy, segmental branches of affected segment is ligated. The aim of the present study is to see the branching pattern of the splenic artery in the human cadaveric spleen. knowledge of the variational anatomy of the splenic artery and its branches will be of immense help for the Surgeons performing various surgical procedures.

II. Methodology

The present work entitled “Study of Anatomical variation of the Segmental branches of Splenic artery in the population of Jharkhand” was carried out in the Department of Anatomy, RIMS, Ranchi, Jharkhand with following aims and objectives :

- 1) To measure the length of splenic artery and its branches supplying the spleen till they enter the hilum.
- 2) To note the origin and course of the splenic artery.
- 3) To study the main segmental branch.
- 4) To note type of branching pattern of the splenic artery and occurrence of polar artery.

The present study was done on 15 embalmed cadavers of both sexes, during routine dissections for undergraduates in the Department of Anatomy, RIMS Ranchi for a period of one and half year. The abdomen region was dissected. The splenic artery was identified, its origin and course were observed for variations. Then digital photographs were taken. With the help of instruments the peritoneal cavity was opened in routine cadaveric dissection followed by the standard method of dissection described by Cunningham. The greater omentum and stomach were identified. To the lesser curvature of stomach, lesser omentum is attached. The free margin of greater omentum was identified. The anterior layer of greater omentum is stripped off by

blunt dissection to visualize the artery. Meticulous dissection was done to separate the celiac trunk from its surrounding dense nerve plexus. The splenic artery was identified which was arising from celiac trunk in all the cases. The artery was traced down from its origin till its branches enter in to the hilum of spleen. The artery was separated from the pancreas, adjacent structures and ligaments for the clear view. All other branches of splenic artery were identified which were cut and separated. Splenic artery & its branches supplying spleen were dissected neatly, traced till the hilum and measured with the digital vernier calliper. Digital photographs were taken for the record.

To remove the spleens from the abdominal cavity, they were detached from their various attachments and the splenic vessels were cut, a minimum of 5 cm away from the hilum of the spleen. Each spleen was dissected carefully along the course of the branches of the splenic artery by a piece meal dissection. The total number of the primary and the polar branches of the splenic artery was noted. Any variations in the form of the number of segmental branches of the splenic artery, if they were present between the branches of the splenic artery, were noted. Digital photographs were taken for the record. All 15 cadavers were studied in detail in similar manner. The data collected were analysed and statistically studied. Following points have been observed during the dissection :- Gender, Origin of Splenic artery, Course of Splenic artery and Occurance of Polar artery, Measurement of length of Splenic artery and its branches, Branching pattern of the splenic artery.

III. Results

Table 1 Showing Sex Distribution Of Cadavers

Gender	FREQUENCY	%
Male	11	73.3%
Female	04	26.6%
Total	15	100%

In the present study 73.3% cadavers belonged to males and 26.6% cadavers were of females. Male and female ratio was almost 3:1 .

Table 2 Showing Origin Of Splenic Artery

Entity	Percentage
Origin Of Splenic Artery From Coeliac Trunk	15 (100%)

The source of origin of Splenic artery was from celiac trunk in 100% cases.

Table 3 Showing Course Of Splenic Artery

SL. NO.	ENTITY	PERCENTAGE
1.	Suprapancreatic course of splenic artery	14(93.33%)
2.	Retropancreatic course of splenic artery	0(0%)
3.	Intrapancreatic course of splenic artery	1(6.66%)

The supr-apancreatic course was seen in 93.33% and intrapancreatic course seen in 6.66% cases.

Table 4 Showing Occurance Of Polar Arteries

Sl. No.	Entity	Percentage Of Occurance
1.	Superior Polar Artery Alone	1(6.66%)
2.	Inferior Polar Artery Alone	0(0%)
3.	Both Superior And Inferior Polar Arteries	1(6.66%)
4.	Specimens Without Superior And Inferior Polar Arteries.	13(86.66%)

In 6.66% cases the superior polar artery was seen and in 6.66% cases there were both superior and inferior polar arteries.

Table 5 Showing The Length Of Splenic Artery Trunk, Lobar Artery, Segmental Artery

Arterial Tree	Mean Length(cms)	Range(cms)
Splenic artery Trunk	7.83	5.5-9.5
Lobar artery	2.49	0.6-5.2
Segmental artery	1.69	0.1-5.2

When the length of splenic artery trunk, lobar artery and segmental artery were measured, the following finding were observed :-

Mean length of splenic artery was 7.83 cms and range 5.5-9.5 cms. Mean length of the lobar artery was 2.49 cms and range 0.6-5.2 cms. Mean length of segmental artery was 1.69 cms and range 0.1-5.2 cms.

Table 6 Showing The Division Pattern Splenic Artery

Arterial Tree	No Bifurcation(%)	Bifurcation(%)	Trifurcation(%)	Quadrifurcation(%)
Trunk	Nil(0%)	15(100%)	Nil(0%)	Nil(0%)

The Splenic artery trunk was bifurcated in 100% cases.

Table 7 Showing The Division Pattern Of Lobar Arteries

SL.NO.	Arterial Tree	No Bifurcation(%)	Bifurcation(%)	Trifurcation(%)	Quadrifurcation(%)
1.	Upper Lobar artery	1(6.66%)	8(53.33%)	5(33.33%)	1(6.66%)
2.	Lower Lobar artery	2(13.33%)	9(60%)	4(26.66%)	0(0%)

The upper lobar artery was bifurcated in 53.33% cases, trifurcated in 33.33% cases, quadrifurcated in 6.6% cases and no branching was observed in 6.66% cases.

The lower lobar artery was bifurcated in 60% cases, trifurcated in 26.66% cases and no branching was observed in 13% cases.

Table 8 Showing Percentage Of Occurance Of The Segmental Arteries

SL. NO.	No. Segmental arteries	Total no. of Specimen(n=15)
1.	2SA	1(6.66%)
2.	4SA	7(46.66%)
3.	5SA	4(26.66)
4.	6SA	3(20%)

In 6.66% cadavers only 2 segmental arteries were present. In 46.66% cadavers 4 segmental arteries were supplying the spleen. In 26.66% cadavers were showing 5 segmental arteries and in 20% cadavers there were 6 segmental arteries in total.

IV. Discussion

The vascular architecture of the spleen was presented in detail by Assolent in 1802. Variation of arterial anatomy is very common and occurs in nearly half of the population. Knowledge of variation in origin, course and branching pattern of splenic artery is important for safe execution of Splenectomy. In most of the cases splenic artery originated from coeliac trunk. The other site of origin includes hepato-splenic trunk, abdominal aorta, spleno-gastric trunk and superior mesenteric artery. In addition to the variability in origin of splenic artery, its course can also follow diverse course. It can be suprapancreatic, retropancreatic, intrapancreatic or anteroppancreatic course. Anatomical variations involving the splenic artery are common and the knowledge becomes important in patients undergoing diagnostic laproscopic procedures and upper abdominal surgeries and radiological investigations which can lead to vulnerable iatrogenic surgery. Hence, it is important for the surgeon to appreciate the basic anatomical facts and have a sound knowledge of the anatomical variations of the splenic artery thereby minimising the chance of complication during splenectomy and other upper abdominal surgery.

In some cases the splenic artery itself or its primary branch gives an artery which does not pierce the hilum, but goes to one of the poles of the spleen. It can be named as the superior or the inferior polar branch. These branches supply a particular part of the spleen which is separated by an avascular area. These branches divide the spleen into definite arterial segments. Precise knowledge polar arteries is very important because now a days, during surgery, surgeons try to remove only affected tissue. Findings reported by various studies will be helpful to surgeons while performing surgical procedures on spleen. The splenic artery divides into two or three main branches or lobar branches before entering the hilum of spleen. These branches enter the hilum and they divide further into four or five segmental arteries. These vessels each supply a segment of the splenic tissue and these segments are separated by a definite avascular plane. The architecture of these segments and the avascular planes between them are very variable. During the partial splenectomy, a particular segmental branch of the injured tissue is ligated. So, precise knowledge of the segmental branches of the splenic artery is essential while performing splenectomy. The conservative splenic surgery requires a detailed knowledge of avascular plane of the spleen and segmental terminal vascularization of the spleen

Origin of splenic artery :

Lipshutz(1917) gave a detailed account on splenic artery based on origin and classified into 4 types :-

Type 1: (75% cases) The splenic artery, left gastric artery and common hepatic artery originated from the celiac trunk.

Type 2: (15% cases) The splenic artery arose from hepato-splenic trunk.

Type 3: (6% cases) The splenic artery took origin from abdominal aorta.

Type 4: (4% cases) The splenic artery was originating from the spleno-gastric trunk.

Prakash et al (2012) have observed that in 86% of cases the left gastric, common hepatic and splenic arteries were found to arise from the celiac trunk. In 4% of cases, the splenic artery were arising from the hepato- splenic trunk, in the rest 2% of cases the common hepatic and left gastric arteries arose from the celiac trunk, and the splenic artery arising directly from the abdominal aorta.

D. Nagajyothi et al(2016) on their study reported that the splenic artery originated from the coeliac trunk in 49 cadavers (98%). The splenic artery arose along with common hepatic artery as hepato-splenic trunk from celiac trunk in 1 cadaver (2%). Oh E et al on their study on 159 samples found that vascular variant Independent origin of the splenic arteries from abdominal aorta was seen in approximately 1% of abdominal CT examinations. Remaining 99% of cases took origin from Coeliac trunk. Severino Aires Araujo Neto et al on their study on 60 cases based on CT scan finding revealed that Splenic artery not arised independently from celiac trunk but arised from hepatosplenic trunk which in turn arised from abdominal aorta in 8.3% cases. Pandey et al(2004), have reported the origin of splenic artery from celiac trunk in 90.6% of cases. Independent or direct origin of splenic artery from abdominal aorta is rare (1%) .Naveen Kumar et al(2014) on their extensive study on course of splenic artery reported that, in majority of the cases it took origin from celiac trunk (90.6%). Rarely, it took origin from abdominal aorta (8.1%) and from other sites (1.3%) In present study the source of origin of splenic artery was exclusively from coeliac trunk in 100% cases.

Table 9 comparison of origin of splenic artery with other studies :

SL. NO.	STUDIES	Source of origin					
		Coeliac trunk	ABA	HST	SGT	SMA	Other sites
1.	Lipshutz	75%	6%	15%	4%	--	--
2.	Prakash et al	86%	--	4%	--	--	10%
3.	D. Nagajyoti	98%	--	2%	--	--	--
4.	Oh et al	99%	1%	--	--	--	--
5.	Pandey et al	90.6%	1%	--	--	--	8.4%
6.	Naveen kr et al	90.6%	8.1%	--	--	--	1.3%
7.	Present study	100%	--	--	--	--	--

Course of Splenic artery:

study conducted by ashoka et al (2010) revealed that Splenic artery has shown supra pancreatic course in 68% and retro pancreatic course in 32% of specimens. Pandey S K et al(2004) have found supra pancreatic course in 74.1%, intrapancreatic course in 4.6%, anteropaneatic course in 18.5%, and retropancreatic course in 2.8% tudy done by Gangadhara et al(2014) splenic artery has shown supra pancreatic course in 63.3% (19 specimens) and retro pancreatic course in 36.3% (11 specimens) of specimens. Sindel et al(2001), also reported that after its origin as splenic artery from celiac trunk it took suprapancreatic, enteropancreatic, intrapancreatic or retropancreatic course. Out of which suprapancreatic course was commonest (74.1%) and retropancreatic course was rarest (2.8%). In present study the most common course of splenic artery was suprapancreatic in 93.33% cases. This was followed by intrapancreatic course in 6.66% cases ,which ran within the Pancreatic parenchyma.

Table 10 comparison of course of splenic artery with other studies :

SL. NO.	Studies	SPC	RPC	IPC	APC
1.	Ashoka et al	68%	32%	--	--
2.	Pandey S K et al	74.1%	2.8%	4.6%	18.5%
3.	Gangadhara et al	63.3%	36.3%	--	--
4.	Sindel et al	74.1%	2.8%	--	--
5.	Present study	99.33%	--	6.66%	--

Occurance of Polar artery :

Mikhail Y. et al(1979) reported polar branches, in 12% upper polar, in 50% lower polar and in 12% both upper and lower polar branches . Remaining 26% specimen had no polar artery. Shashikala R. Londhe(2013) on her study observed that superior polar arteries in 33%, inferior polar arteries in 54% and both polar arteries in 12.4%. Polar arteries were originate from splenic trunk. Garcia JA(1988) observed superior polar arteries in 28.28%, inferior polar arteries in 44.75% and both polar arteries in 10.49% of cases. Remaining 16.48% specimen had no polar artery. According to Prashant NC et al(2012) on the basis of his study the superior polar branch was present in 28.82 % specimens, the inferior polar branch was present in 42.34 % specimens, both the superior and inferior branches were present in 11.71% specimens and no polar branch was observed in 17.11% of the total spleens. Gangadhara et al(2014) have found that 26.6 % specimens showed only superior polar artery, 36.6 % specimens showed only inferior polar artery, 16.6 % specimens showed both polar arteries and 20 % specimens had no polar artery . The present study showed that superior polar artery was in 6.66% of cases . In 6.66 % of cases showed both superior and inferior polar arteries and 86 % of cases showed no polar artery.

Table 11 Comparision Of Occurance Of Polar Artery With Other Studies

SL. NO.	STUDIES	SPA	IPA	Both Polar arteries	No polar arteries
1.	Mikhail Y. et al	12%	50%	12%	26%
2.	Shashikala R. Londhe	33%	54%	12.4%	--
3.	Garcia JA	28.28%	44.75%	10.49%	16.48%
4.	Prashant NC et al	28.82%	42.34%	11.71%	17.1%
5.	Gangadhara et al	26.6%	36.6%	16.6%	20.6%
6.	Present study	6.66%	--	6.66%	86%

Length of Splenic artery and its branches :

Gangadhara et al(2014) have found on their study that the Mean length of splenic artery was 7.45 cms and range 2-11 cms. Mean length of the lobar artery was 3.24 cms and range 1.2 – 8 cms. Mean length of segmental artery was 1.21 cms and range 0.4-3 cms. Ashoka et al(2010) have found the length of splenic artery < 8cms- 10%, 8.1-9cms – 34%, 9.1-10cms – 44%, 10.1- 11cms – 06%, >11.1 cms- 06% of specimens. Jauregui E et al(1999) have mentioned the average length of the splenic artery is 10.6 cm. Alim A et al(2014) have found on their study that the distance between the splenic artery (before giving its lobar branches) and the hilum of the spleen were found 2.99±0.73 cm(in group A, Age 15 – 29 years) 3.79 ±1.43 cm(in groupB, Age 30 – 49 years) and 3.51±1.66 cm (in group C, Age 50 – 69 years) respectively. The present study showed Mean length of splenic artery was 7.83 cm and range 5.5-9.5 cm. Mean length of the lobar artery was 2.49 cm and range 0.6-5.2 cm. Mean length of segmental artery was 1.69 cm and range 0.1-5.2 cm.

Pattern of the division of splenic artery Trunk

1. Daisy Sahni et al(2003) have found on their study that in 90% specimens, the splenic artery was bifurcated into two primary or lobar branches and in 10% specimen trifurcated into three primary or lobar branches.
2. Karl H Truetner et al(1993) observed that splenic artery in 93.8% of cases bifurcated into into two primary branches and in 6.2% cases trifurcated into three primary branches.
3. Katritsis E et al(1982) stated that splenic artery was divided into two primary splenic branches in 85.7 % of the specimens, and into three primary splenic branches in 14.3% of the specimens.
4. Gangadhara et al(2014) et al have observed on their study that splenic artery trunk was bifurcated in 80% specimens, trifurcated in 16.66% specimens and quadrifurcated in 3.3% specimen.
5. The present study shows bifurcation of splenic artery into two primary branches in 100% cases.

Table 12 comparison of pattern of division of the splenic artery trunk with other studies :

SL. NO.	STUDIES	Bifurcation	Trifurcation	Quadrifurcation
1.	Daisy Sahni et al	90%	10%	
2.	Karl H Truetner et al	93.8%	6.2%	
3.	Katritsis E et al	85.7%	14.3%	
4.	Gangadhara et al	80%	16.66%	3.33%
5.	present study	100%		

Occurance of Segmental artery :

Gangadhara et al(2014) on their study have observed that in 3.3% cases only 2 segmental arteries were present. In 60% cases they found 4 segmental arteries supplying the spleen. In 20% cases they found 5 segmental arteries in total. In 13.3% cases they found 6 segmental arteries and in only 3.3% cases they found

7 segmental arteries. Prashant Nashiket Chaware et al(2012) on their study observed that two segmental branches were found in 14.51% specimens, three were found in 60.66% specimens, four were found in 19.13% specimens and five segmental branches were present in 5.7% of the total spleens.

The present study showed 2 segmental arteries in 6.66% cases. In 46.66% cases we found 4 segmental arteries supplying the spleen. In 26.66% cases we found 5 segmental arteries and in 20% cases we found 6 segmental arteries in total.

Table 13 comparison of occurrence of segmental artery with other studies :

SL. NO.	Studies	No.of Artery	Segmental	Percentage of occurrence
1.	Gangadhara et al	2SA		3.3%
		4SA		60%
		5SA		20%
		6SA		13.3%
		7SA		3.3%
2.	Prashant Nashiket Chaware et al	2SA		14.51%
		3SA		60.66%
		4SA		19.13%
		5SA		5.7%
		6SA		6.66%
3.	present study	2SA		6.66%
		4SA		46.66%
		5SA		26.66%
		6SA		20%

V. Conclusion

The present study was conducted in 15 cadavers in the Department of Anatomy, RIMS, Ranchi, Jharkhand. In all cases the source of origin of Splenic artery was coeliac trunk, i.e. seen in 100% cases. In 93.33% cases the course of splenic artery was suprapancreatic and in 6.66% the course was intrapancreatic, which ran within the Pancreatic parenchyma. In 6.66% of cases the superior polar artery took origin from splenic artery trunk before branching into lobar artery and terminated into the superior pole of spleen. In 6.66% of cases showed both superior and inferior polar arteries, they took origin from splenic artery and supplied both superior and inferior pole of spleen. The Mean length of splenic artery in all cases was 7.83 cms and range 5.5-9.5 cms, Mean length of the lobar artery was 2.49 cms and range 0.6-5.2 cms and Mean length of segmental artery was 1.69 cms and range 0.1-5.2 cms. In all cases the splenic artery bifurcated into two primary or lobar branches, i.e. in 100% cases. The different branching pattern was noted on each lobar artery. The upper lobar artery was bifurcated in 53.33% cadavers (i.e. 2 segmental arteries), trifurcated in 33.33% cadavers (i.e. 3 segmental arteries) and quadrifurcated in 6.6% cadavers (i.e. 4 segmental arteries) and no branching was observed in 1(6.66%) cadaver. The lower lobar artery was bifurcated in 60% cadavers (i.e. 2 segmental arteries), trifurcated in 26.66% cadavers (i.e.3 segmental arteries) and no branching was observed in 13% cadavers. In 6.66% cadavers only 2 segmental arteries were present. In 46.66% cadavers 4 segmental arteries were supplying the spleen. In 26.66% cadavers were showing 5 segmental arteries and in 20% cadavers there were 6 segmental arteries in total.

References

- [1]. Alim A, Nurunnabi ASM, Ara S, Mahbub S, Mohanta LC. Comparative histological study on the spleen of human (Homo sapiens), cow (Bos indicus) and goat (Capra hircus). Nepal Journal of Medical sciences 2012;1(2):64-7.
- [2]. Ashok K R, Kiran T V. study of branching pattern of splenic artery. Int J Anat Res 2016;4(1):2073-2075. DOI: 10.16965/ijar.2016.145
- [3]. Daisy Sahni A, IndarJit B, Gupta CN, Gupta DM, Harjeet E. Branches of the splenic artery and splenic arterial segments. Clin Anat 2003 Sep;16(5):371-7.
- [4]. D. Naga Jyothi, T. V. Ramani, S. Saritha, Gayathri. P. B. Sadananda Rao, Asra Anjum. cadaveric study of variations in branching pattern of splenic artery. Int J Anat Res 2015;3(4):1629-1634. DOI: 10.16965/ijar.2015.284
- [5]. Gangadhara, Rajasekhar P., Hemasankar C. Study on origin, course, branching pattern and morphometry of splenic artery and its branches supplying the spleena
- [6]. cadaveric study. *ijcrr*. 2014; 6(18): 1623.
- [7]. Garcia Porrero J, Lemes A. Arterial segmentation and subsegmentation in human spleen. Acta Anat (Basel) 1988;131(4):276-83.
- [8]. Gray's Anatomy: The anatomical basis of clinical practice 2005,39th Edition Churchill LivingstoneElsevier:1241
- [9]. Jauregui E. Anatomy of splenic artery. Rev Fac Cien Med Univ Nac Cordoba. 1999; 56(1): 21-41.
- [10]. Karl H. Treutner, Bernd Klosterhalfen, Gerd Winkeltau, Sylvia Moench, Volker Schumpelick. Vascular Anatomy of the Spleen: The Basis of Organ –Preserving surgery. Clin Anat. 1993; 6: 1-8.
- [11]. Katritsis And Parashos A, Papadopoulos N. Arterial segmentation of the human spleen by post-mortem angiograms and corrosion-casts. Angiology. 1982; 33 (11): 720-7.
- [12]. Lipschutz B. A composite study of the coeliac artery. Ann Surg 1917;65:159-69.
- [13]. Mikhail Y Kamd, Nawar R, Rafla. Observation on the mode of termination and parenchymal distribution of splenic artery with evidence of splenic lobation and segmentation. J Anat. 1979; 128: 253-258.

- [15]. Naveen Kumar et al Atypical Arterial Supply to the Spleen by Polar Branches of Splenic Artery and Accessory Splenic Artery – A Case Report, J Clin Diagn Res. 2014 Aug; 8(8): AD03–AD04
- [16]. Oh E, Gross BH, Williams DM. Independent origin of the hepatic and splenic arteries from abdominal aorta: CT demonstration. J Comput Assist Tomogr. 1998 Jul-Aug; 22(4): 669-70.
- [17]. Pandey S, Bhattacharya S, Mishra R. and Shukla V. (2004), Anatomical variations of the splenic artery and its clinical implications. Clinical Anatomy, 17: 497-502
- [18]. Prakash, T Rajini, Mokhasi, Geethanjali, PV Sivacharan, M Shashirekha. Celiac trunk and its branches: anatomical variations and clinical implications. Singapore Med J. 2012 May.
- [19]. Shashikala Ramachandra Iondhe. Study of vascular pattern in human spleen. Dissertation submitted to Shivaji University Kolhapur. 2002: 19-22, 34, 35.
- [20]. Sindel M, Sarikcioglu L, Ceken K, Yilmaz S. The importance of anatomy of splenic artery and its branches in splenic artery embolisation. Folia Morphol (Warsz). 2001;60(4):333-6.
- [21]. Severino Aires Araujo Neto et al. Anatomical variations of the celiac trunk and hepatic arterial system: an analysis using multidetector computed tomography angiography Radiol Bras. 2015 Nov/Dez;48(6):358–362.
- [22]. Sinnatamby CS. Spleen. Last's anatomy regional and applied: 10th edn. Churchill Livingstone. Edinburgh 1999;264-5.

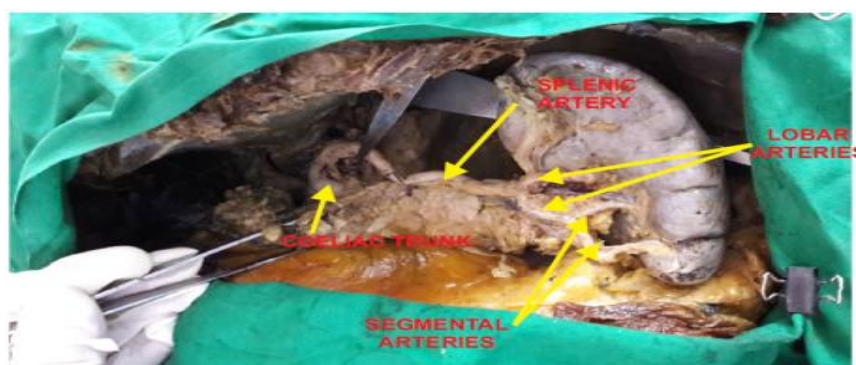


Fig. 01: Bifurcation of splenic artery

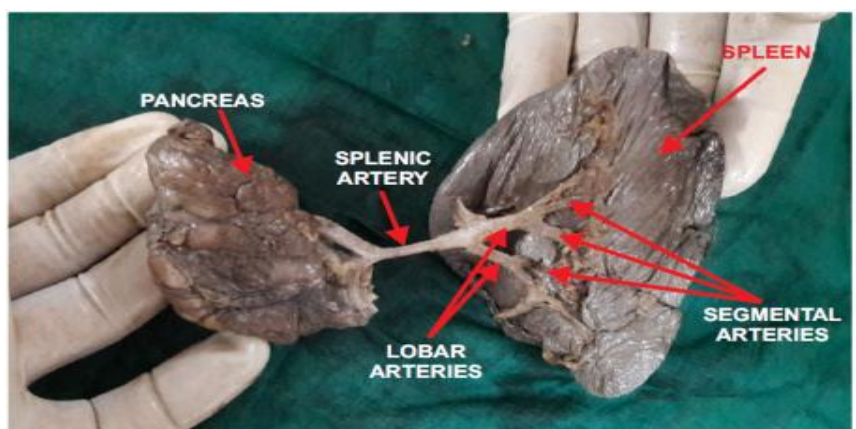


Fig. 02: Segmental branches of lobar artery

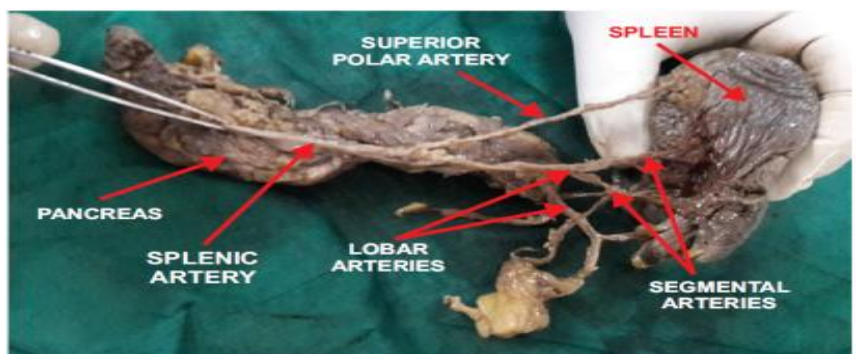


Fig. 03: Superior polar artery from splenic artery trunk

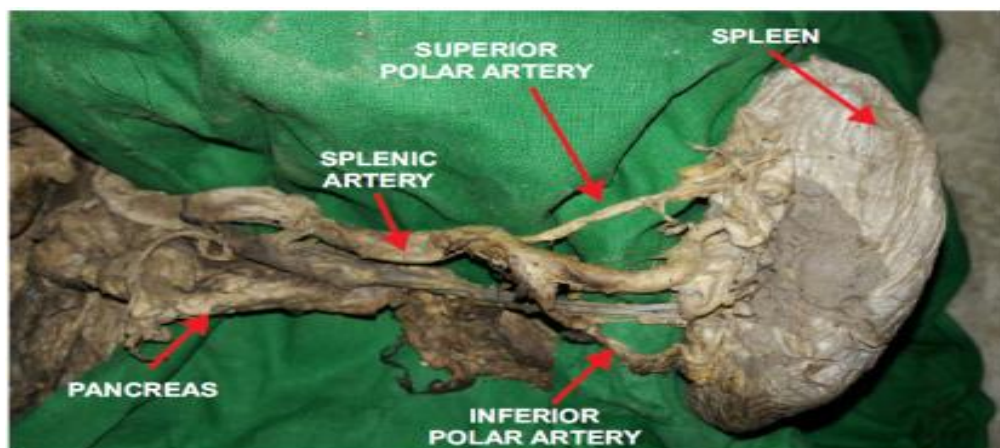


Fig. 04: Superior & Inferior Polar Arteries From Splenic Artery Trunk

*Dr Meet Krishna. "Study of Anatomical Variation of The Segmental Branches of Splenic Artery in The Population of Jharkhand." IOSR Journal of Dental and Medical Sciences (IOSR-JDMS) 16.7 (2017): 34-41.