

## Evaluation And Comparison of The Relationship of Condyle And Mandibular Fossa In Patients with Class I, Class II Division I And Class III Malocclusion: A Cone Beam Computed Tomography Study

\*Dr. Gayathri Ganesh<sup>1</sup>, Dr. Uma Maheswari.R<sup>2</sup>, Dr. Devaki Vijayalakshmi.R<sup>3</sup>,  
Dr. Nagachandran.K.S<sup>4</sup>, Dr. Ratna Rachel Ponraj<sup>5</sup>

<sup>1</sup>(MDS, Department of Orthodontics and Dentofacial Orthopedics, Meenakshi Ammal Dental College, Chennai, India.)

<sup>2</sup>(MDS, Professor, Department of Orthodontics and Dentofacial Orthopedics, Meenakshi Ammal Dental College, Chennai, India.)

<sup>3</sup>(MDS, Professor, Department of Orthodontics and Dentofacial Orthopedics, Meenakshi Ammal Dental College, Chennai, India.)

<sup>4</sup>(MDS, Reader, Department of Orthodontics and Dentofacial Orthopedics, Meenakshi Ammal Dental College, Chennai, India.)

<sup>5</sup>(MDS, Senior lecturer, Department of Orthodontics and Dentofacial Orthopedics, Meenakshi Ammal Dental College, Chennai, India.)

\*Corresponding author: \*Dr. Gayathri Ganesh

---

### ABSTRACT: -

**Aim:** The purpose of this study was to compare and evaluate the condyle-mandibular fossa relationship among patients with skeletal Class I, Class II Division 1 and Class III malocclusion prior to orthodontic treatment using Cone Beam Computed Tomography.

**Materials and methods:** The study included 45 patients with Skeletal Class I (group-1), Class II Division I (group-2) and Class III malocclusions (group-3), 15 subjects each ranging in age from 15 to 40 years, underwent CBCT imaging of the temporomandibular joint. The images obtained from the sagittal slice were evaluated for concentric position of condyle in the fossa and also to assess the depth of the mandibular fossa whereas the symmetry between the positions of condylemandibular fossa was assessed on the axial slice.

**Results:** In the Class I group, posterior joint space showed a statistically significant difference between the right and left sides. A significant difference in the depth of the fossa between Class I and Class III malocclusion on the right side was observed.

**Conclusion** – Evaluation of the concentric position of the condyles in their fossa revealed non-concentric position for Class I and concentric position for Class II and Class III groups. Depth of the fossa was higher in Class III subjects than Class I. Distance of condylar process/midsagittal plane showed symmetrical position in all the groups. On the anteroposterior aspect, a higher percentage for left condyle being placed more anteriorly than right condyle was observed among all the groups.

**Keywords:** Cone Beam Computed Tomography, Malocclusion, Temporomandibular joint

---

Date of Submission: 11 -08-2017

Date of acceptance: 23-08-2017

---

### 1. Introduction

The temporomandibular joint (TMJ) is a synovial joint and its condyle and the fossa might differ in shape and their interrelations among people with various malocclusions, and it can be loaded differently in people with diverse dentofacial morphologies<sup>1</sup>. The influence of occlusion on joint morphology is still not completely understood. Two dimensional imaging and articulators have been used to evaluate the condyle and fossa relationships, but they have many disadvantages<sup>5</sup>. Three-dimensional (3D) evaluations, such as computed tomography (CT) have been utilized to evaluate the TMJ because of its high cost, large radiation dosage, large space requirements and the high level of skill required for interpretation have kept its use to a minimum<sup>6</sup>. CBCT machines because of its high resolution multi-planar images, low cost, reduced radiation dose and less time spent during image-acquisition allows examination of TMJ anatomy without superimposition distortion. and provides isotropic submillimeter spatial resolution images with markedly shorter scanning times (10-70 seconds)<sup>9</sup>

The aim of the present study was to evaluate the mandibular condyle position in the fossa with the 3D images acquired using Cone Beam Computed Tomography imaging technique in order to understand better about TMJs in various malocclusions.

## **II. Subjects And Methods**

Forty five patients with Class I, Class II Division I and Class III malocclusions (15 subjects each) ranging in age from 15 to 40 years were selected and they underwent CBCT imaging of the Temporomandibular joint with their consent. The investigation was done to diagnosis and treat the malocclusion. They were divided into group-1 (Class I), group-2 (Class II Division I) and group-3 (Class III).

### **Patient selection criteria**

All permanent teeth erupted, except third molars  
Absence of functional mandibular deviations  
No crossbites, open bites and evident facial asymmetry  
Symptoms of temporomandibular disorders were not considered because most such disorders are related to disc positioning. Both the TMJ's were scanned with the PLANMECA PROMAX Cone-Beam 3D imaging system. The machine is a PROMAX 3D, with the TUBE TYPE: D-054SB-C. Images were obtained with patients in centric occlusion (maximum dental intercuspation), and FH plane positioned parallel to the floor (Fig-1). In this study the jaw size setting were set to average i.e. the volume size for adults was Ø160 X Ø50 mm. Volumes were reconstructed with a 0.4 mm isometric voxel size with tube voltage 90kVp and the tube current 12 mA. The images were set to normal resolution and the average exposure time was 13 seconds. Images were examined with the scanner's proprietary ROMEXIS software function for temporomandibular joint

### **The following measurements were assessed on the sagittal plane.**

- 1.Depth of the mandibular fossa:** Measured from the most superior point of the fossa to the plane formed by the most inferior point of the articular tubercle to the most inferior point of the auditory meatus (Fig-2)<sup>1,10-13</sup>.
- 2. Anterior joint space:** Shortest distance between the most anterior point of the condyle and the posterior wall of the articular tubercle (Fig-3)<sup>1,10-14</sup>.
- 3. Superior joint space:** Shortest distance between the most superior point of the condyle and the most superior point of the mandibular fossa (Fig-3)<sup>1,10-14</sup>
- 4. Posterior joint space:** Shortest distance between the most posterior point of the condyle and the posterior wall of the mandibular fossa (Fig-3)<sup>1,10-13</sup>

### **The following measurements were assessed on the axial plane.**

- 1.The distance between the geometric centers of the condylar processes and the mid-sagittal plane,** measured with a line that passed through the geometric centers of the condylar processes and perpendicular to the mid-sagittal plane i.e., RCP (right condylar position) and LCP (left condylar position)[Fig-4a]<sup>11-13,15</sup>. The antero-posterior difference between the geometric center of the right and left condylar processes as reflected on the mid-sagittal plane [Fig-4b]<sup>11-13,15</sup>.

The sagittal slice is the most appropriate for assessing the condyle-fossa relationship. It allows analysis of the condylar concentricity by comparing the anterior and posterior articular (joint) spaces on the right and left side. The depth of the mandibular fossa can also be determined by this technique<sup>11,12</sup>. The axial slice is most appropriate to assess the symmetry between the condyles in the anteroposterior and mediolateral aspect, because it shows both condyles in the same image and allows the determination of reference planes such as the median sagittal plane<sup>11,12</sup>.

### **The following measurements were assessed on the sagittal plane.**

- 1.Depth of the mandibular fossa:** Measured from the most superior point of the fossa to the plane formed by the most inferior point of the articular tubercle to the most inferior point of the auditory meatus (Fig-2)<sup>1,10-13</sup>.
- 2. Anterior joint space:** Shortest distance between the most anterior point of the condyle and the posterior wall of the articular tubercle (Fig-3)<sup>1,10-14</sup>.
- 3. Superior joint space:** Shortest distance between the most superior point of the condyle and the most superior point of the mandibular fossa (Fig-3)<sup>1,10-14</sup>
- 4. Posterior joint space:** Shortest distance between the most posterior point of the condyle and the posterior wall of the mandibular fossa (Fig-3)<sup>1,10-13</sup>

### **The following measurements were assessed on the axial plane.**

The distance between the geometric centers of the condylar processes and the mid-sagittal plane, measured with a line that passed through the geometric centers of the condylar processes and perpendicular to the mid-sagittal plane i.e., RCP (right condylar position) and LCP (left condylar position)[Fig-4a]<sup>11-13,15</sup>.2. The

antero-posterior difference between the geometric center of the right and left condylar processes as reflected on the mid-sagittal plane [Fig-4b]<sup>11-13,15</sup>.

The sagittal slice is the most appropriate for assessing the condyle-fossa relationship. It allows analysis of the condylar concentricity by comparing the anterior and posterior articular (joint) spaces on the right and left side. The depth of the mandibular fossa can also be determined by this technique<sup>11,12</sup>. The axial slice is most appropriate to assess the symmetry between the condyles in the anteroposterior and mediolateral aspect, because it shows both condyles in the same image and allows the determination of reference planes such as the median sagittal plane<sup>11,12</sup>.

### **III. Statistical Analysis**

The following tests were applied: 1. Independent t test for the comparison between the right and left side TMJ variables for each group i.e., anterior joint space, posterior joint space, superior joint space and depth of the fossa. 2. ANOVA (One-way group analysis of variance) test between the measurements of all the variables (AS, SS, PS, depth, RCP and LCP) on the right side for all groups and also between the measurements of all the same variables on the left side for all groups. Post hoc test for multiple comparisons was done using Tukey HSD test to identify in which variable a difference had occurred. The level of significance was 95% confidence interval for all tests. P-values of less than 0.05 were considered significant. Statistical analysis was done by using SPSS for Windows (version 17.0).

### **IV. Results**

Table I, II & III shows the descriptive statistical analysis of variables between right and left TMJ's within each group. Independent t test was performed to determine the significance within each group. Table IV and V describes comparison of the variables on the right side and left side between each group using one-way ANOVA test. Table VI shows the analysis between RCP (right condylar position) and LCP (left condylar position) in relation to the mid-sagittal plane within each group. Table VII shows the comparison of RCP and LCP between each group using one-way ANOVA test. In Class I group, there was a statistically significant difference ( $P=0.046$ ) between the right and left posterior joint spaces (Table Ia) and the difference between the averages (anterior joint space–posterior joint space) was  $-0.9\text{mm}$  for the right side and  $-0.5\text{mm}$  for the left side (Table Ib). No statistically significant difference was observed for AS, SS or depth of fossa. In Class II group, no statistically significant difference was observed when the mean anterior, superior and depth of the fossa for right and left side was compared (Table II). In Class III group, when the mean of anterior, superior, posterior joint space and depth of the fossa was compared, no statistically significant difference was observed (Table III). Table IV shows the comparison of class I, class II and class III malocclusion of anterior, posterior, superior joint spaces and depth of the fossa on the right side. Based on the comparison between the 3 groups no statistically significant difference was observed.

The ANOVA test between the three groups (Table IV; Graph 2) on the right side revealed a statistically significant difference ( $P=0.031$ ) in the depth of the mandibular fossa between the Class I ( $7.8\pm 1.0\text{mm}$ ) and Class III ( $8.9\pm 1.4\text{mm}$ ) malocclusion with mean difference of  $1.05\text{mm}$ , indicating an increased fossa height in Class III than Class I malocclusion. Table V shows the comparison of the anterior, posterior, superior joint space and the depth of the fossa on the left side in Class I, Class II and Class III malocclusion. No statistically significant difference was observed. Table VI shows the statistical analysis between right condylar and left condylar position in relation to the mid-sagittal plane within each group. No statistically significant difference was observed between RCP and LCP in each group. Table VII shows the statistical analysis comparing the right condylar position and left condylar position between each group using one-way ANOVA test. The mean distance from the geometric centre of the right condylar processes to the mid-sagittal plane in Class I is  $46.6\text{mm}$ ; Class II is  $47.7\text{mm}$ ; Class III is  $47.9\text{mm}$  with the overall P value= $0.296$ . The mean distance from the geometric centre of the left condylar processes to the mid-sagittal plane in Class I is  $47.7\text{mm}$ ; Class II is  $48.2\text{mm}$ ; Class III is  $48.1\text{mm}$  with the overall P value= $0.852$  respectively. No statistically significant was observed.

Graph 5 shows the average difference in position of the condylar processes (right and left) on the anteroposterior aspect as reflected on the mid-sagittal plane. In Class I malocclusion 15.4% of the right side and 61.5% of the left condylar process was displaced anteriorly whereas 23.1% was in neutral position. In Class II malocclusion, 26.3% of the right condylar process and 60.0% of the left condylar process was displaced anteriorly whereas 13.3% was in neutral position. In Class III malocclusion, 7.1% of the right condylar process and 64.3% of the left condylar process was displaced anteriorly whereas 28.6% was in neutral position. Overall 61.9% of the left condylar process was displaced anteriorly when compared to the right condylar process (16.7%) and 21.4% of the condyles were in neutral position.

## **V. Discussion**

Understanding TMJ morphology and its spatial disposition in different malocclusions and the influence of orthodontic treatment on its structures during the stages of human development are still challenging for the orthodontists. According to the literature, the most significant morphologic alterations and positioning asymmetries of TMJ structures are related to absence of teeth, premature occlusal contact points, functional mandibular deviations, unilateral posterior crossbites and dentoskeletal asymmetries. However, earlier study has reported that articular aspects that are characteristic of specific malocclusion were not determined and it was unknown whether a morphologic condition of the condyle or an articular positioning was typical of a specific type of malocclusion<sup>11</sup>.

### **Joint space in Class I, II and III malocclusions:**

In our study, the evaluation of condylar concentricity in Class I malocclusion showed that both sides were characterized by non-concentric positioning of the condyles. In the sagittal slice, a statistically significant difference for posterior joint space, with a smaller left posterior joint space than the right posterior joint space was observed, indicating a more anteriorly positioned condyle on the right side in accordance with the study done by Rodrigues et al<sup>11</sup> and Vitral et al<sup>10</sup>. Lack of condylar centralization was also observed in asymptomatic Class I subjects by Rodrigues et al<sup>14</sup>. Ikeda and Kawamura<sup>18</sup> in a cone beam CT (CBCT) study in functionally optimal joints without disc displacement, found non-centered condyles with the posterior joint space larger than the anterior joint spaces. In our study, the mean value of anterior joint space is similar for both sides and there is a difference only in the posterior joint space, suggesting that it may perhaps be due to variations in the condylar dimensions or in the shape of the mandibular fossa<sup>19</sup>. Also Burley<sup>21</sup> when evaluating the articular structures of the temporal bone in patients with different types of malocclusions (Classes I, II, and III) showed that they do not produce functional stimuli capable of altering the contour of the anterior wall of the mandibular fossa. In Class II malocclusion there is no significant differences for anterior joint space and posterior joint space on the right and left sides, indicating a concentric condylar position in the fossa. Gianelly et al<sup>22</sup> found concentric condylar position in Class II malocclusions characterized by deep bite without overjet which was consistent with the present study and he also found that there was no correlation between bite depth and condylar position.

In Class II malocclusion the mean superior joint space showed a relative difference between the right and left side, but they were not statistically significant. This difference in superior joint space had been reported earlier by Burke et al<sup>23</sup>, in a Class II group in which patients with vertical facial morphologic characteristics had decreased superior joint spaces compared with increased superior joint spaces in patients with horizontal facial patterns. But there was no statistical significance between facial morphology and anteroposterior condyle position. Hence facial morphology was not considered as a factor in the current study. In our study, Class III malocclusion showed no statistically significant difference for the anterior, superior or posterior joint space on the right and left side, which showed concentric condylar position in the fossa. The mean joint space values (AS, SS, PS) given by Kim et al<sup>24</sup> partly correlated with the values of the present study, but no statistically significant difference was observed. Kim and Lee et al<sup>25</sup> found no significant difference in joint spaces in Class III patients with or without asymmetry. So the selection of Class III subjects in the present study included those without apparent asymmetry which indicated a concentric condylar position. Conversely the mean superior joint space in the current study correlated with the mean values of Kim et al<sup>24</sup> indicating a normal vertical position in the fossa. Also according to Hansson et al<sup>27</sup>, joint space was considered normal when the distance between the condylar head and mandibular fossa was between 1.5 mm and 4 mm which suggest that the values for superior joint space in our study as normal.

### **Depth of the Mandibular fossa in different malocclusions:**

The depth of the mandibular fossa in the present study for the Class I malocclusion showed no statistically significant difference for both sides which was in concordance with the study done by Vitral et al<sup>13</sup> and Rodrigues et al<sup>11</sup>. However the mean depth on the right side was comparatively smaller than the fossa depth on the left side. In Class II malocclusion no significant difference for both sides was observed in depth of the mandibular fossa. But the mean depth on the right side was comparatively smaller than the left side. Similar observations were reported by Rodrigues et al<sup>12</sup> in Class II Division I malocclusion. The fossa depth can vary according to disparities in the dimensions of the fossa or asymmetry in the cranial base. The depth of the mandibular fossa did not show any statistically significant difference between right and left sides in the Class III malocclusion which was consistent with the results obtained by Rodrigues et al<sup>12</sup>. Katsavrias and Halazonetis<sup>16</sup> found that the size of the mandibular fossa tends to be larger, wider and shallower in Class III malocclusion and were found to have different fossa shapes than Class II malocclusion.

On comparison between the three malocclusion types, on the right side a significant difference in the depth of the mandibular fossa between the Class I and Class III malocclusion was observed, indicating an increased fossa height in Class III malocclusion than Class I. This difference is probably due to the different severity of malocclusion between the samples. According to Katsavrias and Halazonetis<sup>16</sup>, shape variability of the condyle was mainly related to inclination of the condylar head, inclination of the eminence and in turn related to depth of the fossa. Moreover condyle shape was different in the Class III malocclusion, more elongated and inclined anteriorly compared with the Class II malocclusion. On the axial slice, current study showed no statistically significant differences between the right (RCP) and left (LCP) sides for the mediolateral positioning of the condyles in relation to the mid-sagittal plane for all the malocclusion types, indicating a symmetrical condylar position (CP) on the transverse dimension which is in concordance to the study done by Rodrigues et al<sup>11,12</sup>.

Pullinger et al<sup>3</sup> investigated 74 asymptomatic joints, which represented “normal” population and found the TM joints were 43% concentric, 27% posterior and 30% anteriorly positioned. In the present study, as the sagittal section could not reveal any asymmetric condylar position for Class II Division I and Class III malocclusions<sup>3,10,11,16,19</sup>, the axial slice was assessed to reveal whether the differences in articular spaces are associated with the dimension or the asymmetric positioning of the mandibular fossae as suggested by Rodrigues et al<sup>12</sup>. So to create symmetrical relationships, Ben-Bassat et al confirms that the occlusal features might be associated with TMJ structure remodeling<sup>30</sup>. Cohlmia et al<sup>19</sup> observed that subjects with malocclusions frequently showed non-concentric condylar positioning and mild condyle-fossa relationship asymmetry, in which the left condyle was placed more anteriorly than the right, which correlated with the results in this study.

In general, in the assessment of symmetries between the condyles, the results seem to confirm that occlusal features might be associated with TMJ structure remodeling to create symmetrical relationships, because dimensional and positional symmetries between the condyles are characteristics of different malocclusions<sup>15</sup>. According to several studies, the lack of condyle centralization with anterior joint spaces smaller than posterior joint spaces, was a common finding among the various malocclusions<sup>3,10,11,16,19</sup>. With the advent of CBCT, a precise measurement of the joint space, depth of the fossa, distance from the geometric center of the condyle to the mid-sagittal plane and its bilateral difference can be made. Thus future studies including the articular disc position in relation to glenoid fossa and condyle should be evaluated in different malocclusion which will provide a better understanding of the TMJ complex.

**Tables And Figures**

**Table Ia:** Comparison between right and left TMJ within CLASS-I group

Class I	Right Side	Left Side	Significance (P Value<0.05)
	Mean ± Sd	Mean ± Sd	
Anterior Joint Space (Mm)	1.8 ± 0.4	1.8 ± 0.3	0.776
Superior Joint Space (Mm)	2.8 ± 0.6	2.8 ± 0.7	0.924
Posterior Joint Space (Mm)	2.7 ± 0.5	2.3 ± 0.5	0.046*
Depth Of Fossa (Mm)	7.8 ± 1.0	8.07 ± 1.0	0.530

\*mean difference significant at the .05 level  
SD-Standard deviation

**Table Ib:** Evaluation of concentric position of condyle in Class I group

SIDE (Class I)	Anterior joint space (mm)	Posterior joint space (mm)	Anterior joint space – Posterior joint space (mm)
	Mean ± SD	Mean ± SD	
RIGHT SIDE	1.8 ± 0.4	2.7 ± 0.5	-0.9
LEFT SIDE	1.8 ± 0.3	2.3 ± 0.5	-0.5

**Table II:** Comparison between right and left TMJ within CLASS II group

CLASS II	RIGHT SIDE	LEFT SIDE	SIGNIFICANCE(P value <0.05)	
	Mean ± SD	Mean ± SD		
Anterior joint space (mm)	2.0 ± 0.7	1.9 ± 0.4	0.659	NS

Superior joint space (mm)	3.08 ± 1.1	3.4 ± 0.9	0.384	NS
Posterior joint space (mm)	2.7 ± 0.9	2.6 ± 0.9	0.682	NS
Depth of fossa (mm)	7.9 ± 1.2	8.2 ± 1.1	0.363	NS

NS- Not significant

**Table III:** Comparison between right and left TMJ within CLASS III group

CLASS III	RIGHT SIDE	LEFT SIDE	SIGNIFICANCE (P value <0.05)	
	Mean ± SD	Mean ± SD		
Anterior joint space (mm)	1.8 ± 0.4	1.9 ± 0.5	0.493	NS
Superior joint space (mm)	2.7 ± 0.8	2.8 ± 1.0	0.648	NS
Posterior joint space (mm)	2.6 ± 0.8	2.7 ± 0.8	0.773	NS
Depth of fossa (mm)	8.9 ± 1.4	8.8 ± 1.0	0.838	NS

NS- Not significant

**Table IV:** Comparison between left and right side TMJ in three groups

Parameter	Left side				Right side			
	Class I	Class II	Class III	Significance (ANOVA) (P <0.05)	Class I	Class II	Class III	Significance (ANOVA) (P <0.05)
					Mean ±SD	Mean ±SD	Mean ±SD	
Anterior joint space (mm)	1.8 ± 0.3	1.9 ± 0.4	1.9 ± 0.5	0.571 (NS)	1.8 ± 0.4	2.0 ± 0.7	1.8 ± 0.4	0.439 (NS)
Superior joint space (mm)	2.8 ± 0.7	3.4 ± 0.9	2.8 ± 1.0	0.091 (NS)	2.8 ± 0.6	3.0 ± 1.1	2.7 ± 0.8	0.398 (NS)
Posterior joint space (mm)	2.3 ± 0.5	2.6 ± 0.9	2.7 ± 0.8	0.314 (NS)	2.7 ± 0.5	2.7 ± 0.9	2.6 ± 0.8	0.912 (NS)
Depth of fossa (mm)	8.1 ± 1.0	8.3 ± 1.1	8.8 ± 1.0	0.165 (NS)	7.8 ± 1.0	7.9 ± 1.2	8.9 ± 1.4	0.031* (S)

(\*mean difference significant at the 0.05 level; NS- Not significant)

**Table V:** Comparison between RCP and LCP within each group

Malocclusion	RCP	LCP	SIGNIFICANCE (P value <0.05)
	Mean ± SD	Mean ± SD	
Class I	46.6 ± 2.04	47.7 ± 2.5	0.186 (NS)
Class II	47.7 ± 2.3	48.2 ± 2.6	0.532 (NS)
Class III	47.9 ± 2.7	48.1 ± 2.3	0.810 (NS)

(NS- Not significant)

**Table VI:** Comparison of Condylar position (CP) between three groups

CP	Class I	Class II	Class III	Significance (ANOVA) (P <0.05)
	Mean ± SD	Mean ± SD	Mean ± SD	
RCP	46.6 ± 2.0	47.7 ± 2.3	47.9 ± 2.7	0.296 (NS)
LCP	47.7 ± 2.5	48.2 ± 2.6	48.1 ± 2.3	0.852 (NS)

NS- Not significant

Figures:

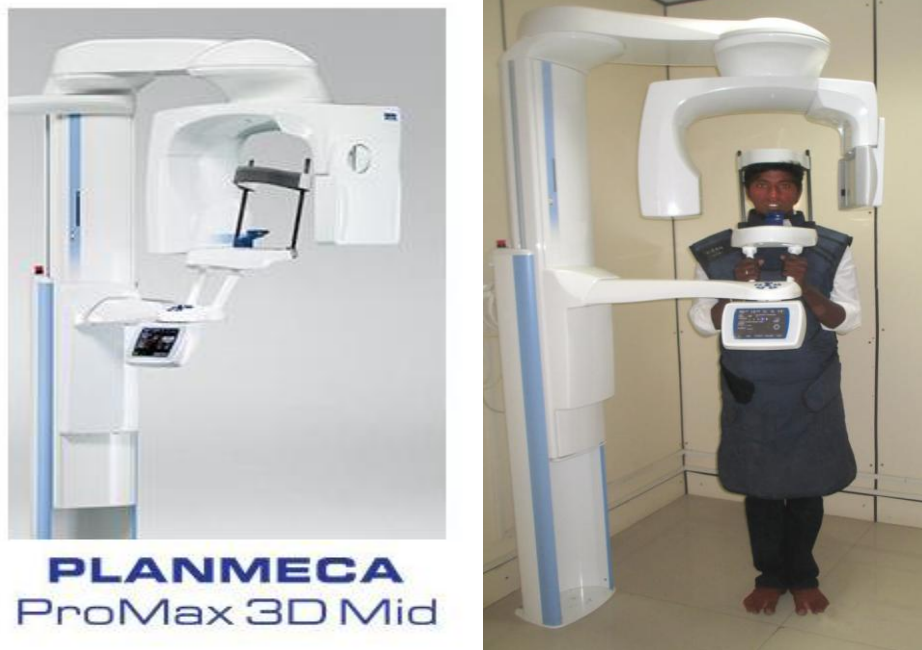

Fig.1a.

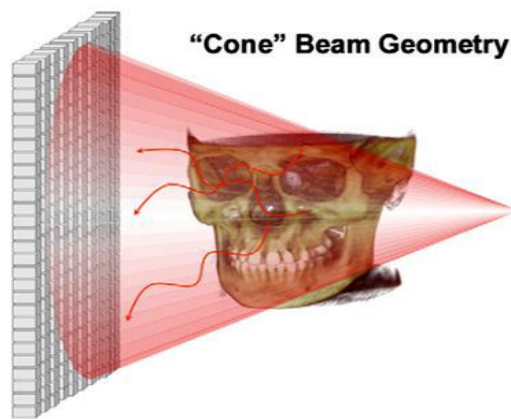
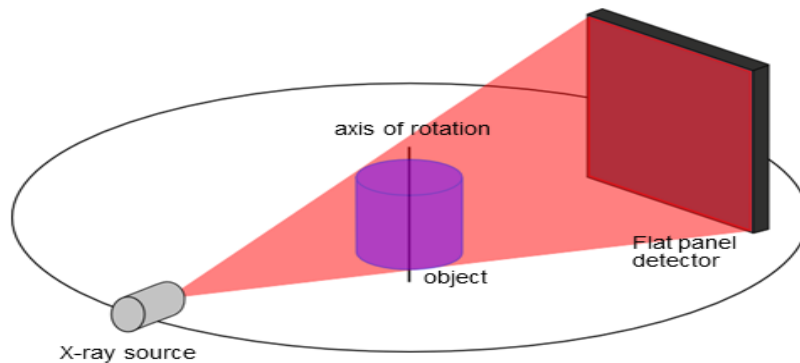


Fig.1b.



Cone beam 3D X-ray device takes the whole 3 dimensional volume with wide conical beam in one scan instead of many slices with many scans.

Fig 1c.

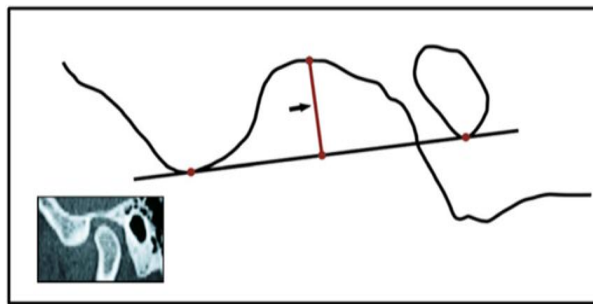


Fig 2 -Depth of the Mandibular Fossa

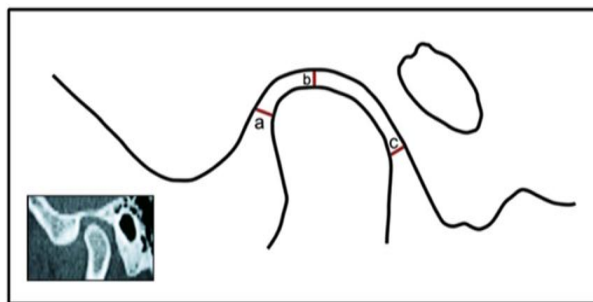


Fig 3- a, Anterior joint space; b, Superior joint space; c, Posterior joint space.

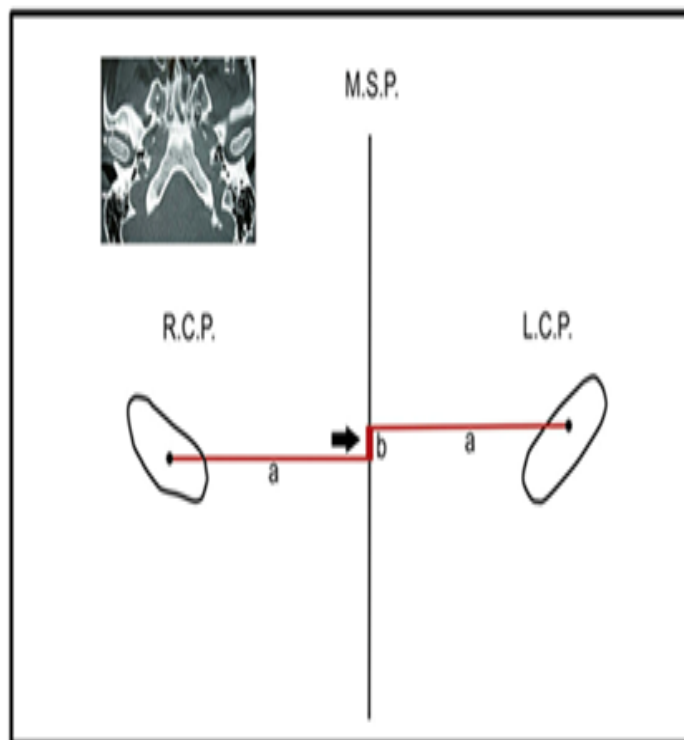
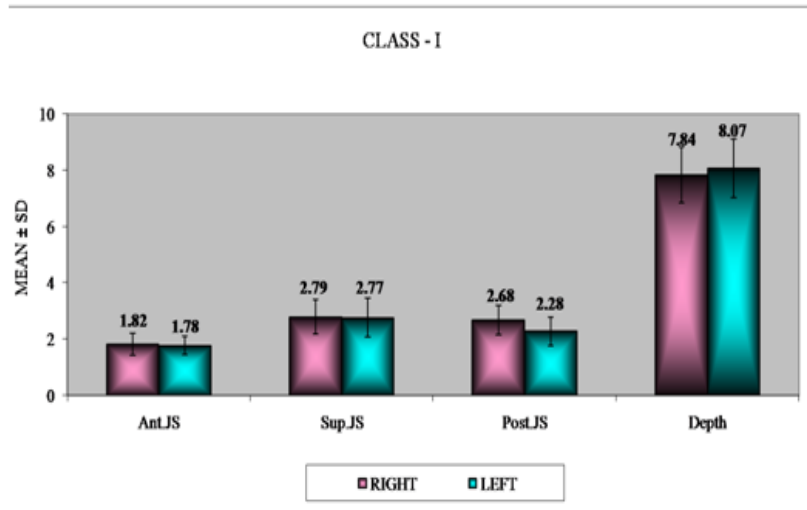
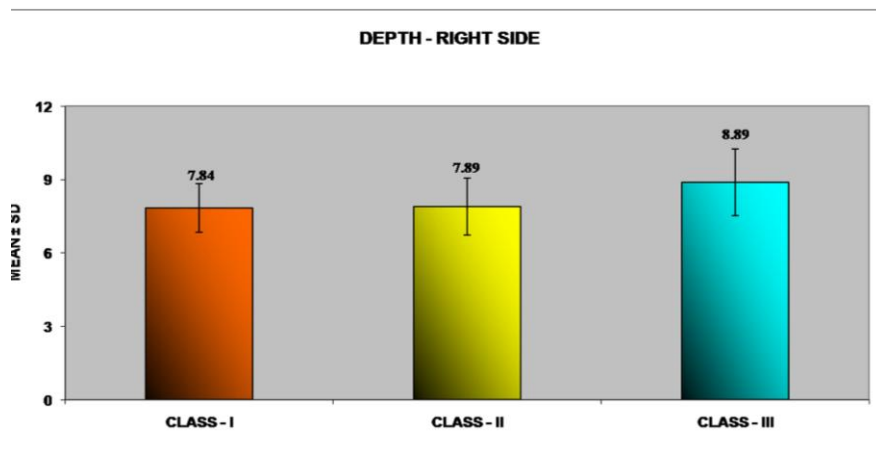


Fig 4- 'a' measures the distance between the geometric center of the condylar processes to the midsagittal plane and 'b' measures the difference in distance between the condylar processes. RCP, Right condylar position; LCP, left condylar position; MSP, Midsagittal plane.

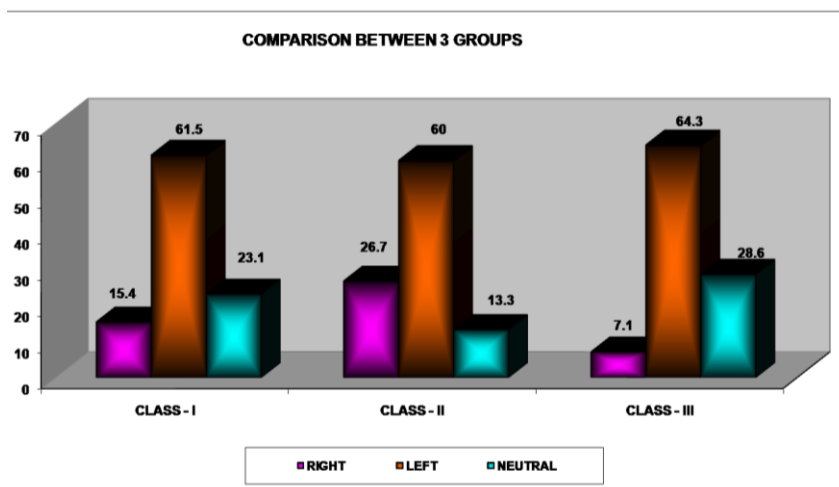




Graph 1: Comparison of the variables within Group 1



Graph 2: Comparing the Depth of the mandibular fossa on the right side



Graph 3: Comparing the position of the condyle in group 1, group 2 and group 3

## **VI. Summary And Conclusion**

Class I malocclusion was associated with more of non-concentric condylar position in the fossa both on the right and left side. There was a higher mean for posterior joint space on the right TMJ, indicating an anteriorly positioned condyle. Class II and Class III malocclusion was associated with more of concentric condylar position in the fossa both on the right and left side. On comparing all three types of malocclusion, a statistically significant difference was observed for the depth of the mandibular fossa on the right side between Class I and Class III malocclusion, with the depth being greater in Class III than Class I. On the anteroposterior aspect, a significant difference was observed for majority of the left condyle being placed more anteriorly than the right condyle in all three types of malocclusion.

## **References**

- [1]. Zane Krisjane, Ilga Urtane, Gaida Krumina, Katrina Zepa. Three-dimensional evaluation of TMJ parameters in Class II and Class III patients. *Stomatologija, Baltic Dental and Maxillofacial Journal* 2009; 11: 32-36.
- [2]. Mongini F, Schmid W. Treatment of mandibular asymmetries during growth. *Eur J Orthod* 1987; 9:51-67.
- [3]. Andrew G. Pullinger, William K. Solberg, Lars Hollender, Arne Petersson. Relationship of mandibular condylar position to dental occlusion factors in an asymptomatic population. *Am J Orthod Dentofacial Orthop* 1987; 91:200-6.
- [4]. O'Byrn BL, Sadowsky C, Schneider B, Begole EA. An evaluation of mandibular asymmetry in adults with unilateral posterior crossbite. *Am J Orthod Dentofacial Orthop* 1995; 107:394-400.
- [5]. S Barghan, S Tetradis, SM Mallya. Application of cone beam computed tomography for assessment of the temporomandibular joints. *Australian Dental Journal* 2012; 57:(1 Suppl): 109-118.
- [6]. Brian Schlueter, Ki Beom Kim, Donald Oliver, Gus Sortiropoulos. Cone Beam Computed Tomography 3D Reconstruction of the Mandibular Condyle. *Angle Orthodontist* 2008; 78(5): 880-888.
- [7]. Mozzo P, Procacci C, Tacconi A, Martini PT, Andreis IA. A new volumetric CT machine for dental imaging based on the cone-beam technique: preliminary results. *Eur Radiol* 1998; 8: 1558-1564.
- [8]. Arai Y, Tammisalo E, Iwai K, Hashimoto K, Shinoda K. Development of compact computed tomographic apparatus for dental use. *Dentomaxillofac Radiol* 1999; 28: 245-248.
- [9]. Oana Bida Honey, Bruce S. Haskell, William Charles Scarfe, Michael J. Hilgers, Kathleen Klueber, Anibal M. Silveira, Allan G. Farman. Accuracy of cone beam computed tomography imaging of the temporomandibular joint: Comparisons with panoramic radiology and linear tomography. *Am J Orthod Dentofacial Orthop* 2007; 132:429-38.
- [10]. Robert Willer Farinazzo Vitral, Carlos de Souza Telles, Marcelo Reis Fraga, Roberto Sotto Maior Fortes de Oliveira, Orlando Motohiro Tanaka. Computed tomography evaluation of temporo- mandibular joint alterations in patients with Class II Division 1 subdivision malocclusions: Condyle-fossa relationship. *Am J Orthod Dentofacial Orthop* 2004; 126:48-52.
- [11]. Rodrigues AF, Fraga MR, Vitral RWF. Computed tomography evaluation of the temporomandibular joint in Class I malocclusion patients: condylar symmetry and condyle-fossa relationship. *Am J Orthod Dentofacial Orthop* 2009; 136:192-8.
- [12]. Andreia Fialho Rodrigues, Marcelo Reis Fraga, Robert Willer Farinazzo Vitral. Computed tomography evaluation of the temporomandibular joint in Class II Division 1 and Class III malocclusion patients: Condylar symmetry and condyle-fossa relationship. *Am J Orthod Dentofacial Orthop* 2009; 136:199-206.
- [13]. Robert Willer Farinazzo Vitral, Marcio Jose da Silva Campos, Andreia Fialho Rodrigues, Marcelo Reis Fraga. Temporomandibular joint and normal occlusion: Is there anything singular about it? A computed tomographic evaluation. *Am J Orthod Dentofacial Orthop* 2011; 140:18-24.
- [14]. Marcelo Reis Fraga, Andréia Fialho Rodrigues, Luiz Claudio Ribeiro, Marcio José da Silva Campos, Robert Willer Farinazzo Vitral. Anteroposterior condylar position: A comparative study between subjects with normal occlusion and patients with Class I, Class II Division 1, and Class III malocclusions. *Med SciMonit* 2013; 19: 903-907.
- [15]. Vitral RWF, Telles CS. Computed tomography evaluation of temporomandibular joint alterations in Class II Division 1 subdivision patients: condylar symmetry. *Am J Orthod Dentofacial Orthop* 2002; 121:369-75.
- [16]. Elias G. Katsavrias and Demetrios J. Halazonetis. Condyle and fossa shape in Class II and Class III skeletal patterns: A morphometric tomographic study. *Am J Orthod Dentofacial Orthop* 2005; 128:337-46.
- [17]. Silva MAG, Wolf U, Heinicke F, Bumann A, Visser H, Hirsch E. Cone beam computed tomography for routine orthodontic treatment planning: a radiation dose evaluation. *Am J Orthod Dentofacial Orthop* 2008; 133:640:e1-5.
- [18]. Kazumi Ikeda and Akira Kawamura. Assessment of optimal condylar position with limited cone beam computed tomography. *Am J Orthod Dentofacial Orthop* 2009; 135:495-501.
- [19]. Jeff T. Cohlmia, Joydeep Ghosh, Pramod K. Sinha, Ram S. Nanda, G. Frans Currier. Tomographic assessment of temporomandibular joints in patients with malocclusion. *Angle Orthd* 1996;66(1):27-36.
- [20]. Yahia H. Ismail, Ahmed Rokni. Radiographic study of condylar position in centric relation and centric occlusion. *Journal of Prosthetic Dentistry* 1980; 43(3): 327-330.
- [21]. Burley MA. An examination of the relation between the radiographic appearance of the temporomandibular joint and some features of the occlusion. *Br Dent J* 1961; 110: 195-200.
- [22]. Anthony A. Gianelly, James C. Petras, Joseph Boffa. Condylar position and Class II deep-bite, no-overjet malocclusions. *Am J Orthod Dentofacial Orthop* 1989;96:428-32.
- [23]. Burke G, Major P, Glover K, Prasad N. Correlations between condylar characteristics and facial morphology in Class II preadolescent patients. *Am J Orthod Dentofacial Orthop* 1998; 114: 328-36.
- [24]. Kim YI, Cho BH, Jung YH, Son WS, Park SB. Cone beam computerized tomography evaluation of condylar changes and stability following two-jaw surgery: Le Fort I osteotomy and mandibular setback surgery with rigid fixation. *Oral Surg Oral Med Oral Pathol Oral Radiol Endod* 2011; 111:681-687.
- [25]. Hyoun Oak Kim, Won Lee, Yoon-Ah Kook, Yoonji Kim. Comparison of the condyle-fossa relationship between skeletal class III malocclusion patients with and without asymmetry: a retrospective three-dimensional cone-beam computed tomography study. *Korean J Orthod* 2013; 43(5): 209-217.
- [26]. Emel Seren, Huseyin Akan, Melahat Ogutcen Toller, Serdar Akyar. An evaluation of the condylar position of the temporomandibular joint by computerized tomography in Class III malocclusions: A preliminary study. *Am J Orthod Dentofac Orthop* 1994; 105:483-8.

- [27]. Hansson T, OÈ berg T, Carlsson GE, Kopp S. Thickness of the soft tissue layers and the articular disk in the temporomandibular joint. *Acta Odont Scand* 1977; 35: 77- 83.
- [28]. Meng. F, Liu. Y, Hu. K, Zhao. Y, Kong. L, Zhou. S. A comparative study of the skeletal morphology of the temporomandibular joint of children and adults. *J Postgrad Med* 2008;54(3):191-4.
- [29]. Vig PS, Hewitt AB. Asymmetry of the human facial skeleton. *Angle Orthod* 1975; 45:125-9.
- [30]. Ben-Bassat Y, Yaffe A, Brin I, Freeman J, Ehrlich Y. Functional and morphological-occlusal aspects in children treated for unilateral posterior cross-bite. *Eur J Orthod* 1993; 15: 57-63.

\*Dr.Gayathri Ganesh. "Evaluation And Comparison of The Relationship of Condyle And Mandibular Fossa In Patients with Class I, Class II Division I And Class III Malocclusion: A Cone Beam Computed Tomography Study." *IOSR Journal of Dental and Medical Sciences (IOSR-JDMS)* 16.8 (2017): 93-103