

Extramedullary Splenic Hematopoiesis In Polycythemia Vera-A Case Report

*Nisha Yadav¹, Neelima Arora², Quadir Fatima³, Amit Kumar⁴

¹(P.G.Student,dept of Pathology, S.P.Medical College, Bikaner, Rajsthan,India)

²(M.D.Associate professor, dept of Pathology,SP.Medical College Bikaner, Rajsthan,India)

³(M.D.Professor,dept of Pathology, S.P.Medical College Bikaner, Rajsthan,India)

⁴(M.D. Pediatrics, Safdarganj Hospital, Delhi,India)

Corresponding Author:

Abstract: Polycythemia Vera is a clonal myeloproliferative neoplastic process characterized by abnormal proliferation of erythrocytes ,megakaryocytes and granulocytes in bone marrow in the absence of an hypoxic stimulus and in the sites of extra medullary hematopoiesis like in spleen.The study is carried out in 46yr female to assess the degree of hematopoiesis to clarify the pathogenesis of splenomegaly.polycythemia Vera is a rare cause of extra medullary hematopoiesis.splenoectomy was done in this patient.Patient was diagnosed with polycythemia Vera 12yrs back

Keywords: Extramedullary hematopoiesis,Spleen

Date of Submission: 11 -09-2017

Date of acceptance: 22-09-2017

I. Introduction

Polycythemia Vera is a clonal myeloproliferative disorder of the bone marrow that can present with extramedullary hematopoiesis in the late stage.Due to replacement of normal bone marrow with fibrous tissue,hematopoiesis pursues in various other organs with reticuloendothelial capacity such as liver,spleen and lymph nodes,is denoted as "extramedullary hematopoiesis".rare sites are skin and heart.

II. Case Report

A 46yr female was diagnosed with polycythemia Vera in 2005.At the time of diagnosis,she had hepatosplenomegaly and leukoerythroblastic picture on blood smear with cell counts within normal limits.Red cell mass was elevated.Her physical examination at current admission revealed hepatomegaly measuring 10cm and her spleen was extending to the inguinal region.The patient hematology at admission was the follows :hemoglobin 18.8gm/dl,white blood cell $16.5 \times 10^9/L$,pcv -60% and rbc count 6.5million /mm.splenoectomy was done in this patient and sent for histopathological examination.

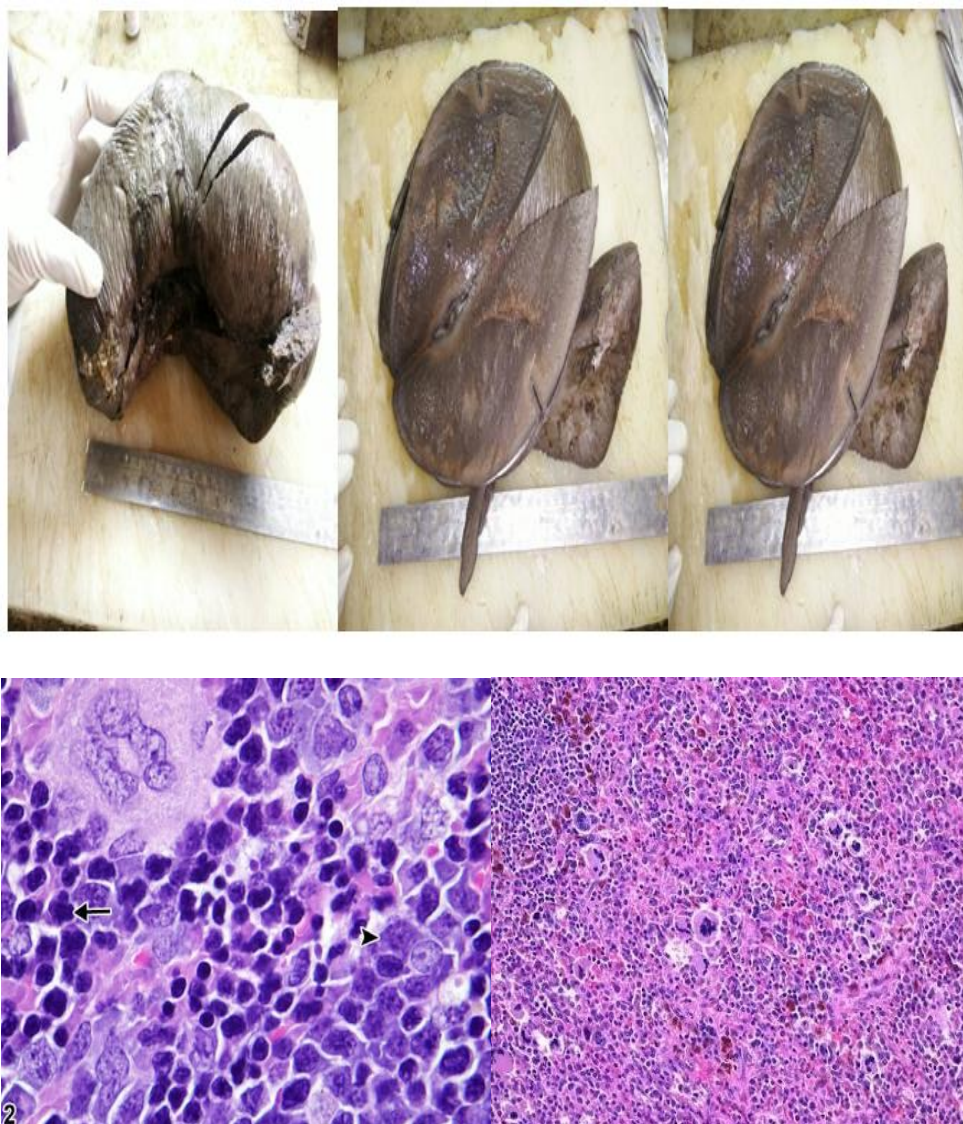
III. Pathological Findings

Gross examination of spleen _massively enlarged spleen ,avg 2kg.Diffusely dark red and moderately firm with multiple areas of hemorrhage.



Microscopic sections show marked expansion of the red pulp and intact white pulp. Most of the red pulp is composed of erythroid islands, myeloid precursor cells and megakaryocytes. A subset of megakaryocytes is atypical with "cloudy" condensed chromatin and a few are seen within sinusoidal spaces. A

few mitotic figures are noted. The erythroid islands show normoblastic maturation. The myeloid cells are left shifted, but blasts are not increased (CD34 and CD117 stains highlight about 5% of myeloid cells). The white pulp is unremarkable. Reed-Sternberg or Hodgkin cells are not seen. Histiocytes/macrophages are not increased. In a patient with a history of myeloproliferative neoplasm, the findings are consistent with splenic extramedullary hematopoiesis..



In images 1 and 2 showing red pulp expansion by numerous hematopoietic cells including megakaryocytes.

IV. Discussion

The spleen in humans does not normally function as a site of hematopoiesis. In normal adult spleen, there is virtually always a very small number of mature hematopoietic elements. The literature supports that these cells are derived from circulating stem cells that take up residence and undergo terminal differentiation, or are circulating maturing elements that are trapped within the spleen, or most likely, a combination of these events [1-3]. When benign bone marrow elements are found in an increased number in the spleen, it is termed extramedullary hematopoiesis, which is also referred to as myeloid metaplasia. Extramedullary hematopoiesis is often a result of conditions that disrupt the marrow microenvironment, facilitating the egress of progenitor and precursor cells, with an increase in circulating mature and immature marrow elements. Extramedullary hematopoiesis can be seen in a wide range of splenic conditions. The splenic microenvironment is uniquely suited as a site for extramedullary hematopoiesis. [4-10] This patient was presented with hepatosplenomegaly and constitutional symptoms like headache, dizziness, weight loss, plethora. The diagnosis is made in laboratory. Red cell count was 6.5 million/mm³, hematocrit is 60%, hb 18.5 gm%. The specific gravity is 1.075 to 1.080, compared with the normal range of 1.055 to 1.065. The

esr is increased. After an average interval of 10 yrs 15% to 20% of cases undergo spent phase and hematopoiesis shift to the spleen, which enlarges markedly.

V. Major And Minor Criteria For Polycythemia[11]

Major WHO criteria are as follows:

1. Hemoglobin >16.5 g/dL in men and >16 g/dL in women, or hematocrit >49% in men and >48% in women, or red cell mass >25% above mean normal predicted value
2. Bone marrow biopsy showing hypercellularity for age with trilineage growth (panmyelosis) including prominent erythroid, granulocytic, and megakaryocytic proliferation with pleomorphic, mature megakaryocytes (differences in size)
3. Presence of JAK2V617F or JAK2 exon 12 mutation

The minor WHO criterion is as follows:

Serum erythropoietin level below the reference range for normal

Diagnostic criteria for PV as per the 2016 revised World Health Organization (WHO) guidelines include three major criteria and a minor criterion. Diagnosis requires the presence of either all three major criteria or the first two major criteria and the minor criterion.

References

- [1]. Freedman MH, Saunders EF. Hematopoiesis in the human spleen. *Am J Hematol* 1981;11:271–275. | PubMed | ISI | ChemPort |
- [2]. O'Keane JC, Wolf BC, Neiman RS. The pathogenesis of splenic extramedullary hematopoiesis in metastatic carcinoma. *Cancer* 1989;63:1539–1543.
- [3]. Wilkins BS, Green A, Wild AE, et al. Extramedullary haemopoiesis in fetal and adult human spleen: a quantitative immunohistological study. *Histopathology* 1994;24:241–247. | PubMed | ISI | ChemPort |
- [4]. Snover DC, Frizzera G, Spector BD, et al. Wiskott–Aldrich syndrome: histopathologic findings in the lymph nodes and spleens of 15 patients. *Hum Pathol* 1981;12:821–831. | PubMed | ISI | ChemPort |
- [5]. Arnold R, Calvo W, Heymer B, et al. Extramedullary hematopoiesis after bone marrow transplantation. *Scan J Haematol* 1985;34:9–12. | ISI | ChemPort |
- [6]. Hassan NM, Neiman RS. The pathology of the spleen in steroid-treated immune thrombocytopenic purpura. *Am J Clin Pathol* 1985;84:433–438. | PubMed | ISI | ChemPort |
- [7]. Douay L, Laporte JP, Lefrancois G, et al. Blood and spleen haematopoiesis in patients with myelofibrosis. *Leukemia Res* 1987;11:725–730. | Article | ISI | ChemPort |
- [8]. Palitzsch KD, Falk S, Muller H, et al. Splenic haematopoiesis in patients with cirrhosis of the liver. *Virchows Arch* 1987;411:179–183. | ISI | ChemPort |
- [9]. Wolf BC, Banks PM, Mann RB, et al. Splenic hematopoiesis in polycythemia vera. A morphologic and immunohistologic study. *Am J Clin Pathol* 1988;89:69–75. | PubMed | ISI | ChemPort |
- [10]. Dilly SA, Sloane JP. Cellular composition of the spleen after human allogeneic bone marrow transplantation. *J Pathol* 1988;155:151–160. | Article | PubMed | ISI | ChemPort |
- [11]. Arber DA, Orazi A, Hasserjian R, Thiele J, Borowitz MJ, Le Beau MM, et al. The 2016 revision to the World Health Organization classification of myeloid neoplasms and acute leukemia. *Blood*. 2016 May 19. 127 (20):2391–405. [Medline]. [Full Text].

*Nisha Yadav. "Extramedullary Splenic Hematopoiesis In Polycythemia Vera-A Case Report."
IOSR Journal of Dental and Medical Sciences (IOSR-JDMS) 16.9 (2017): 82-84