

Role of MRCP in the diagnosis of Acute Gallstone Pancreatitis

Uday Kumar¹, Mritunjay Sarawgi², Arun Kumar Tiwary³, Manjit Singh⁴

¹Junior Resident, Dept. of Surgery, Rajendra Institute of Medical Sciences, Ranchi, Jharkhand, India.

²Professor, Dept. of Surgery, Rajendra Institute of Medical Sciences, Ranchi, Jharkhand, India.

³Associate Professor, Dept. of Surgery, Rajendra Institute of Medical Sciences, Ranchi, Jharkhand, India.

⁴Junior Resident, Dept. of Surgery, Rajendra Institute of Medical Sciences, Ranchi, Jharkhand, India.

Corresponding author: Uday Kumar

Abstract

Aim: To study the patients having gall stone pancreatitis and observe the pattern of study and role of various diagnostic modalities with special emphasis on MRCP in diagnosing the disease.

Materials and Methods: The study was a prospective observational study conducted in the Department of General Surgery, RIMS, Ranchi of Jharkhand state from June 2017 to May 2019 on 50 patients who fulfilled the inclusion criteria. The qualitative variables are described in the form of proportions and quantitative variables are described in the terms of mean, median, range and standard deviation. Data was checked for normality before applying appropriate tests of significance. Significance of difference in proportions (qualitative variables) was calculated using chi square test. Significance of p value was taken as $p < 0.05$. Significance difference in means was calculated using independent t test. Liver function tests mean values were compared with MRCP findings for common bile duct stones. ROC curve analysis was done for liver function tests and ultrasound findings of common bile duct stones with the gold standard MRCP.

Results: In the present study, the clinical features at the time of presentation - epigastric pain, nausea & vomiting, fever and retching & hiccoughs. 68% study participants had fever, 88% had nausea & vomiting, 38% had retching & hiccoughs at the time of presentation. All the study participants-50(100%) presented with the complaints of abdominal pain.

In the present study the ROC curve showed the area (95% CI) under the curve value is 0.845 (0.734-0.956) with a standard error value of 0.056 for elevated liver function tests with positive MRCP finding. LFT was found to be a better predictor as it predicted 84% who had common bile duct stones. Also, it was found that alkaline phosphatase and elevated transaminases were found to be higher in the participants with common bile duct stones. Alkaline phosphatase value has been associated with positive MRCP finding of common bile stone. This was found to be statistically significant (p value- 0.011). Our study reported MRCP to be gold standard in diagnosis of common bile duct stones in a study which compared MRCP with ERCP.²⁴⁻²⁶

Conclusion: MRCP is found to be the gold standard test for diagnosing common bile duct stones as all MRCP positive cases had stones and were removed by ERCP. MRCP would prevent unnecessary intervention (ERCP) thereby reducing patient morbidity.

Keywords: LFT, MRCP, Common bile duct stones.

Date of Submission: 07-12-2018

Date of acceptance: 22-12-2018

I. Introduction

Gallstone pancreatitis is thought to be triggered by the passage of gallstone down the common bile duct. Biliary calculi accounts for 50 to 70% of patients with pancreatitis. Wider the cystic duct, higher the risk of small stones passing through. For detecting CBD dilatation ultrasound (US) demonstrated a sensitivity of 25% and a specificity of 70%.¹

The sensitivity of US for predicting CBD dilatation was 55% when the IOC-derived diameter was >10 mm and 100% when it was >15 mm. Thus the overall sensitivity in detection of stone by US was 10%. This further improves to 17% if patients have a dilated CBD on US.²⁻³

Further using an unenhanced helical CT specificity is 84-100%. And the sensitivity is 65-88% and specificity is 84-100%. With the use of contrast IV cholangiography along with helical CT, the sensitivity is 85% and specificity is much higher 88%.⁴⁻⁵

The role of ERCP is crucial because in detection of gall stones the sensitivity of ERCP was 96% and specificity of ERCP was 92%.⁶⁻⁹ For the detection of CBD stone EUS gives a sensitivity of 88-97% and specificity of 93-100%.¹⁰⁻¹⁴

MRCP resulted in 100% sensitivity and 96% specificity in detecting CBD stones. Also it does not expose the patient to radiation like CT SCAN, does not require administration of exogenous contrast materials

and avoids the complications of invasive procedure like ERCP. Magnetic resonance cholangiopancreatography may have a role in those situations where initial evaluation suggests a benign cause of biliary pathology requiring further cholangiographic confirmation but not necessarily intervention. It may also be useful in cases of failed ERCP before transhepatic cholangiography, especially in cases where minimal intrahepatic dilatation is suggested by ultrasound or CT, making percutaneous transhepatic cholangiography more difficult. With complex problems of the biliary tree, MRCP may allow a definitive diagnosis, which may help plan a directed intervention (endoscopic or transhepatic) that would have an increased likelihood of success, with decreased risk. The aim of this study is to identify whether magnetic resonance cholangiopancreatography (MRCP) can be used selectively in patients with acute gallstone pancreatitis to detect choledocholithiasis. The objective of the study was to assess the role of MRCP in diagnosis of choledocholithiasis among patients with gall stone pancreatitis.

II. Material And Methods

The study was a prospective observational study conducted in the Department of General Surgery, RIMS, Ranchi of Jharkhand state from June 2017 to May 2019 on 50 patients who fulfilled the inclusion criteria.

The study population comprised of patients with and probable diagnosis of acute gallstone pancreatitis presenting at emergency and out patients department of surgery.

All patients clinically suspected to have acute gallstone pancreatitis and finding of gallstones on USG abdomen, patients having Serum amylase >300 u/L, cases of all age groups irrespective of sex and on USG CBD was dilated and more than 8 mm.

All patients having an implanted pacemaker, defibrillator, or heart valve, an implanted pump device (such as an insulin or pain medication pump), an inner ear implant, an aneurysm clip within the brain, an intrauterine device (IUD), metal in the eyes (at any time), or have ever been a metal worker of any kind, permanent tattoo eyeliner, currently pregnant, artificial joints or metallic plates, patient having history of claustrophobia, patient who require sedation or ventilation were excluded from the study.

The sampling method was consecutive sampling method done in Department of Surgery in the hospital. The study participants who presented with and probable diagnosis of gallstone pancreatitis who so ever fulfilled the inclusion criteria and willing to participate in the study were included successively.

The qualitative variables are described in the form of proportions and quantitative variables are described in the terms of mean, median, range and standard deviation. Data was checked for normality before applying appropriate tests of significance. Significance of difference in proportions (qualitative variables) was calculated using chi square test. Significance of *p* value was taken as *p* < 0.05. Significance difference in means was calculated using independent *t* test. Liver function tests mean values were compared with MRCP findings for common bile duct stones. ROC curve analysis was done for liver function tests and ultrasound findings of common bile duct stones with the gold standard MRCP.

III. Results

Profile of study participants

Among the 50 study participants, 33 (66%) were males and 17(34%) were females. The mean (\pm SD) age of study participants was 41.02 (\pm 12) years with a range of 24 – 62 years. 12(24%) study participants had history of alcohol consumption among which 10(20%) had quit alcohol consumption at the time of study (past history). The etiology of acute pancreatitis is varied- Alcohol in 17(38%), Gall stone in 21(42%), both gall stone and alcohol in 1(2%) and idiopathic in 9 (18%) study participants. (Table 1) The study participants presented with various symptoms –epigastric pain, nausea & vomiting, fever and retching & hiccoughs among which epigastric pain was reported by all the study participants 50(100%)

Table 1 Profile of the study participants presented with acute pancreatitis. (N =50)

S.No.	Parameters	N (%)
1.	Gender	
	Male	33(66)
	Female	17(34)
2.	Occupation	
	Clerk/Shop keeper	4(8)
	Skilled worker	5(10)
	Unskilled worker	26(51)
	House wife	12(24)
	Student	2(4)
3.	Past history of alcohol consumption	
	Yes	10(20)
	No	40(80)
4.	Etiology	

Alcohol	19(38)
Gallstone	21(42)
Gallstone & Alcohol	1(2)
Idiopathic	9(18)

Table 2 Distribution of study participants according to liver function tests. (N =50)

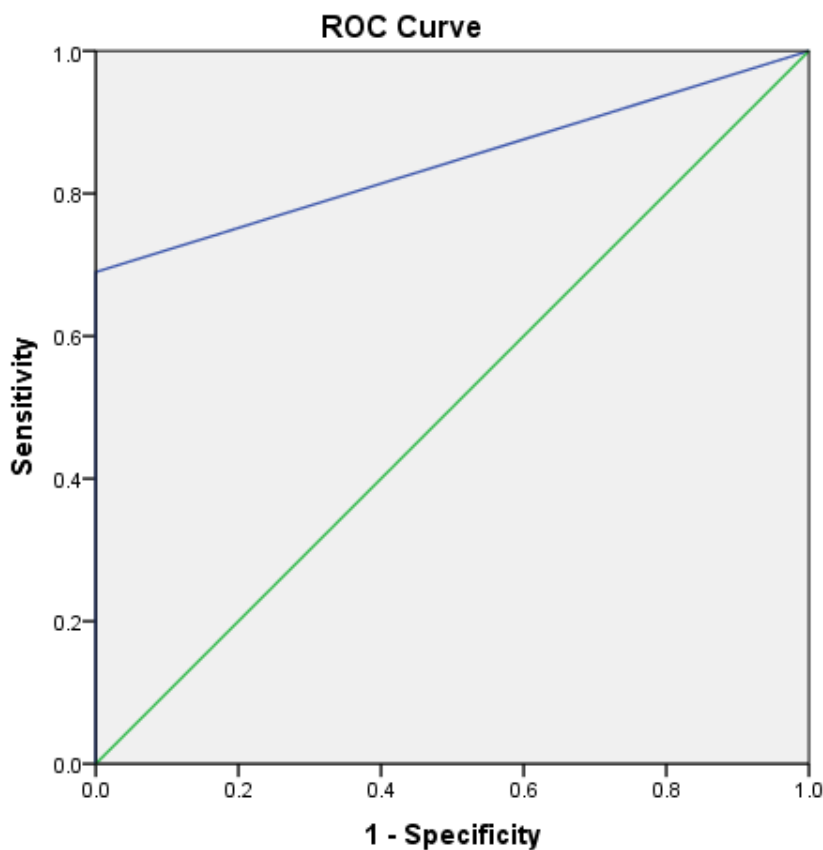
S.No.	Parameters	Mean(±SD)
1.	Bilirubin (Total)	2.7(0.9)
2.	Bilirubin (Direct)	1.5(0.7)
3.	Amylase	750(46)
4.	PT INR	1.4(0.49)
5.	Alkaline phosphatase	587(93)
6.	SGOT	457(23)
7.	SGPT	345(67)

Table 3 Distribution of study participants according to the lipase and amylase levels. (N =50)

S. No.	Parameters	N(%)
1.	Elevated lipase levels	
	Yes	41(82)
2.	Elevated amylase levels	
	Yes	46(92)
	No	4(8)

Among the study participants 20(40%) had elevated levels of transaminases. Elevated levels of amylase was seen in 46 (92%) of study participants and elevated lipase levels were seen in 41(82%) of study participants. Ultrasound feature suggesting common bile duct stone (>8mm diameter) was seen in 20(40%) of the participants.

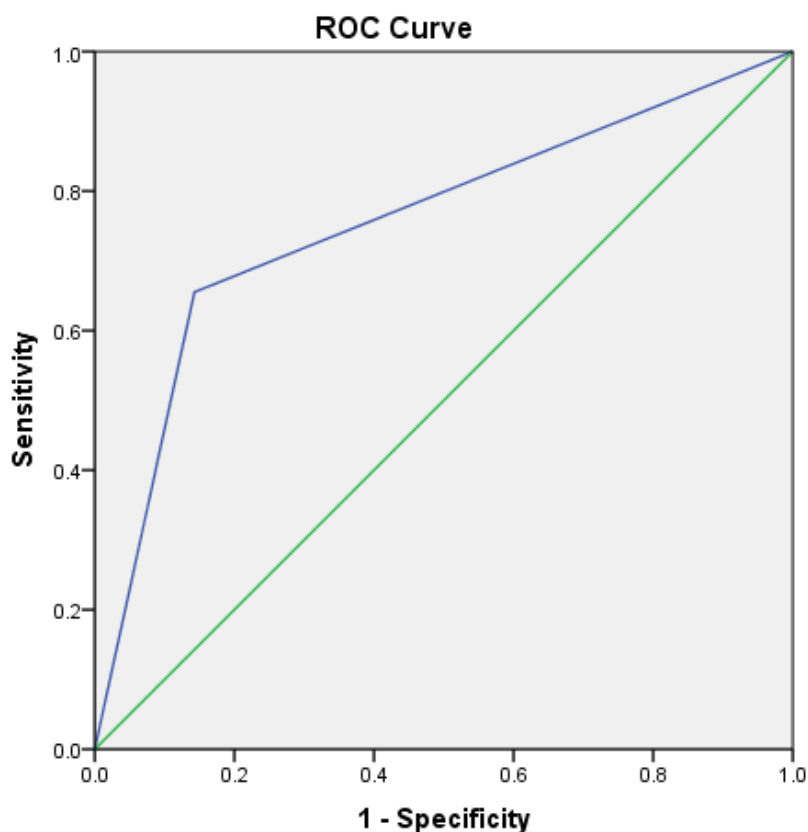
Figure 1 Receiver Operating Characteristic (ROC) curve analysis for Liver function tests with MRCP



Diagonal segments are produced by ties.

The area (95% CI) under the curve value is 0.845 (0.734-0.956) with a standard error value of 0.056. LFT was found to be a better predictor as it predicted 84% who had common bile duct stones.

Figure 2 Receiver Operating Characteristic (ROC) curve analysis for Ultrasound finding with MRCP



The area (95% CI) under the curve value is 0.756 (0.619-0.894) with a standard error value of 0.070. Ultrasound finding was found to be a fair predictor as it predicted 76% who had common bile duct stones. All the patients who were found to be positive for common bile duct stones in MRCP 21(42%) underwent ERCP and the stones were removed. MRCP is found to be the gold standard test for diagnosing common bile duct stones as all MRCP positive cases had stones and were removed by ERCP. All the patients who were found to be positive for common bile duct stones in MRCP 21(42%) underwent ERCP and the stones were removed. MRCP is found to be the gold standard test for diagnosing common bile duct stones as all MRCP positive cases had stones and were removed by ERCP.

IV. Discussion

In the present study, the clinical features at the time of presentation - epigastric pain, nausea & vomiting, fever and retching & hiccoughs. 68% study participants had fever, 88% had nausea & vomiting, 38% had retching & hiccoughs at the time of presentation. All the study participants-50(100%) presented with the complaints of abdominal pain.

In the present study the ROC curve showed the area (95% CI) under the curve value is 0.845 (0.734-0.956) with a standard error value of 0.056 for elevated liver function tests with positive MRCP finding. LFT was found to be a better predictor as it predicted 84% who had common bile duct stones. Also, it was found that alkaline phosphatase and elevated transaminases were found to be higher in the participants with common bile duct stones. Alkaline phosphatase value has been associated with positive MRCP finding of common bile stone. This was found to be statistically significant. (p value- 0.011) These results are similar to the previous studies which also have reported that elevated liver function tests are associated with common bile duct stone findings in MRCP.¹⁵⁻¹⁹ In our study, ultrasound finding was found to be a fair predictor as it predicted 76% who had common bile duct stones as shown by ROC curve analysis. This findings are also similar to previous studies.^{19,20}

In the present study, all the patients who were found to be positive for common bile duct stones in MRCP 21(42%) underwent ERCP and the stones were removed. MRCP is found to be the gold standard test for diagnosing common bile duct stones as all MRCP positive cases had stones and were removed by ERCP. This finding was supported by many previous studies²⁰⁻²⁶ Similar to our study MRCP was reported to be gold standard in diagnosis of common bile duct stones in a study which compared MRCP with ERCP.²⁴⁻²⁶

V. Conclusion

LFT was found to be a better predictor as it predicted 84% who had common bile duct stones. Ultrasound finding was found to be a fair predictor as it predicted 76% who had common bile duct stones. MRCP is found to be the gold standard test for diagnosing common bile duct stones as all MRCP positive cases had stones and were removed by ERCP. MRCP would prevent unnecessary intervention (ERCP) thereby reducing patient morbidity.

VI. Recommendation

It is recommended that liver function tests could be simple tests to predict the presence of common bile duct stones and this could avoid unnecessary intervention (ERCP). It would avoid unnecessary patient morbidity. MRCP is found to be the gold standard test for diagnosing common bile duct stones as all MRCP positive cases had stones and were removed by ERCP.

References

- [1]. Lichtenbaum RA¹, McMullen HF, Newman RM., *SurgEndosc.* 2000 Mar;14(3):254-7
- [2]. Neoptolemos JP, Hall AW, Finlay DF, Berry JM, Carr-Locke DL, Fossard DP. The urgent diagnosis of gallstones in acute pancreatitis: a prospective study of three methods. *Br J Surg*1984; 71: 230-233 [PMID: 6141833 DOI: 10.1002/bjs.1800710324]
- [3]. Vilgrain V, Palazzo L. Choledocholithiasis: role of US and endoscopic ultrasound. *Abdom Imaging* 2001; 26: 7-14 [PMID: 11116352 DOI: 10.1007/s002610000108]
- [4]. Cabada-Giadas T, Sarría Octavio de Toledo L, Martínez-Berganza-Asensio MT, Cozcolluela-Cabrejas R, Alberdi Ibáñez I, Alvarez López A, García-Asensio S. Helical CT cholangiography in the evaluation of the biliary tract: application to the diagnosis of choledocholithiasis. *Abdom Imaging* 2002; 27: 61-70 [PMID: 11740611 DOI: 10.1007/s00261-001-0043-6]
- [5]. Jiménez Cuenca I, delOlmo-Martínez L, Pérez Homs M. Helical CT without contrast in choledocholithiasis diagnosis. *EurRadiol*2001; 11: 197-201 [PMID: 11218014 DOI: 10.1007/s003300000609]
- [6]. Stabuc B, Drobne D, Ferkolj I, Gruden A, Jereb J, Kolar G, Mlinaric V, Mervic M, Repse A, Stepec S, Markovic S, *Eur J GastroenterolHepatol.* 2008 Dec;20(12):1171-5. doi: 10.1097/MEG.0b013e32830a9a31
- [7]. Trondsen E, Edwin B, Reiertsen O, Fagertun H, Rosseland AR. (1995) Selection criteria for endoscopic retrograde cholangiopancreatography (ERCP) in patients with gallstone disease. *World J Surg*19:852–856; discussion 857.
- [8]. de Lédighen V, Lecesne R, Raymond JM, Gense V, Amouretti M, Drouillard J, Couzigou P, Silvain C. Diagnosis of choledocholithiasis: EUS or magnetic resonance cholangiography? A prospective controlled study. *GastrointestEndosc*1999; 49: 26-31 [PMID: 9869719 DOI: 10.1016/S0016-5107(99)70441-4]
- [9]. Prat F, Amouyal G, Amouyal P, Pelletier G, Fritsch J, Choury AD, Buffet C, Etienne JP. Prospective controlled study of endoscopic ultrasonography and endoscopic retrograde cholangiography in patients with suspected common-bile-duct lithiasis. *Lancet* 1996; 347: 75-79 [PMID: 8538344 DOI: 10.1016/S0140-6736(96)90208-1]
- [10]. Maple JT, Ben-Menachem T, Anderson MA, Appalaneni V, Banerjee S, Cash BD, Fisher L, Harrison ME, Fanelli RD, Fukami N, Ikenberry SO, Jain R, Khan K, Krinsky ML, Strohmeier L, Dominitz JA. The role of endoscopy in the evaluation of suspected choledocholithiasis. *GastrointestEndosc* 2010; 71: 1-9
- [11]. Freitas ML, Bell RL, Duffy AJ. Choledocholithiasis: evolving standards for diagnosis and management. *World J Gastroenterol* 2006; 12: 3162-3167
- [12]. Dumot JA. ERCP: current uses and less-invasive options. *Cleve Clin J Med* 2006; 73: 418, 421, 424-425]
- [13]. Grande M, Torquati A, Tucci G, Rulli F, Adorisio O, Farinon AM. Preoperative risk factors for common bile duct stones: defining the patient at high risk in the laparoscopic cholecystectomy era. *J LaparoendoscAdvSurg Tech A* 2004; 14: 281-286 [PMID: 15630944 DOI: 10.1089/lap.2004.14.281]
- [14]. Charatcharoenwitthaya P, Sattawatthamrong Y, Manatsathit S, Tanwadee T, Leelakusolvong S, Kachintorn U, Leungrojanakul P, Boonyapisit S, Pongprasobchai S. Predictive factors for synchronous common bile duct stone in patients with symptomatic cholelithiasis. *J Med Assoc Thai* 2004; 87: 131-136
- [15]. Lee SP, Nicholls JF, Park HZ. Biliary sludge as a cause of acute pancreatitis. *N Engl J Med.* 1992 Feb 27;326(9):589-93.
- [16]. Halldestam I, Kullman E, Borch K. Incidence of and potential risk factors for gallstone disease in a general population sample. *Br J Surg.* 2009 Nov. 96(11):1315-22.
- [17]. Kreimer F, Cunha DJ, Ferreira CC, Rodrigues TM, Fulco LG, Godoy ES. Comparative analysis of preoperative ultrasonography reports with intraoperative surgical findings in cholelithiasis. *Arq Bras Cir Dig.* 2016 Mar;29(1):26-9.
- [18]. Videhul P, Sandblom G, Rudberg C, Rasmussen C. Are liver function tests, pancreatitis and cholecystitis predictors of common bile duct stones? Results of a prospective, population-based, cohort study of 1171 patients undergoing cholecystectomy. *HPB* 2011, 13, 519–527
- [19]. Wilcox CM, Kim H. Prospective Evaluation of the Clinical Features of Choledocholithiasis: Focus on Abdominal Pain. *South Med J.* 2016 May;109(5):290-3..
- [20]. Hjartarson JH, Hannesson P, Sverrisson I, Blöndal S, Ívarsson B, Björnsson ES. The value of magnetic resonance cholangiopancreatography for the exclusion of choledocholithiasis. *Scand J Gastroenterol.* 2016 May 16:1-8
- [21]. Kamath SU, Dharap SB, Kumar V. Scoring system to preoperatively predict choledocholithiasis. *Indian J Gastroenterol.* 2016 May 5.
- [22]. Ward WH, Fluke LM, Hoagland BD, Zarow GJ, Held JM, Ricca RL. The Role of Magnetic Resonance Cholangiopancreatography in the Diagnosis of Choledocholithiasis: Do Benefits Outweigh the Costs? *Am Surg.* 2015 Jul;81(7):720-5.

- [23]. Aydelotte JD, Ali J, Huynh PT, Coopwood TB, Uecker JM, Brown CV. Use of Magnetic Resonance Cholangiopancreatography in Clinical Practice: Not as Good as We Once Thought. *J Am Coll Surg.* 2015 Jul;221(1):215-9.
- [24]. Petrescu I, Bratu AM, Petrescu S, Popa BV, Cristian D, Burcos T. CT vs. MRCP in choledocholithiasis jaundice. *J Med Life.* 2015 Apr-Jun;8(2):226-31.
- [25]. Chen W, Mo JJ, Lin L, Li CQ, Zhang JF. Diagnostic value of magnetic resonance cholangiopancreatography in choledocholithiasis. *World J Gastroenterol.* 2015 Mar 21;21(11):3351-60.
- [26]. Al-Jiffry BO, Elfateh A, Chundrigar T, Othman B, Almalki O, Rayza F, Niyaz H, Elmakhzangy H, Hatem M. Non-invasive assessment of choledocholithiasis in patients with gallstones and abnormal liver function. *World J Gastroenterol.* 2013 Sep 21;19(35):5877-82.

Uday Kumar. "Role of MRCP in the diagnosis of Acute Gallstone Pancreatitis." IOSR Journal of Dental and Medical Sciences (IOSR-JDMS), vol. 17, no. 12, 2018, pp 32-37.