

Foreign body perforation of duodenum presenting as acalculous cholecystitis- A case report

Sathasivam Subramani¹, Anbalagan.A², Rajendran.V³, Rajendran.S⁴

¹(Department of Surgical Gastroenterology, Madras medical college, Chennai)

²(Department of Surgical Gastroenterology, Madras medical college, Chennai)

³(Department of Surgical Gastroenterology, Madras medical college, Chennai)

⁴(Department of Surgical Gastroenterology, Madras medical college, Chennai)

Abstract: A 38-year-old female was evaluated in our outpatient department with complaints of intermittent vague upper abdominal pain lasting for 2 months. She did not report any other Gastrointestinal (GI) complaints and had an unremarkable past history and physical examination. Ultrasound abdomen and CECT abdomen were suggestive of acalculous cholecystitis. ^{99m}Tc-mebrofin hepatobiliary scintigraphy showed cholecystitis with severe dysfunction of gallbladder and duodenogastric reflux. We planned for an elective Laparoscopic cholecystectomy and after releasing the omental adhesions, found a toothpick protruding out from first part of duodenum, closely applied to gallbladder wall with surrounding inflammation. We removed the toothpick with Maryland forceps and did cholecystectomy, with suturing of perforation in duodenum. The histopathological examination of gallbladder was reported as acalculous cholecystitis. Acalculous cholecystitis is traditionally thought to occur in patients with serious medical or surgical illness. Foreign body perforation of GI tract is not a recognized cause of acute acalculous cholecystitis. Foreign body perforation can be included as differential diagnosis in young and fit patients with discordant clinical picture of acalculous cholecystitis.

Date of Submission: 07-03-2018

Date of acceptance: 23-03-2018

I. Case history

A 38-year-old female turned up in our outpatient department with complaints of vague upper abdominal pain lasting for 2 months. She had intermittent pain lasting for 1-2 hours, which subsided spontaneously. Pain was not associated with food intake and was nonradiating. She did not report any other Gastrointestinal (GI) complaints. She had no history of fever. Her general condition was good (BMI -24) and abdominal examination was normal. Her blood investigations were normal. Ultrasound abdomen showed gallbladder wall thickening with minimal pericholecystic fluid suggestive of acalculous cholecystitis. Computed tomography (CT) scan abdomen confirmed the ultrasound findings. Upper GI endoscopy was normal.

Acute acalculous cholecystitis is traditionally known to occur in critically ill patients, following cardiac surgery, abdominal vascular surgery, severe trauma, total parenteral nutrition, or sepsis¹. Our patient was otherwise medically fit and relatively younger with mild symptoms. In view of atypical presentation of acalculous cholecystitis, Patient was advised a trial of conservative management. She returned with persistent pain after one week. We did a ^{99m}Tc-mebrofin hepatobiliary scintigraphy to confirm gallbladder functional status (Fig 1&2). Findings were compatible with cholecystitis with severe dysfunction of gallbladder and duodenogastric reflux.




Figure 1: Scintigraphy

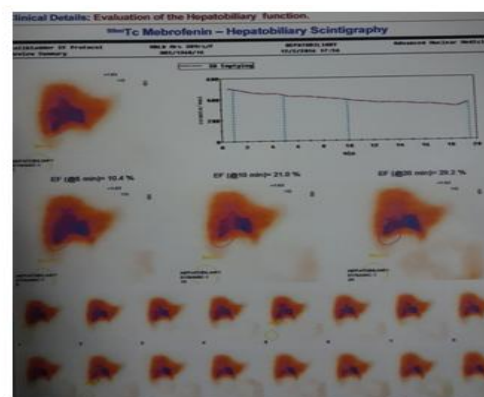


Figure 2: Scintigraphy

We assessed the patient for elective Laparoscopic cholecystectomy. Intraoperatively omentum was adherent to gallbladder. On releasing the omental adhesions, we found a toothpick protruding out from first part of duodenum and closely applied to gallbladder wall with surrounding inflammation (Fig.3). We removed toothpick with Maryland forceps and did cholecystectomy. Perforation site in duodenum was sutured with 2-0 vicryl with intracorporeal knotting. Postoperative period was uneventful and discharged on fourth postoperative day with full oral intake. The histopathological examination of gallbladder was reported as acalculous cholecystitis. Toothpick measured about 5.0 x 0.3 cm in size. On retrospective questioning, Patient could not remember the history of using toothpick.

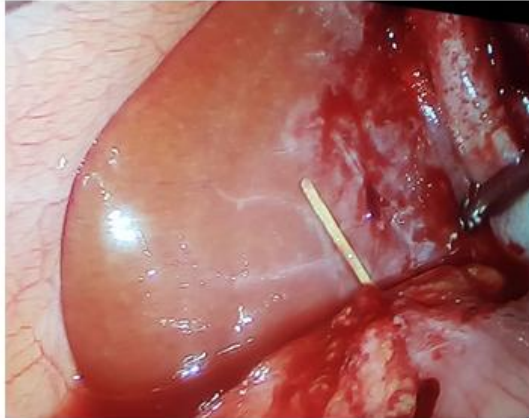


Figure 3: Toothpick penetrating duodenum (after separating omental adhesions). Note GB wall inflammation

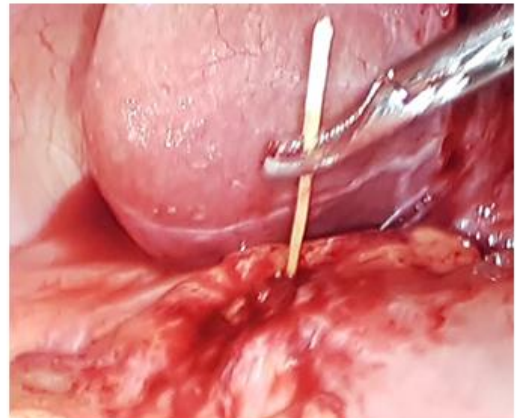


Figure 4: Tooth prick removed with Maryland forceps

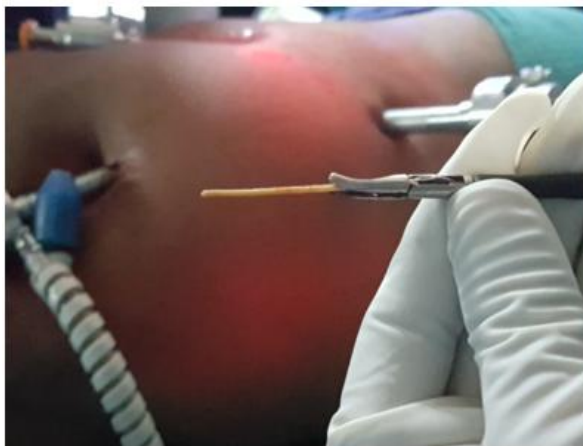

Figure 5: After removal



Figure 6: Removed Toothpick, about 6 cm in length

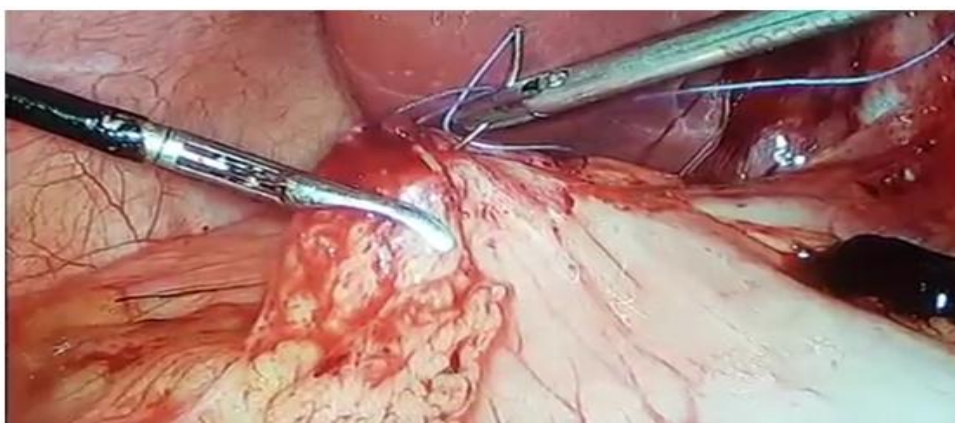

Figure 7: Intracorporeal Suturing of first part of duodenum

II. Discussion

Accidental or intentional foreign body ingestion is common in paediatric and adolescent age groups and in people with psychiatric disorders. Most of the patients can be safely observed either in hospital or in an outpatient setting as the foreign bodies pass through the entire GI tract once they cross esophagus without any symptoms. In infrequent cases, they do cause symptoms, which may necessitate surgical intervention either as an emergency or elective procedure. Fish bones are most common cause followed by toothpicks and metallic foreign bodies.¹ Foreign body ingestion, of which the patient themselves are not aware resulting in significant symptoms, is very rare.

Acalculous cholecystitis as such occurs in patients with serious medical or surgical illness². Foreign body perforation of GI tract is not a recognized cause of acute acalculous cholecystitis. Amir Mehran reported a case of gastric perforation by metal pin, which presented like acalculous cholecystitis.³ Daniel Henneman presented a case of gastric perforation due to wooden stick, which mimicked as acute cholecystitis⁴. However, in his report, preoperative ultrasound picked up gallstones and diagnosed as acute calculous cholecystitis. To the best of our knowledge, there are no other studies reporting foreign body perforation of GI tract presenting as cholecystitis. Literature review shows many case reports of foreign body perforations of gastro duodenal region and migrating to liver. In such cases it presents as liver abscess^{5, 6, 7} or inflammatory pseudotumor of liver.^{8, 9}

In our case, foreign body perforation of the duodenum by toothpick in an otherwise healthy adult female resulted in clinical picture and relevant investigations mimicking acalculous cholecystitis. Radiological imaging could not pick up a wooden foreign body, as a cause for cholecystitis. HIDA scan was also suggestive of acalculous cholecystitis and led us to diagnose the patient with acalculous cholecystitis in spite of clinical suspicion. Toothpick after perforation could have caused direct irritation or inflammation resulting in severe dysfunction of gallbladder, which presented as cholecystitis. Slow perforation of duodenum could have resulted in sealing of perforation tract explaining for the absence of peritonitis signs. Preoperative upper GI scopy failed to show the toothpick as it could have migrated out of mucosa by the time it caused symptoms.

Our patient is a reminder that despite extensive investigations, wooden foreign bodies can still be missed and definitive diagnosis will be provided only by surgery. Foreign body perforation can be included as differential diagnosis in young and fit patients with discordant clinical picture of acalculous cholecystitis.

III. Conclusion

Foreign body perforation of duodenum mimicking as acalculous cholecystitis is rare. Clinicians dealing with atypical presentation of acalculous cholecystitis should keep this rare possibility among the differential diagnosis.

References

- [1]. Goh BK, Chow PK, Quah HM, et al. Perforation of the gastrointestinal tract secondary to ingestion of foreign bodies. *World J Surg* 2006;30:372-7
- [2]. Acute Acalculous Cholecystitis, *Gastroenterology Clinics of North America*, Volume 39, Issue 2, Pages 343-357; Philip S. Barie, Soumitra R. Eachempati.
- [3]. Mehran A, Podkameni D, Rosenthal R, et al. Gastric perforation secondary to ingestion of a sharp foreign body. *JSLs* 2005;9:91-3
- [4]. Henneman D, Bosman W-M, Ritchie ED, van den Bremer J. Gastric perforation due to foreign body ingestion mimicking acute cholecystitis. *BMJ Case Reports*. 2015;2015:bcr2014207806. doi:10.1136/bcr-2014-207806.
- [5]. Glick WA, Simo KA, Swan RZ, et al. Pyogenic hepatic abscess secondary to endoluminal perforation of an ingested foreign body. *J Gastrointest Surg* 2012;16:885-7.
- [6]. Panebianco A, Lozito R, Prestera A, et al. Unusual liver abscess secondary to ingested foreign body: laparoscopic management. *Il Giornale di Chirurgia*. 2015;36(2):74-75.
- [7]. Dugger K, Leiby T, Brus M, et al. Hepatic abscess resulting from gastric perforation of a foreign object. *Am J Emerg Med* 1990;8:323-5
- [8]. Srinivasan UP, Duraisamy AB, Ilango S, Rathinasamy A, Chandramohan SM. Inflammatory pseudotumor of liver secondary to migrated fishbone - a rare cause with an unusual presentation. *Annals of Gastroenterology: Quarterly Publication of the Hellenic Society of Gastroenterology*. 2013;26(1):84-86.
- [9]. Zhang Y, Lu H, Ji H, Li Y. Inflammatory pseudotumor of the liver: A case report and literature review. *Intractable & Rare Diseases Research*. 2015;4(3):155-158. doi:10.5582/irdr.2015.0102

Sathasivam Subramani "Foreign body perforation of duodenum presenting as acalculous cholecystitis- A case report. *IOSR Journal of Dental and Medical Sciences (IOSR-JDMS)*, vol. 17, no. 3, 2018, pp 26-28.