

A Comparative Study of Outcome of Percutaneous Lateral And Crossed Pinning In The Treatment of Type Iii Supracondylar Fractures of Humerus In Children

Harindra Himanshu¹, Bijoy Kumar², Lal Bahadur Manjhi³

1. Senior Resident, 2. Associate Professor, 3. Professor

Department Of Orthopaedics, RIMS, Ranchi -834009, Jharkhand, India.

Correspondence Author: Dr. Harindra Himanshu, Senior Resident,

Abstract

Background and Objectives: The commonly accepted treatment of type III, extension-type supracondylar fractures of humerus in children is closed reduction with percutaneous pinning. The present study aims at comparing the functional outcome of percutaneous crossed pinning with lateral pinning. **Methods:** An analysis of results with regard to ulnar nerve injury, carrying angle and range of movements was made in 22 children with lateral pinning and 38 children with crossed pinning. Functional outcome was graded according to Mitchell and Adams criteria. **Results:** There was no statistically significant difference with regard to functional outcome, between the two groups. Both methods produced satisfactory results in all cases. Ulnar nerve injury occurred in three cases (5%) after crossed pinning. One case had significant palsy, which recovered by four months and the other had only ulnar nerve paraesthesia. **Interpretations and Conclusions:** Percutaneous pinning is an excellent method of treatment of type III supracondylar fractures in children. Crossed medial and lateral pinning may be considered the treatment of choice in majority of these fractures, with careful technique safeguarding against ulnar nerve injury. The lateral pinning is an equally good treatment choice especially for the grossly swollen elbows in which the medial epicondyle is barely palpable.

Keywords: Supracondylar fracture, humerus, crossed pinning, lateral pinning, ulnar nerve, carrying angle, range of motion.

Date of Submission: 26-03-2018

Date of acceptance: 09-04-2018

I. Introduction

Supracondylar humeral fractures are the most common elbow fractures in children^[1]. One epidemiologic study of elbow fractures in children identified supracondylar fractures in 58%^[2]. Treatment of supracondylar humeral fractures in children has been the subject of much discussion and dispute for many years. Historically, these fractures were associated with complications such as malunion that resulted in cosmetically and functionally inferior results. Results have been improved and the frequency of these complications dramatically decreased with more modern techniques of treatment, specially with the advent of the image intensifier, which facilitates accurate pin placement^[1]. Various treatment options for supracondylar fractures are: conservative or operative. Conservative in the form of closed reduction and immobilization in pop slab or cast. Operative in form of closed reduction and percutaneous k wires fixation, open reduction and k wires fixation or traction. Overall goal of all forms of treatment is the same, to obtain and maintain an anatomic reduction of the distal humerus to minimize complications such as nerve injury, compartment syndrome, Volkmann ischaemic contracture, cubitus varus deformity and limitation of elbow movements. In current practice treatment is determined by the type of fracture. Type III fractures are inherently unstable, because in type III fractures, the periosteum is torn, there is no cortical contact between the fragments, and soft tissue injury may accompany the fracture^[3]. Although a number of historic series used casting as primary treatment, most recent reports favor pinning of this fracture because of concerns about vascular compromise, compartment syndrome, and malunion^[4]. Hence most type III fractures require operative (close) reduction and pinning (crossed pinning or lateral pinning)^[3]. The present study is an attempt towards assessing and comparing the results of two methods of pinning – crossed pinning and lateral pinning – presently followed in the management of these difficult fractures.

AIMS AND OBJECTIVES

The aim of our study is :-

1. To evaluate the outcome of fixation of type III supracondylar fractures by closed reduction, internal fixation with **percutaneous crossed pinning**.
2. To evaluate the outcome of fixation of type III supracondylar fractures by closed reduction, internal fixation with **lateral pinning**.
3. To **compare the results of the two types of percutaneous pinning** in the management of type III supracondylar fractures.

II. Materials And Method

This study was conducted from April 2015 to March 2017. During this period a total of 60 patients with closed, Gartland type III supracondylar fractures of humerus, attending the Orthopaedic emergency and outpatient department were included in the study.

INCLUSION CRITERIA :-

1. Gartland type III supracondylar fractures of humerus of either side in either sex, in children between the age group of 3-12 years.

EXCLUSION CRITERIA :-

1. Gartland type I and type II supracondylar fractures.
2. Gartland type III supracondylar fractures treated by open reduction and internal fixation
3. Compound injuries around elbow with supracondylar fractures.

TECHNIQUE :-

After the patient's arrival to the hospital, detailed history was taken and thorough clinical examination (local and general examination) was done. Distal neurovascular survey was done and recorded. After taking appropriate x ray, (i.e. - Standard antero-posterior and lateral radiographs) of the involved elbow, fracture was noted and classified. The cases were treated on an emergency basis with closed reduction and percutaneous pinning, under the guidance of C-arm image intensifier. After pre operative medications, general anesthesia was administered and patient were positioned supine on the operating table with affected limb being placed on a radiolucent arm board or over the sterile draped C-arm image intensifier. The fracture was first reduced in the frontal plane and reduction is checked with fluoroscopy. The elbow was then flexed while the olecranon is pushed anteriorly to correct the sagittal deformity. Restoration of the Baumann angle (which is generally >10 degrees) on the AP view, intact medial and lateral columns on oblique views, and the anterior humeral line passing through the middle third of the capitellum on the lateral view are indications of a successful reduction. Because of the amount of rotation present at the shoulder, some rotational malalignment in the axial plane can be tolerated at the fracture site, but any rotational malalignment can compromise fracture stability, so, if present, stability of the reduction should be carefully evaluated, before going for the fixation. Reduction is held with two or three Kirschner wires (K-wires). The choice of K-wire construct (i.e. :- crossed or lateral pin fixation) depends on the operating surgeon's personal preference. Usually two k wires are preferred but any rotational malalignment can compromise fracture stability, so, if present, stability of the reduction should be carefully evaluated, and a third pin probably should be used. If a medial pin is used, the lateral pin (s) should be placed first, then the elbow should be extended and the medial pin placed without hyperflexion of the elbow. The elbow is immobilized in 50 to 60 degrees of flexion or more, depending on the amount of swelling and vascular status. After proper placement of the pins, the elbow was extended and the adequacy of reduction and stability was assessed in both the views. About a cm of pins were left outside the skin and rest were removed. Left out pins were bent and well padded before applying above elbow slab with elbow flexed to 50 to 60 degrees or more, depending on the amount of swelling and vascular status. Neurovascular status of limb were assessed before sending the patient back to ward.

Postoperative Mobilization& Rehabilitation

The 'K' wires were removed at four to six weeks time as an out patient procedure. The slab was continued till the end of 4 weeks. Active elbow exercises were started from fourth week as tolerated by the child. Passive motion and forceful manipulation were avoided. Patient and their attended are specifically advised to avoid massage.

Follow Up Protocol

All patients were followed for at least six months .Follow up was done regularly at 3 weeks, 6 weeks, 3 months, 6 months. During the follow-up period pain , restriction of motion and satisfaction with appearance of elbow was assessed. Carrying angle and the range of flexion and extension of both the injured and the normal elbow was measured with a goniometer and recorded. Radiologically the presence of callus, and complications were seen .A neurological examination was performed to note recovery in case of a neural deficit being noted previously. Follow-up X-rays were done in the immediate post-operative period, at 3 weeks and at subsequent visits, to note any displacement, malalignment and fracture union . Finally, the functional outcome was assessed on the basis of Mitchell and Adams^[13] criteria .The outcome was considered excellent, when the elbow had normal shape and movement of the elbow with a change in carrying angle of less than 5 degrees and limitation of elbow movement of less than 10 degrees. Results were graded as good, when the change in the carrying angle was between 5-15 degrees and limitation of movement between 10-20 degrees. When the change in carrying angle was more than 15 degrees and limitation of movements more than 20 degrees, the results were considered poor.

III. Results

The Study involved 60 patients of Gartland type III supracondylar fractures of humerus , which were operated in Orthopaedic emergency department in our hospital . The age distribution of patients ranges from 2 to 12 years. Youngest was 2.5 while oldest was 11.5 years , with a peak incidence (nearly 50%) in the age group of 5 – 8 years. The mean age in the study was 6.75 years. The incidence of fracture is higher in boys with 43 (71.66 %) boys and 17 (28.33 %) girls . The left or nondominant side is most frequently injured involving 41 (68.33 %) cases and rest 19 (31.66 %) involve the dominant right side . Trauma in the form of fall (fall at home, school, while playing etc.) is present in 95% patients . Out of the 60 cases of type III supracondylar fractures of humerus, 46 (77%) cases had posteromedial and rest 14 (23%) cases had posterolateral displacement of the distal fragment. The incidence of pre-operative nerve injuries was 8.8% with radial and median nerve being involved equally with no ulnar nerve injury. In our series 38 (63.3 %) patients were treated with crossed pinning and 22 (36.7 %) patients with lateral pinning. Out of the 60 operated patients , 7 (11.66 %) faced complications in form of pin tract infection and ulnar nerve palsy . Out of the 7 complicated cases 4 (6.66 %) cases of pin tract infection and 3 (5%) cases of iatrogenic ulnar nerve injury were seen . Out of the 4 cases of pin tract infection , 1 is in lateral pinning and 3 in cross pinning . All the cases of iatrogenic ulnar nerve injury was seen in crossed pinning group. The average loss of range of movement was 8.4 degrees in the lateral pinning group and 7.2 degrees in the crossed pinning group, which was not statistically significant. The average change in carrying angle was 2.5 degrees for crossed pinning and 3.1 degrees for the lateral pinning group. The difference between the two groups was not statistically significant. The functional outcome was assessed on the basis of Mitchell and Adams^[13] criteria. There were 82% excellent and 18% good results in crossed pinning group and 71% excellent and 29% good results in lateral pinning group. The difference in functional outcome between the two groups was not statistically significant.

IV. Discussion

In this study, sixty children with type III supracondylar fractures of humerus who were treated with closed reduction and percutaneous crossed pinning (medial- lateral) or lateral pinning methods were evaluated both retrospectively and prospectively. In our study mean age was 6.75 years and peak incidence (nearly 50%) were in the age group of 5 – 8 years . The results match with study done by Wilkins^[5] , where peak incidence was between 5-8 years and an average age of 6.7 years. When male and female child involvement is concern our results of 71.66 % male and 28.33 % in females matches with series of Solak^[6] (males 72.8% and females 27.2 %) but slight differs from series of Wilkins^[5] (males 62.85% & females 37.15 %) . but in both the series male preponderance were noted , which is similar to our study. In Aronson and Prager^[7] non dominant left side is 2 times more commonly involved than right . Our results were similar , left side 2.15 times more commonly involved than right . The common mechanism of injury in our series was fall on an outstretched hand (95 %) which is same as that in series by Mostafavi^[8]. Incidence of posteromedial displacement is higher than posterolateral . In our series , we have 77% posteromedial and 23% postero-lateral displacements . Similar results were seen in study of other series of : Wilkins^[5] (75%) , Aronson and Prager^[7] (75%) and Mostafavi^[8] (82%). Wilkins^[5] study, incidence of pre operative nerve injury was 7.7% . Our study has similar results having a incidence of 8.8% (6 cases). Radial and median nerves were equally involved with no ulnar nerve involvement. Neurological recovery was complete in all cases by 3 to 4 months. The average hospital stay for a patient in our study was 4 days with a range of 1 to 14 days. The average hospital stay in other series were 3.4 days by Aronson and Prager^[7] and 4.2 days by Nacht et al^[9]. Incidence Of Pin tract infection with pin loosening in our series was 6.66% , similar to Mostafavi^[8] , were the incidence was 5%. Pin tract infection with pin loosening, necessitated earlier removal of 'K' wires (at 2 weeks). The infection was treated with

appropriate antibiotics and regular wound dressing. The above elbow slab was continued in these patients. Infection was fully eradicated in all 3 patients with the above measures. The loss of both the range of motion and the carrying angle were greater in these 4 patients, compared to those without infection. There were 3 cases of iatrogenic ulnar nerve palsy following medial pinning (5%). In one case, there was only paraesthesia along the ulnar nerve distribution, which subsided spontaneously in one week. In another case of nerve palsy, there were both motor and sensory deficits, but complete neurological recovery occurred by the end of 4 months. There were no iatrogenic nerve injuries following lateral pinning. The incidence of ulnar nerve injury with medial pinning in other series were - 8% in the series by Skaggs et al.^[10] and 5% in the series by Solak^[6]. Iatrogenic nerve injury almost always involves the ulnar nerve following the placement of the medial pin for crossed pinning. The incidence of ulnar nerve injury was reduced in our series by taking precautions such as inserting the lateral pin first and avoiding hyperflexion of elbow during medial pin placement. Minimum follow up period was 6 months. This time period was adequate to assess fracture union, malalignment, range of motion and recovery from nerve injuries. An average follow up period was 18 months, similar to the series by Aronson and Prager^[7] (17.2 months). Average time period required for radiological union was 7.6 weeks, similar to the series by Mostafavi^[8] where union occurred at an average of 7.2 weeks. The correlation between the type of pinning and functional outcome was made on the basis of change in the carrying angle and range of motion as compared to the normal side. In our series, the average change in carrying angle for cases treated with **lateral pinning** was 3.1 degrees (range: 0-8 degrees) with 5 patients having change of carrying angle between 5-8°. In the series by Aronson and Prager^[7], this was 2.2 degrees (range 0-8 degrees). The average change in carrying angle in cases treated by **crossed pinning** was 2.5 degrees with range of 0-7 degrees. 5 patients had loss of carrying angle between 5-7° in this group. The difference in the carrying angle between the two groups was not statistically significant. However, there was no cubitus varus deformity in either group in our series and patients were satisfied with the cosmetic appearance of their elbows. In the series by Davis et al.^[11] there was, as a whole, 13% incidence of cubitus varus. The slightly higher change of carrying angle in lateral pinning cases may be related to a comparatively less stable construct with two lateral pins compared to two crossed pins. Biomechanical studies by Zionts^[12] have demonstrated that crossed pinning is more stable than lateral pinning in rotational testing as well as varus and valgus loading. However, a series by Skaggs et al.^[10] demonstrated no clinical difference in stability between crossed and lateral pins. In our series, the average loss of range of movement was 7.2 degrees (range 0-16 degrees) for cases with crossed pinning. This compared favourably with series by Nacht et al.^[9] (7.8 degrees). For cases with lateral pinning, the average loss of range of movement was 8.4 degrees (range 0-14 degrees) which compares favourably with the series by Aronson and Prager^[7] which demonstrated a loss of range of movement of 10 degrees. The difference with regard to loss of range of movement between the two groups was not statistically significant (p=0.204) with both groups showing excellent or good range of movements. In our series, no significant improvement in range of motion was observed between the sixth month exam and the final follow-up exam. It is therefore inferred that no significant improvement in the range of motion could be obtained after the first six months following surgery. Functional outcome following two types of pinning was evaluated according to Mitchell and Adams^[13] criteria. In our series, the functional outcome following crossed medial – lateral pinning was excellent in 82% and good in 18% of cases. There were no poor results. This compared favourably with the series by Mostafavi^[8] with 88% excellent results. In our series cases treated with lateral pinning showed 71% excellent and 29% good results with no poor results. In the series by Aronson and Prager^[7] excellent results were found in 88% and good results in 12%.

V. Conclusion

In our study, we observed that closed reduction and percutaneous pinning is an excellent method of treatment of type III supracondylar fractures in children. Crossed medial and lateral pinning is the treatment of choice in these fractures, with careful technique which safeguards the ulnar nerve. We also observed that the lateral pinning is an equally good treatment especially for the grossly swollen elbows in which the medial epicondyle is barely palpable with increased risk of ulnar nerve injury during the placement of the medial pin. Both the methods offer consistently satisfactory functional and cosmetic results.

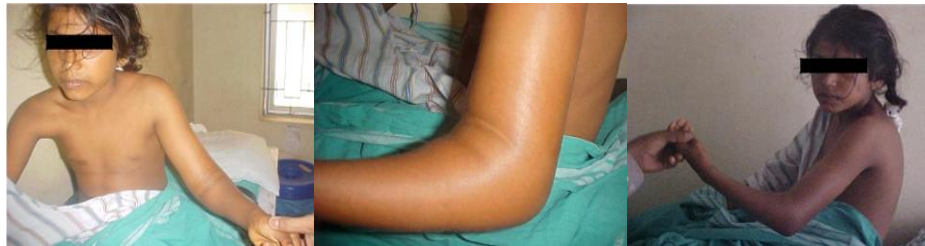Bibliography

- [1]. David L. Skaggs, John M. Flynn : Supracondylar Fractures of the Distal Humerus . In : James H . Beady, Jams H. Kasser . Rockwood And Wilkin's Fractures In Children , 7th Edition. Philadelphia ;Lippincott Williams & Wilkins ; 2010. pg487 .
- [2]. Houshian S, Mehdi B, Larsen MS. The epidemiology of elbow fracture in children: analysis of 355 fractures, with special reference to supracondylar humerus fractures. J Orthop Sci 2001;6:312-315.
- [3]. David L. Skaggs, John M. Flynn Supracondylar Fractures of the Distal Humerus .In : James H . Beady, Jams H. Kasser . Rockwood And Wilkin's Fractures In Children , 7th Edition. Philadelphia ;Lippincott Williams & Wilkins ; 2010. pg501 .
- [4]. David L. Skaggs, John M. Flynn Supracondylar Fractures of the Distal Humerus .In : James H . Beady, Jams H. Kasser . Rockwood And Wilkin's Fractures In Children , 7th Edition. Philadelphia ;Lippincott Williams & Wilkins ; 2010. pg502 .
- [5]. Wikins KE; The Operative management of supracondylar fractures, OrthopClin North Am, 1990; Vol.21 (2) : 269.

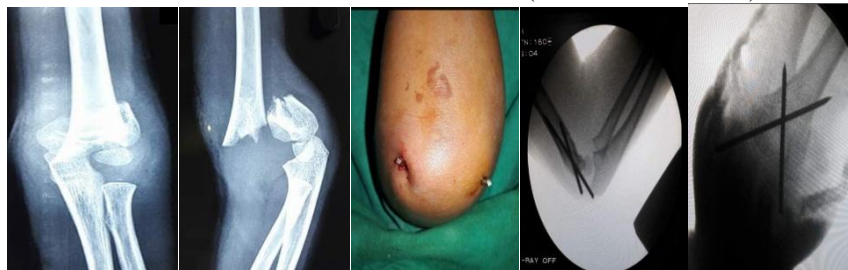- [6]. Solak, Sukru and Aydn, Erbil: Comparison of two percutaneous pinning methods for the treatment of paediatric type III Supracondylar humerus fractures. *J. Paediatr. Orthop* 2003; Part B 12(5) : 346-349.
- [7]. Aronson, D.D., and Prager P.I. : Supracondylar Fractures of the Humerus in Children : A Modified Technique for Closed Pinning. *Clin. Orthop.*, 1987; 219: 174-184.
- [8]. Mostafavi, Hamid R. and Spero, Charles: Crossed pin fixation of displaced supracondylar humerusfractures in children. *Clin. Orthop.* 2001; 1(376): 56-61.
- [9]. Nacht J., Ecker M., Chung S., et al : Supracondylar Fractures of the Humerus in Children Treated by Closed Reduction and Percutaneous Pinning *Clin. Orthop.*, 1983; 177: 203-209.
- [10]. Skaggs D L. et al. : Operative treatment of supracondylar fractures of humerus in Children – the consequences of pin placement?. *J. Bone Joint surs*, 2001; 83-A(5): 735-740.
- [11]. Davis R T. et al.; Supra condylar humerus fractures in children. Comparison of operative treatment methods. *ClinOrthop* 2000; 376: 49-55.
- [12]. Zionts L.E., Mc Kellop H.A and Hathaway R. : Torsional Strength of Pin Configurations Used to Fix Supracondylar Fractures of the Humerus in Children. *J. Bone Joint Surg.*, 1994; 76A: 253-256.
- [13]. Mitchell, W.J., and Adams, J.P : Supracondylar Fractures of the Humerus in Children. *J.A.M.A.*, 1961; 175:573-577.

PHOTOGRAPHS

**CLINICAL PHOTOGRAPH OF PATIENT (TYPE III SUPRACONDYLAR FRACTURE)
PRESENTING IN EMERGENCY**



ON TABLE FRACTURE FIXATION (CROSS PINNING)



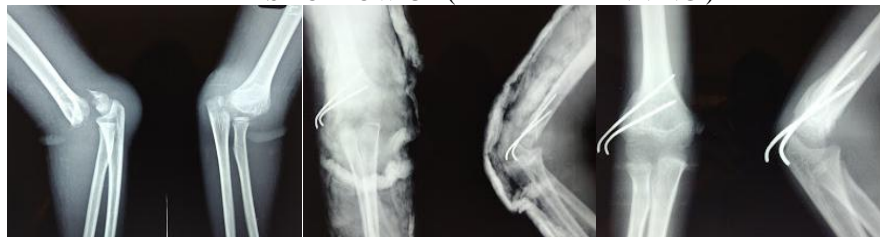AP & LATERAL VIEW

OR PICTURE

C ARM PICTURE OF FIXATION

OF FIXATION

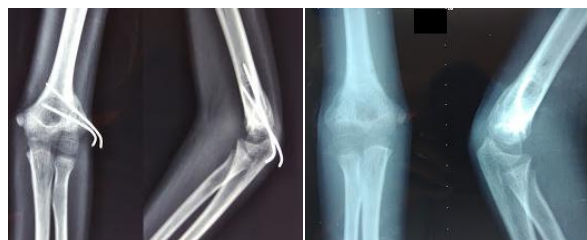
X RAYS FOLLOW UP (LATERAL PINNING)



PRE OPERATIVE

**IMMEDIATE POST
OPERATIVE**

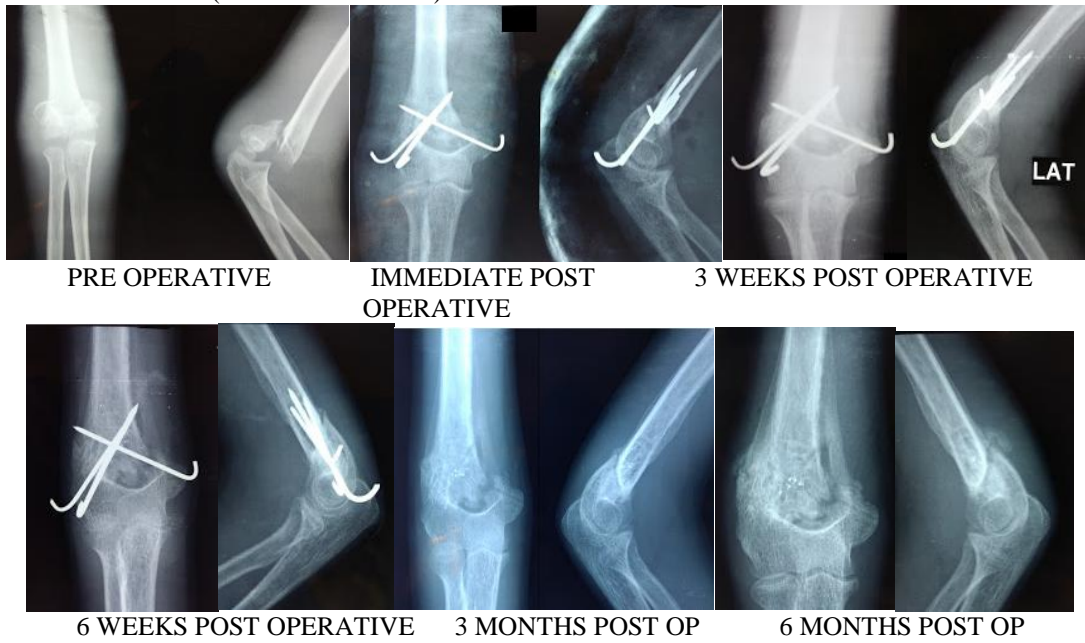3 WEEKS POST OPERATIVE



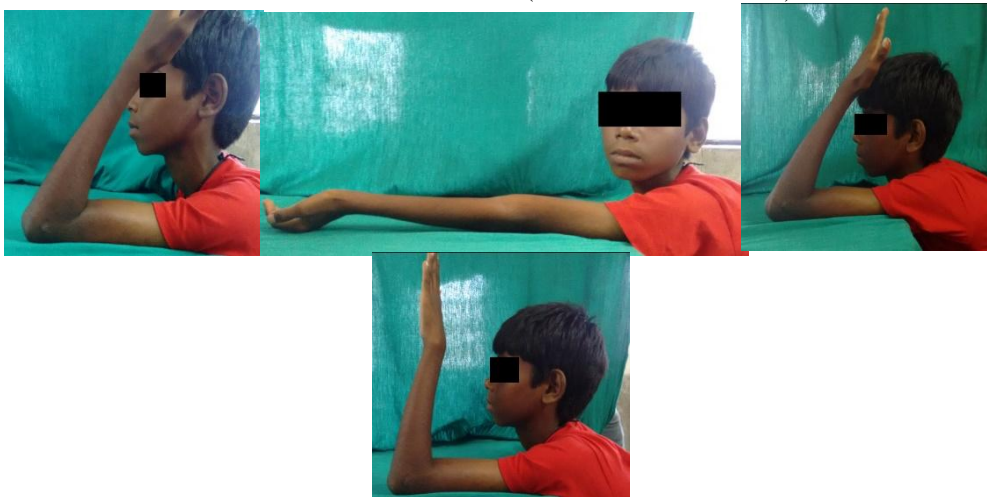6 WEEKS POST OPERATIVE

3 MONTHS POST OP

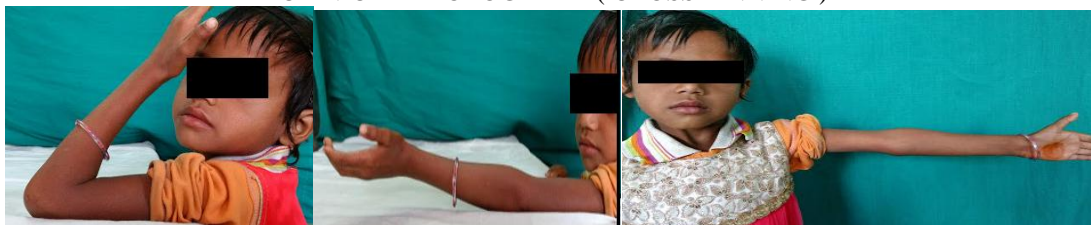X RAYS FOLLOW UP (CROSS PINNING)



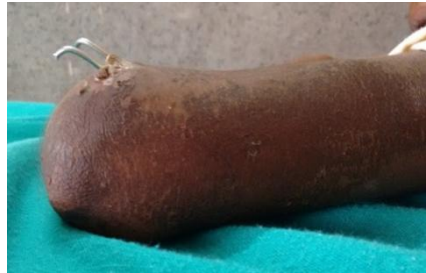CLINICAL PHOTOGRAPH (LATERAL PINNING)



CLINICAL PHOTOGRAPH (CROSS PINNING)



COMPLICATIONS



PIN TRACT INFECTION

Subrat Kumar Sahu" A Prospective Study of Early Postoperative Course And Pathological Outcome of Modified D2 Gastrectomy. ."IOSR Journal of Dental and Medical Sciences (IOSR-JDMS), vol. 17, no. 4, 2018, pp 07-13.