

Surgical Management of Spondylolisthesis by Pedicular Screw Rod System and Postero-Lateral Fusion

Dr. Ramesh Benguluri¹ & Dr. Chinnala Srujan Kumar²

1. Department Of Orthopaedics, Assistant Professor, Deccan College Of Medical Sciences (PEH).

2. Department Of Orthopaedics, Junior-Resident, Malla Reddy Institute Of Medical Sciences.

Corresponding author: Dr. Chinnala Srujan Kumar.

Abstract:

Introduction: Incidence of spondylolisthesis in general population is 5-7%. No matter what the etiology is, patients usually have significant functional disability. Few studies have investigated the long term effect of Postero Lateral Fusion on functional outcome.

Objectives: To study the efficacy of Postero Lateral Fusion in spondylolisthesis especially in terms of functional outcome.

Methodology: From July 2010 to June 2012, a total of 86 patients, operated with Postero Lateral Fusion were followed up and evaluated based on Visual Analogue for Pain (VAS) for low back pain, ODI and neurological deficits.

Results: Follow up was 83% of original study population (86). Average follow up was 13 months. The mean difference between pre operative and post operative VAS at final follow up was 3.5 cms (SD= 2.94); ODI was 28% at 4 months and 36% at 8 months. Claudication pain relieved in all; functional outcome was good in 67%, fair in 27.5% and failed in 5.5%; 75% had fusion at an average of 5.5 months.

Conclusion: PLF is still a safe, promising and appealing technique.

Keywords: Spondylolisthesis, Posterolateral Fusion (PLF), Functional Outcome.

Date of Submission: 28-03-2018

Date of acceptance: 12-04-2018

I. Introduction:

Spondylolisthesis is the subluxation of a vertebral body over another in the sagittal plane and is a relatively frequent mechanism of intervertebral instability^{1, 2}. Spondylolisthesis can be caused by ligamentous laxity, a defect in the pars interarticularis, previous surgery, or may be traumatic and occurs in up to 5% of the general population and affects all ages³. The surgical treatment of spondylolisthesis is indicated for cases of neurogenic claudication, intractable radicular pain, severe low back pain, presence of neurological symptoms, and failure of conservative management, radiological instability, progressive worsening of the listhesis, meyerding grade III and IV listhesis, and spondyloptosis^{2, 4-6}. The primary goal of spinal fusion is to remove pain generating tissues and to alleviate the patient's pain by stabilization of one or more motion segments⁷. Spinal fusion has been developed as a final course of progressive intents, which are designed to stabilize spine movement, reduce pain, and to moderate further degenerative change^{23, 24}. The goals of surgical treatment for lumbar spinal stenosis include relief of leg and back pain. Although decompression is a standard treatment regimen for the surgical treatment of lumbar spinal stenosis, additional fusion after extensive decompression can be required in many cases. In particular, an extensive facetectomy is needed for decompression of the foraminal stenosis in many cases. Thus, for cases of lumbar foraminal stenosis, a combination of neural decompression and spinal fusion can be performed to achieve the goals of surgical treatment. Lumbar spinal fusion is a common surgical treatment used in disc degeneration, which is related to chronic lower back pain and other spinal disorders, such as disc herniation, spondylolisthesis, facet arthropathy, and spinal stenosis²⁷. Since spinal arthrodesis was first reported 90 years ago, various techniques have been developed for lumbar spine fusion. Posterior lumbar fusion has the advantages that these are the purely dorsal approach thus avoiding the risks inherent to an anterior approach^{28, 29}. PLF construct reduces the postoperative segmental mobility and permits better graft incorporation³⁰. Posterior spinal decompression, stabilization and fusion are associated with acceptable postoperative complication rate when done under fluoroscopic guidance. The availability of intraoperative fluoroscopy and improved access to varieties of spinal titanium implants has revived posterior spinal stabilization techniques with their distinct advantages⁸. The present study was conducted to review our experience with Posterior Lumbar Fusions for the management of spondylolisthesis.

II Materials And Methods:

The present study was conducted in the department of Orthopedics, Narayana Medical College and general hospital, Chintareddy Palem, Nellore.

In present study we evaluated the outcome of surgical management of patients who were operated upon with posterior stabilization using pedicular screw rod system and postero lateral fusion for spondylolisthesis between July 2010 and June 2012 and followed up.

Inclusion Criteria:

- 1) Patients Age Between Of 20 – 75 Yrs.
- 2) Both Genders.
- 3)Patients Diagnosed With Spondylolysis And Spondylolisthesis With Failed Conservative Treatment

Exclusion Criteria:

- 1) Patients Of Age Less Than 20 Yrs And More Than 75 Yrs.
- 2) Patients With Grade–V Spondylolisthesis.
- 3) Patients Who Did Not Have A Regular Follow Up For A Minimum Period Of 6 Months.
- 4) Patients With Any Other Spinal Pathologies.
- 5) Patients Who Have Had Earlier Surgeries On Their Spine.

II. Results:

A total of 86 cases of spondylolisthesis were treated surgically by posterior stabilization using pedicular screw rod system and postero-lateral fusion. Of these cases, 72 cases turned up for follow up while 14 patients were lost to follow up.

Clinical Details:

Of the 86 patients that were followed up there were 58 females and 28 males. All patients were in the range of 20 years to 75 years with an average age at the time of surgery being 43 years. These patients have a duration of symptoms ranging from 1 month to 10 years with a mean time period of 28.6 months. The majority of the patients were housewives followed by those doing heavy manual work. All the 86 patients had low back pain; radicular pain present in 56 patients; neurological deficits present in 12 patients; claudication pain present in 36 patients. No involvement of bowel and bladder in any patient. All patients were requiring NSAID’s, bed rest, 45 patients underwent traction and physiotherapy for a variable periods with an average of 6 months. All patients have had paraspinal muscle spasm and spinal tenderness and had reduced spinal movements. Average pre-operative vas for low back pain was 7.8 and ODI was 52%.

Of total 86 patients:

- 1) 55 patients had instability at the level of L4–L5 and 31 had L5– S1 instability.
- 2) 44 patients had grade 1 slip, 34 patients had grade 2 slip and the rest 8 had grade 3 slip.

The patients had an average blood loss of about 250 ml. In our study there were no instrumentation failure, vascular injury and infection. Intra-operatively 8 (9.3%) patients had dural tear, 2 patients had pedicle failure leading to medial wall penetration and post operatively developed radicular pain on right side which was of new onset, hence was revised with removal of instrumentation. Dural tear was tackled by placing free fat graft and water tight closure of all layers.

Post–Operative Observations At Discharge:

The mean difference between pre operative and post operative VAS and ODI at discharge were 2.6 cm(SD=1.87)and 26% respectively. The mean difference of ODI and VAS was found to be more in males than females. Claudication pain was relieved in all patients. Neurological improvement was seen in 8 out of 12 patients. Sensory improvement was seen in 18 and blunting in 6 patients.

Post operatively grade of slip improved as 44 patients had grade 0, 28 patients had grade i and grade ii in 14 patients. Overall outcome had been graded into good, fair and failed depending on VAS, ODI, improvement in radiculopathy and neurological deficits.

Points	3	2	1
VAS Difference	>3.5	>3	<2.94
ODI Difference	>40%	10-40%	<10%
Radiculopathy	Absent	Ocassionally Present	Persisting
Neurological Deficits: Improvement	2 Grades	1 Grade	Not Improved

Maximum Score–12 And Minimum Score–4

The mean difference between pre operative and post operative ODI at 4 months follow up was 28% and 8 month follow up was found to be 36%. Re – Operation rates were 2.7% . Neurological deficits of new onset were 2.7 % compared to 5% in literatures. Pedicle failure was observed in 2.7% of patients. 10 Patients had post operatively low back pain, while 6 had radiculopathy and 4 had a limp. Whatever may be the score persistent radiculopathy is considered as failed response. Outcome score was good(≥ 10) in 48(67%), fair (5 – 10) in 20(27.5%) and failed (≤ 5) in 4(5.5%). Overall good outcome is significantly associated with more number of patients i.e.,67%. Good outcome was also significantly associated with 1)Younger age group. 2)Males. 3)strongly associated with lower grade of slip and 4) strongly associated with radiological fusion. It was found that there was no significant relation between level of instability and final clinical outcome. Clinical outcome (based on VAS for low back pain, ODI, radicular pain, neurological deficits and claudication) and spinal fusion was then assessed by plain lumbar spine radiographs at 2, 4, 8 and 12 months after operation.

III. Discussion:

Adult spondylolisthesis is a radiographically verifiable condition revealed by motion in lumbar segments. It is important to isolate the specific symptoms, signs, and functional disabilities that distinguish spondylolisthesis from other types of low-back pain and sciatica. Despite the conservative treatment previously received by many patients, their symptoms cannot be resolved^{43,64}. In numerous studies, the mean age of the patients being treated for isthmic type spondylolisthesis has ranged from 29.8 to 53.4 years⁴². In a study, the mean age was 47.3 years in patients who underwent PLF procedure. The duration of the symptoms ranged from 8 to 60 months, with a mean duration of 38.4 months. 43 in present study also we had females more than male patients and a mean age was 43 years. The patients have duration of symptoms ranging from 1 month to 10 years with a mean time period of 28.6 months. In accordance with the literature surgery was performed in patients who did not respond to conservative management or who develop neurological deficits at the time of presentation^{43,64}. In our series we had L4-L5 level (55 cases) involvement more than L5-S1 level (31 cases) and 44 patients had grade 1 slip, 34 patients had grade 2 slip and the rest 8 had grade 3 slip. Kim et al reported that 50% of the defective levels were L4-L5, and this ratio was similar to that found in our series (54%)⁴⁵. In a study, the vertebral levels at which the implants were inserted were as follows: L2-3 (one patient), L4-5 (25 patients), and L5-S1 (15 patients)⁴³. In one study, the most commonly affected level was L5-S1 followed by L4-5 and L3-L4 respectively⁴⁴. Dantas reported equal number (45%) of patients involving the L4-L5 and L5-S1 levels¹. Yan *et al* reported the L5-S1 affected rate of 52.27% and L4-L5 of 47.72%⁴⁷. Postero lateral fusion has been one of the standards for surgical treatment of lumbar spinal instability, and with the use of spinal instrumentation, it has been widely used for lumbar degenerative pathology¹²¹. 54 of the 72 patients (75%) had obtained bony fusion while 18 patients did not. The average time for bony fusion was 5.5 months with the earliest being 4 months and the latest 11 months. Good outcome was significantly associated with younger age group, male gender, lower grade of slip and radiological fusion group. However there was no significant relation between level of instability and final clinical outcome. In spondylolisthesis patients, concern for spinal biomechanics is the key to proper surgical management^{61,62}. Crawford et al. Reproduced the lumbar spondylolisthesis grade1 using cadaveric specimens and studied the biomechanics of various hardware combinations including cages with and without intersomatic spacers, pedicle screws alone, and pedicle screws with cages⁶³. The surgical treatment of choice for the management of spondylolisthesis remains a matter of controversy^{2,57,59,60} and an effective spondylolisthesis surgery involves fusion of the fewest possible segments, minimizes dislocation, achieves adequate decompression, corrects the sagittal axis, and accomplishes fusion^{47,58}. Suk et al performed decompression, pedicle screw fixation and fusion in 76 patients with symptomatic spondylolisthesis and a stenotic spinal canal. In the PLF group, the incidence of nonunion was 7.5%, whereas there was no nonunion in the PLIF group⁶². However, in a study it could not be concluded which operative technique (PLF, PLIF, anterior lumbar interbody fusion, or instrumentation) best accomplished fusion. In the management of low-grade isthmic spondylolisthesis, instrumentation, decompression, reduction, and fusion can all play a beneficial role⁴². In a prospective study, however, Kim et al could not find any differences among clinical outcomes and fusion ratios after observing PLF, PLIF, and combined PLF/ PLIF groups for 3 years. In addition, the PLIF-only group showed shorter operating times, lower blood loss, and no pain in the iliac wing (the donor site for bone fusion)⁴⁵. All the grade III listhesis were reduced to grade ii or i and grade ii were reduced to grade I or reduced completely. Grade i listhesis were reduced completely or in situ fixation was performed. In younger patient group the most common type of listhesis seen was dysplastic and in the elder group the degenerative type was the most common⁴⁴. Madan and boeree compared 23 patients treated with PLIF and 21 treated with PLF who also had instrumentation treatment. Satisfactory clinical outcomes were found at a rate of 69.5% in the PLIF group and 69.5% in the PLF group. In patients with low grade spondylolisthesis, they obtained better clinical results in the PLF group; however, the quality of fusion and correction was better in the PLIF group¹²². After 2 years of experience with PLF and PLIF, Elman et al reported that these 2 methods produced similar outcomes in the management of adult isthmus spondylolisthesis (with the exception of Higher Complication Rates When

Using The PLIF Method)¹²³. Patients With Adequate Fusion might have a better clinical outcome and vice versa¹²⁴. Some investigators have reported that the clinical outcomes for PLIF are no better than for other fusion techniques. In patients who underwent PLIF, the wider retraction of the nerve root and Thecal Sac Was Clearly disadvantageous because it induced leg pain¹²⁵⁻¹²⁷. An Oswestry index of 89% with good or excellent results in the PLIF patients, and 86% in PLF patients. The difference was not statistically significant. In a prospective randomized study on degenerative lumbar disease, three fusion methods: posterolateral fusion (PLF), posterior lumbar interbody fusion (PLIF), and PLIF combined with PLF (PLF+PLIF), were compared and there was no significant differences in clinical results and union rates among the three methods⁶⁰. The reported complications in the PLF patients are screw fractures and loosening of the implants and these may require reoperation. It is generally believed that reduction at operation is not required for patients with symptomatic grades 1 and 2 spondylolisthesis. Complication rates were reportedly higher in patients who received reduction at operation¹²⁸⁻¹³¹. Although a sound fusion is thought to be a parameter for clinical success in patients with mechanical LBP, however, the fusion rates did not correlate with the clinical outcomes in patients¹³².

In a prospective study, our aim was to compare the clinical outcome of posterior lumbar interbody fusion (PLIF) and posterolateral fusion (PLF) in spondylolisthesis. Radiography was performed preoperatively and postoperatively to assess the fusion. Both surgical procedures were effective, but the PLF group showed more complications related to hardware biomechanics. The PLIF group presented a better fusion rate than PLF group but there was no significant statistical difference in clinical and functional outcome in the two groups¹³³. Swan et al investigated 2 groups with low-grade isthmic spondylolisthesis; they treated the first group (50 consecutive patients) using 1-level posterior instrumentation and PLF, and they treated the second group (50 consecutive patients) with both anterior lumbar interbody fusion and PLF. At the 2nd year postoperatively, a clinical examination demonstrated that the patients who received the combined anteroposterior treatment showed more correction of their unstable spondylolisthesis than patients who only received posterior treatment¹³⁴. The complications associated with the spine procedure include permanent neurological

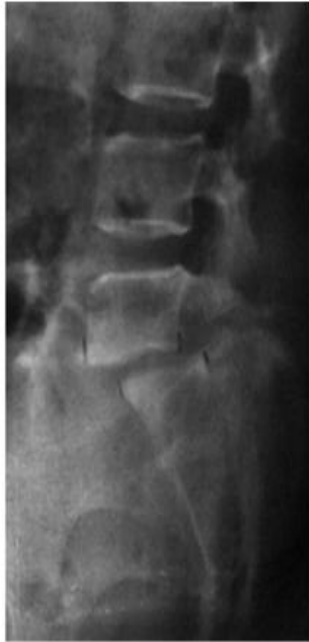Deficit in 0.4%-1.7%, csf leakage in 0.4%-0.5%, radicular pain in 1.1%-2.5%, and deep wound infection in 0.6%-5% of patients¹³⁵. The complication rates associated with PLIF are higher than those with PLF and, technically, PLF is easier to perform^{57,64,136}. In comparison to PLIF, the PLF has less blood loss and PLIF procedure considered to be difficult due to the increased bleeding, prolonged operation time, and more extensive dissection². Cerebrospinal fluid (CSF) leaks can occur as a result of spine surgery or trauma. These leaks represent serious problems because of persistent headaches and the possibility of meningitis. Surgical management is often needed and requires meticulous direct closure of the dura or closure by means of a fascial graft¹³⁷. Based on findings it was concluded that if there is instability affecting the three-column spine in spondylolisthesis, posterior interbody fusion with pedicle screws (PLIF) provides a more solid mechanical construction when compared with the pedicle screws used alone. Both surgical procedures were effective, although the PLF group showed more complications related to hardware biomechanics. Clinical and functional outcomes in both groups were similar, and no significant statistical difference was found. But PLIF presented better fusion rate when compared with PLF. Lumbar spondylolisthesis is a heterogeneous disorder characterised by the forward displacement of one vertebra on another. Conservative treatment for segmental instability is possible for patients with tolerable pain. Surgery is indicated if symptoms are disabling and interfere with work, if the condition is progressive, or if there is a significant neurological deficit⁵⁷. Postero lateral fusion can be a option for the management of lumbar spondylolisthesis. However this study has limitations as the number of patients included was relatively small and studies with larger numbers of patients are required. With advances in minimal access technology using operating microscope, in future the present technique can be compared with other approaches providing an adequate decompression and circumferential fusion, and avoid many of the disadvantages of the traditional posterior open approach for degenerative spondylolisthesis.

IV. Conclusions:

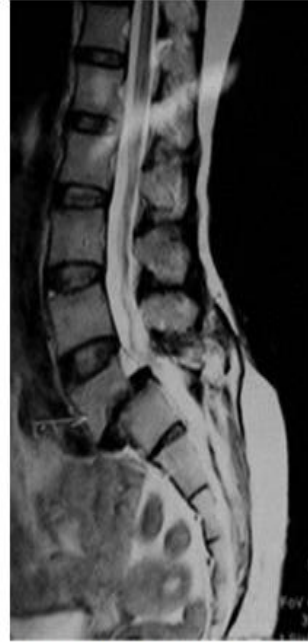Spondylolisthesis is a common condition that is seen in orthopedic practice for low back pain. To treat this many surgical and non-surgical methods have been described in literature. Surgical decompression and spinal stabilization is recommended for those patients who fail to respond to conservative management or who have significant spinal instability. Different techniques i.e. anterior, posterior and or combined approached have been used for various underlying degree of spondylolisthesis. Postero-lateral lumbar fusion and spinal decompression is an effective method in the treatment of spondylolisthesis, as it provided good spinal fusion, less complication with satisfactory clinical outcome. Although the surgical fixation of spondylolisthesis using pedicular screw rod system and posterolateral graft with decompression is a safe, promising and appealing technique especially in low grade listhesis, there is a need to study, adopt and PLIF, TLIF and ALIF procedures to produce better clinical results and in high grade spondylolisthesis. Based on our findings we conclude that spondylolisthesis was one of the most common indications for posterior spinal decompression, stabilization and postero lateral fusion (PLF) at our center. Surgical procedures were effective with fewer complications related

to hardware biomechanics. The surgical procedure was associated with minimal postoperative complications particularly when performed under fluoroscopic guidance. Good outcome was mainly related to the preoperative neurological deficits and the degree of slip. Apart from the surgical management, modification of the lifestyle is also recommended to avoid failure of surgery. Although short-term results from studies are promising, the number of patients included was relatively small and studies with larger numbers of patients are required.

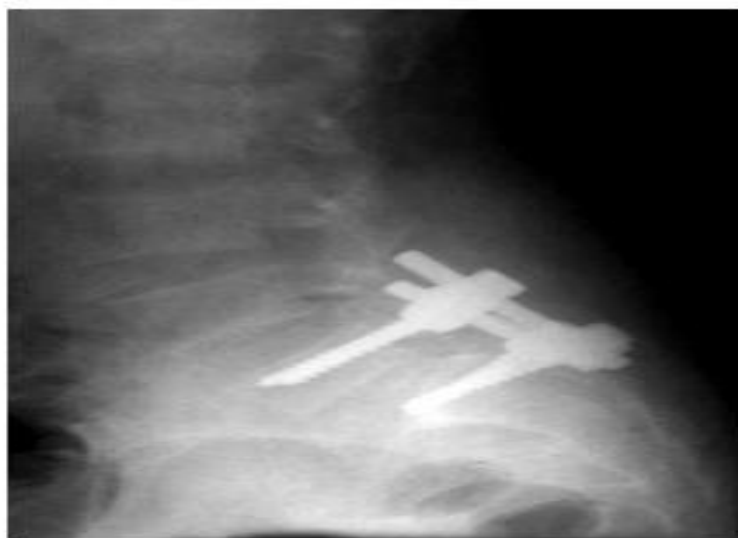Case 1:



PRE OF X-RAY LS SPINE LATERAL VIEW

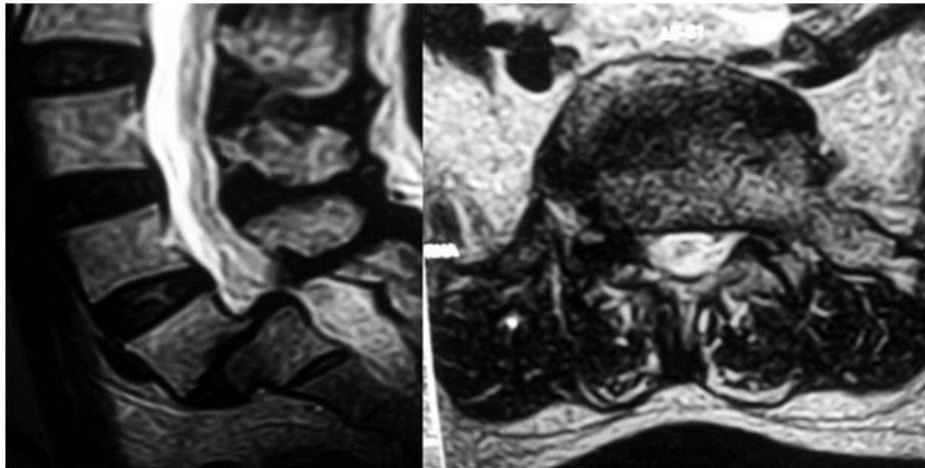


MRI SAGITAL CUT LS SPINE

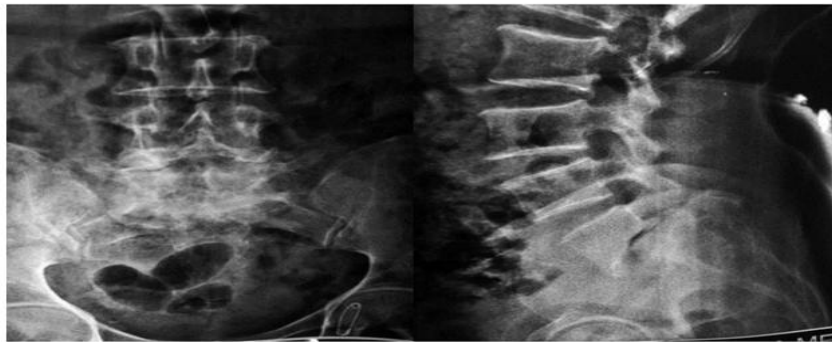


POST OP-LS SPINE LATERAL VIEW AT 6 MONTHS

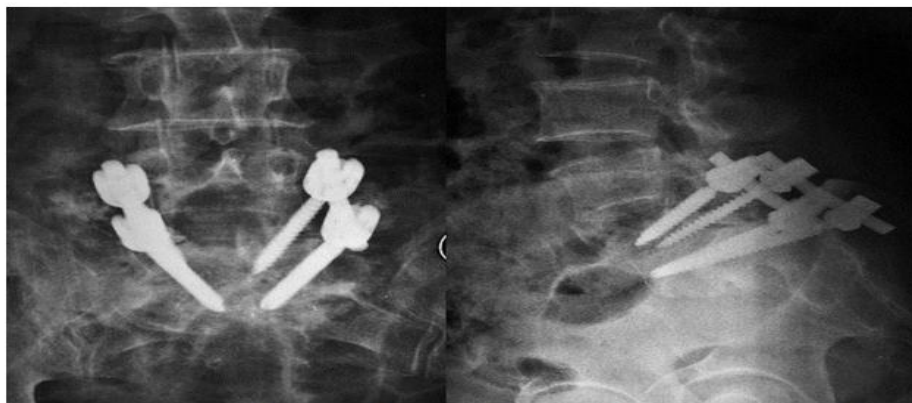
Case 2:



PRE OF MRI SAGITAL & AXITAL CUTS



PRE-OP X-RAY LS SPINE A.P. & LATERAL VIEW



POST OPERATIVE X-RAY LS SPINE A.P. LATERAL VIEWS AT 6 MONTHS

References:

- [1]. Dantas Flr, Prandini Mn, Ferreira Mat. Comparison Between Posterior Lumbar Fusion With Pedicle Screws And Posterior Lumbar Interbody Fusion With Pedicle Screws In Adult Spondylolisthesis. *Arquivos De Neuro-Psiquiatria* 2007;65:764-770.
- [2]. Dai Ly, Jia Ls, Yuan W, Ni B, Zhu Hb. Direct Repair Of Defect In Lumbar Spondylolysis And Mild Isthmic Spondylolisthesis By Bone Grafting, With Or Without
- [3]. Facet Joint Fusion. *European Spine Journal : Official Publication Of The European Spine Society, The European Spinal Deformity Society, And The European Section Of The Cervical Spine Research Society* 2001;10:78-83.
- [4]. Frymoyer J, Selby D. Segmental Instability. Rationale For Treatment. *Spine* 1985;10:280.
- [5]. Roy-Camille R, Roy-Camille M, Demeulenaere C. [Osteosynthesis Of Dorsal, Lumbar, And Lumbosacral Spine With Metallic Plates Screwed Into Vertebral Pedicles And Articular Apophyses]. *La Presse Medicale* 1970;78:1447-1448.
- [6]. Zdeblick Ta. A Prospective, Randomized Study Of Lumbar Fusion. Preliminary Results. *Spine* 1993;18:983-991.
- [7]. Feffer HI, Wiesel Sw, Cuckler Jm, Rothman Rh. Degenerative Spondylolisthesis. To Fuse Or Not To Fuse. *Spine* 1985;10:287-289.

- [8]. Fuji T, Oda T, Kato Y, Fujita S, Tanaka M. Posterior Lumbar Interbody Fusion Using Titanium Cylindrical Threaded Cages: Is Optimal Interbody Fusion Possible Without Other Instrumentation? *Journal Of Orthopaedic Science : Official Journal Of The Japanese Orthopaedic Association* 2003;8:142-147.
- [9]. Idowu Oe, Adewole Oa, Majekodunmi Aa. Posterior Spinal Decompression, Stabilization And Arthrodesis In Nigerian Adults: Profile And Outcome. *Nigerian Medical Journal : Journal Of The Nigeria Medical Association* 2012;53:42-46.
- [10]. Janssen Me, Lam C, Beckham R. Outcomes Of Allogenic Cages In Anterior And Posterior Lumbar Interbody Fusion. *European Spine Journal : Official Publication Of The European Spine Society, The European Spinal Deformity Society, And The European Section Of The Cervical Spine Research Society* 2001;10 Suppl 2:S158-168.
- [11]. Agazzi S, Reverdin A, May D. Posterior Lumbar Interbody Fusion With Cages: An Independent Review Of 71 Cases. *Journal Of Neurosurgery* 1999;91:186-192.
- [12]. Burkus Jk, Dorchak Jd, Sanders Dl. Radiographic Assessment Of Interbody Fusion Using Recombinant Human Bone Morphogenetic Protein Type 2. *Spine* 2003;28:372-377.
- [13]. Chitnavis B, Barbagallo G, Selway R, Dardis R, Hussain A, Gullan R. Posterior Lumbar Interbody Fusion For Revision Disc Surgery: Review Of 50 Cases In Which Carbon Fiber Cages Were Implanted. *Journal Of Neurosurgery* 2001;95:190-195.
- [14]. Hashimoto T, Shigenobu K, Kanayama M, Et Al. Clinical Results Of Single-Level Posterior Lumbar Interbody Fusion Using The Brantigan I/F Carbon Cage Filled With A Mixture Of Local Morselized Bone And Bioactive Ceramic Granules. *Spine* 2002;27:258-262.
- [15]. Janssen Me, Nguyen C, Beckham R, Larson A. Biological Cages. *European Spine Journal : Official Publication Of The European Spine Society, The European Spinal Deformity Society, And The European Section Of The Cervical Spine Research Society* 2000;9 Suppl 1:S102-109.
- [16]. Sasso Rc, Kitchel Sh, Dawson Eg. A Prospective, Randomized Controlled Clinical Trial Of Anterior Lumbar Interbody Fusion Using A Titanium Cylindrical Threaded Fusion Device. *Spine* 2004;29:113-122; Discussion 121.
- [17]. Cloward Rb. The Treatment Of Ruptured Lumbar Intervertebral Discs By Vertebral
- [18]. Body Fusion. I. Indications, Operative Technique, After Care. *Journal Of Neurosurgery*
- [19]. 1953;10:154-168.
- [20]. Brunon J, Chazal J, Chirossel Jp, Et Al. When Is Spinal Fusion Warranted In Degenerative Lumbar Spinal Stenosis? *Revue Du Rhumatisme (English Ed)* 1996;63:44- 50.
- [21]. Kim E-H, Kim H-T. En Bloc Partial Laminectomy And Posterior Lumbar Interbody Fusion In Foraminal Spinal Stenosis. *Asian Spine Journal* 2009;3:66-72.
- [22]. Postacchini F. Surgical Management Of Lumbar Spinal Stenosis. *Spine* 1999;24:1043-1047.
- [23]. Postacchini F, Cinotti G, Perugia D, Gumina S. The Surgical Treatment Of Central Lumbar Stenosis. Multiple Laminotomy Compared With Total Laminectomy. *The Journal Of Bone And Joint Surgery British Volume* 1993;75:386-392.
- [24]. Sanderson Pl, Getty Cj. Long-Term Results Of Partial Undercutting Facetectomy For Lumbar Lateral Recess Stenosis. *Spine* 1996;21:1352-1356.
- [25]. Simmons Eh, Capicotto Wn. Posterior Transpedicular Zielke Instrumentation Of The Lumbar Spine. *Clinical Orthopaedics And Related Research* 1988:180-191.
- [26]. Burkus Jk, Gornet Mf, Dickman Ca, Zdeblick Ta. Anterior Lumbar Interbody Fusion Using Rbmp-2 With Tapered Interbody Cages. *Journal Of Spinal Disorders & Techniques* 2002;15:337-349.
- [27]. Sasso Rc, Lehuac Jc, Shaffrey C, Spine Interbody Research G. Iliac Crest Bone Graft Donor Site Pain After Anterior Lumbar Interbody Fusion: A Prospective Patient Satisfaction Outcome Assessment. *Journal Of Spinal Disorders & Techniques* 2005;18 Suppl:S77-81.
- [28]. Carreon Ly, Puno Rm, Dimar Jr, Glassman Sd, Johnson Jr. Perioperative Complications Of Posterior Lumbar Decompression And Arthrodesis In Older Adults. *The Journal Of Bone And Joint Surgery American Volume* 2003;85-A:2089-2092.
- [29]. Cho K-J, Suk S-I, Park S-R, Et Al. Short Fusion Versus Long Fusion For Degenerative Lumbar Scoliosis. *European Spine Journal : Official Publication Of The European Spine Society, The European Spinal Deformity Society, And The European Section Of The Cervical Spine Research Society* 2008;17:650-656.
- [30]. Zhang Qh, Teo Ec. Finite Element Application In Implant Research For Treatment Of Lumbar Degenerative Disc Disease. *Medical Engineering & Physics* 2008;30:1246- 1256.
- [31]. Brantigan Jw, Steffee Ad, Lewis Ml, Quinn Lm, Persenaire Jm. Lumbar Interbody Fusion Using The Brantigan I/F Cage For Posterior Lumbar Interbody Fusion And The Variable Pedicle Screw Placement System: Two-Year Results From A Food And Drug Administration Investigational Device Exemption Clinical Trial. *Spine* 2000;25:1437- 1446.
- [32]. Csécei Gi, Klekner Ap, Dobai J, Lajgut A, Sikula J. Posterior Interbody Fusion Using Laminectomy Bone And Transpedicular Screw Fixation In The Treatment Of Lumbar Spondylolisthesis. *Surgical Neurology* 2000;53:2-6; Discussion 6.
- [33]. Panjabi Mm. Biomechanical Evaluation Of Spinal Fixation Devices: I. A Conceptual Framework. *Spine* 1988;13:1129-1134.
- [34]. Wright P, Canale S, Beaty J. Campbell's Operative Orthopaedics. *Campbell's Operative Orthopaedics* 2003.
- [35]. Et Renault R. Origine Et Developpement Des Os. *Acc D'un Atlas Grand In* 1864;4.
- [36]. McBride Ed. A Mortised Transfacet Bone Block For Lumbosacral Fusion. *The Journal Of Bone & Joint Surgery* 1949;31:385-399.
- [37]. Roche Mb, Rowe Gg. Anomalous Centers Of Ossification For Inferior Articular
- [38]. Processes Of The Lumbar Vertebrae. *The Anatomical Record* 1951;109:253-259.
- [39]. Hitchcock Hh. Spondylolisthesis Observations On Its Development, Progression, And Genesis. *The Journal Of Bone And Joint Surgery (American)* 1940;22:1-16.
- [40]. Wiltse Ll. Etiology Of Spondylolisthesis. *Clinical Orthopaedics* 1957;10:48.
- [41]. Möller H, Sundin A, Hedlund R. Symptoms, Signs, And Functional Disability In Adult Spondylolisthesis. *Spine* 2000;25:683-689; Discussion 690.
- [42]. Wiltse Ll, Newman P, Macnab I. Classification Of Spondylois And Spondylolisthesis. *Clinical Orthopaedics And Related Research* 1976;117:23-29.
- [43]. Marchetti P, Bartolozzi P. Spondylolisthesis: Classification And Etiopathogenesis. *Progress In Spinal Pathology: Spondylolisthesis Ii Italian Scoliosis Research Group, Bologna* 1986.
- [44]. Soini J, Laine T, Pohjolainen T, Hurri H, Alaranta H. Spondylolysis Augmented By Transpedicular Fixation In The Treatment Of Olisthetic And Degenerative Conditions Of The Lumbar Spine. *Clinical Orthopaedics And Related Research* 1993:111-111.
- [45]. Abumi K, Panjabi Mm, Kramer Km, Duranceau J, Oxland T, Crisco Jj. Biomechanical Evaluation Of Lumbar Spinal Stability After Graded Facetectomies. *Spine* 1990;15:1142.

- [46]. Jacobs Wch, Vreeling A, De Kleuver M. Fusion For Low-Grade Adult Isthmic Spondylolisthesis: A Systematic Review Of The Literature. *European Spine Journal* : Official Publication Of The European Spine Society, The European Spinal Deformity Society, And The European Section Of The Cervical Spine Research Society 2006;15:391-402.
- [47]. Ganju A. Isthmic Spondylolisthesis. *Neurosurgical Focus* 2002;13:E1.
- [48]. Stauffer Rn, Coventry Mb. Posterolateral Lumbar-Spine Fusion. *Analysis Of Mayo Clinic Series. The Journal Of Bone And Joint Surgery American Volume* 1972;54:1195-1204.
- [49]. Kim J-S, Lee K-Y, Lee S-H, Lee H-Y. Which Lumbar Interbody Fusion Technique Is Better In Terms Of Level For The Treatment Of Unstable Isthmic Spondylolisthesis? *Journal Of Neurosurgery Spine* 2010;12:171-177.
- [50]. Ming-Li F, Hui-Liang S, Yi-Min Y, Huai-Jian H, Qing-Ming Z, Cao L. Analysis Of Factors Related To Prognosis And Curative Effect For Posterolateral Fusion Of Lumbar Low-Grade Isthmic Spondylolisthesis. *International Orthopaedics* 2009;33:1335-1340.
- [51]. Yan D-L, Pei F-X, Li J, Soo C-L. Comparative Study Of Pflf And Tlif Treatment
- [52]. In Adult Degenerative Spondylolisthesis. *European Spine Journal* : Official Publication Of The European Spine Society, The European Spinal Deformity Society, And The European Section Of The Cervical Spine Research Society 2008;17:1311-1316.
- [53]. Laurent Le, Einola S. Spondylolisthesis In Children And Adolescents. *Acta Orthopaedica Scandinavica* 1961;31:45-64.
- [54]. Terry Y, Lindsay R. *Essentials Of Skeletal Radiology*. Williams And Wilkins 1987.
- [55]. Albee Fh. Transplantation Of A Portion Of The Tibia Into The Spine For Pott's Disease A Preliminary Report. *Journal Of The American Medical Association* 1911;57:885-886.
- [56]. Bohlman Hh, Cook Ss. One-Stage Decompression And Posterolateral And Interbody Fusion For Lumbosacral Spondyloptosis Through A Posterior Approach. *Report Of Two Cases. The Journal Of Bone And Joint Surgery American Volume* 1982;64:415-418.
- [57]. Boriani S, Weinstein Jn, Biagini R. Primary Bone Tumors Of The Spine. *Terminology And Surgical Staging. Spine* 1997;22:1036-1044.
- [58]. Bradford Ds, Ahmed Kb, Moe Jh, Winter Rb, Lonstein Je. The Surgical Management Of Patients With Scheuermann's Disease: A Review Of Twenty-Four Cases Managed By Combined Anterior And Posterior Spine Fusion. *The Journal Of Bone And Joint Surgery American Volume* 1980;62:705-712.
- [59]. Cheng Bc, Gordon J, Cheng J, Welch Wc. Immediate Biomechanical Effects Of Lumbar Posterior Dynamic Stabilization Above A Circumferential Fusion. *Spine* 2007;32:2551-2557.
- [60]. Kumar A, Beastall J, Hughes J, Et Al. Disc Changes In The Bridged And Adjacent Segments After Dynesys Dynamic Stabilization System After Two Years. *Spine* 2008;33:2909-2914.
- [61]. Hibbs Ra. A Report Of Fifty-Nine Cases Of Scoliosis Treated By The Fusion Operation. *The Journal Of Bone & Joint Surgery* 1924;6:3-34.
- [62]. Inamdar Dn, Alagappan M, Shyam L, Devadoss S, Devadoss A. Posterior Lumbar Interbody Fusion Versus Intertransverse Fusion In The Treatment Of Lumbar Spondylolisthesis. *Journal Of Orthopaedic Surgery (Hong Kong)* 2006;14:21-26.
- [63]. Spruit M, Pavlov Pw, Leitao J, De Kleuver M, Anderson Pg, Den Boer F. Posterior Reduction And Anterior Lumbar Interbody Fusion In Symptomatic Low-Grade Adult Isthmic Spondylolisthesis: Short-Term Radiological And Functional Outcome. *European Spine Journal* : Official Publication Of The European Spine Society, The European Spinal Deformity Society, And The European Section Of The Cervical Spine Research Society 2002;11:428-433.
- [64]. Kant Ap, Daum Wj, Dean Sm, Uchida T. Evaluation Of Lumbar Spine Fusion. *Plain Radiographs Versus Direct Surgical Exploration And Observation. Spine* 1995;20:2313-2317.
- [65]. Kim Ki, Kim Sr, Sasase N, Et Al. 2'-,5'-Oligoadenylate Synthetase Response Ratio Predicting Virological Response To Peg-Interferon-Alpha2b Plus Ribavirin Therapy In Patients With Chronic Hepatitis C. *Journal Of Clinical Pharmacy And Therapeutics* 2006;31:441-446.
- [66]. Brantigan Jw, Neidre A. Achievement Of Normal Sagittal Plane Alignment Using A Wedged Carbon Fiber Reinforced Polymer Fusion Cage In Treatment Of Spondylolisthesis. *The Spine Journal* : Official Journal Of The North American Spine Society 2003;3:186-196.
- [67]. Suk Si, Lee Ck, Kim Wj, Lee Jh, Cho Kj, Kim Hg. Adding Posterior Lumbar Interbody Fusion To Pedicle Screw Fixation And Posterolateral Fusion After Decompression In Spondylolytic Spondylolisthesis. *Spine* 1997;22:210-219; Discussion 219.
- [68]. Crawford Nr, Cagli S, Sonntag Vk, Dickman Ca. Biomechanics Of Grade I Degenerative Lumbar Spondylolisthesis. Part 1: In Vitro Model. *Journal Of Neurosurgery* 2001;94:45-50.
- [69]. Fraser Rd. Interbody, Posterior, And Combined Lumbar Fusions. *Spine* 1995;20:167s-177s.
- [70]. Gill Gg, Manning Jg, White Hl. Surgical Treatment Of Spondylolisthesis Without Spine Fusion Excision Of The Loose Lamina With Decompression Of The Nerve Roots. *The Journal Of Bone And Joint Surgery (American)* 1955;37:493-520.
- [71]. Capener N. Spondylolisthesis. 1932.
- [72]. Friberg S. *Studies On Spondylolisthesis* 1939.
- [73]. Verbiest H. . Impending Lumbar Spondyloptosis. *Problems With Posterior Decompression And Foraminotomy: Treatment By Anterior Lumbosacral Console Fusion. Clinical Neurosurgery* 1973;20:197.
- [74]. Niggemeyer O, Strauss J, Schulitz K. Comparison Of Surgical Procedures For Degenerative Lumbar Spinal Stenosis: A Meta-Analysis Of The Literature From 1975 To 1995. *European Spine Journal* 1997;6:423-429.
- [75]. Snijder J, Seroo J, Snijder C, Schijvens A. Therapy Of Spondylolisthesis By Repositioning And Fixation Of The Olisthetic Vertebra. *Clin Orthop* 1976;117:149-156.
- [76]. Harrington Pr, Dickson Jh. Spinal Instrumentation In The Treatment Of Severe Progressive Spondylolisthesis. *Clin Orthop* 1976;117:157-163.
- [77]. Buck J. Direct Repair Of The Defect In Spondylolisthesis Preliminary Report. *Journal Of Bone & Joint Surgery, British Volume* 1970;52:432-437.
- [78]. Deguchi M, Rapoff Aj, Zdeblick Ta. Posterolateral Fusion For Isthmic Spondylolisthesis In Adults: Analysis Of Fusion Rate And Clinical Results. *Journal Of Spinal Disorders* 1998;11:459-464.
- [79]. Blume Hg. Unilateral Posterior Lumbar Interbody Fusion: Simplified Dowel Technique. *Clinical Orthopaedics And Related Research* 1985;193:75-84.
- [80]. Harms J, Jeszenszky D. The Unilateral Transforaminal Approach For Posterior Lumbar Interbody Fusion. *Orthop Traumatol* 1998;6:88-99.
- [81]. Fischgrund Js, Mackay M, Herkowitz Hn, Brower R, Montgomery Dm, Kurz Lt. 1997 Volvo Award Winner In Clinical Studies. Degenerative Lumbar Spondylolisthesis With Spinal Stenosis: A Prospective, Randomized Study Comparing Decompressive Laminectomy And Arthrodesis With And Without Spinal Instrumentation. *Spine* 1997;22:2807-2812.

- [83]. Huang K-F, Chen T-Y. Clinical Results Of A Single Central Interbody Fusion Cage And Transpedicle Screws Fixation For Recurrent Herniated Lumbar Disc And Low-Grade Spondylolisthesis. *Chang Gung Medical Journal* 2003;26:170-177.
- [84]. Enker P, Steffee Ad. Interbody Fusion And Instrumentation. *Clinical Orthopaedics And Related Research* 1994;90-101.
- [85]. Evans Jh. Biomechanics Of Lumbar Fusion. *Clinical Orthopaedics And Related Research* 1985:38-46.
- [86]. King D. Internal Fixation For Lumbosacral Fusion. *The Journal Of Bone And Joint Surgery (American)* 1948;30:560-578.
- [87]. Boucher H. A Method Of Spinal Fusion. *The Journal Of Bone And Joint Surgery British Volume* 1959;41:248.
- [88]. Andrew T, Piggott H. Growth Arrest For Progressive Scoliosis. Combined Anterior And Posterior Fusion Of The Convexity. *Journal Of Bone & Joint Surgery, British Volume* 1985;67:193-197.
- [89]. Jacobs R, Montesano Px, Jackson Rp. Enhancement Of Lumbar Spine Fusion By Use Of Translaminar Facet Joint Screws. *Spine* 1989;14:12.
- [90]. Roy-Camille R, Roy-Camille M, Demeulenaere C. [Osteosynthesis Of Dorsal, Lumbar, And Lumbosacral Spine With Metallic Plates Screwed Into Vertebral Pedicles And Articular Apophyses]. *La Presse Medicale* 1970;78:1447.
- [91]. Magerl F. External Skeletal Fixation Of The Lower Thoracic And The Lumbar Spine. *Current Concepts Of External Fixation Of Fractures* New York, Springer Verlag 1982:353-366.
- [92]. Dick Jc, Brodke Ds, Zdeblick Ta, Bartel Bd, Kunz Dn, Rapoff Aj. Anterior Instrumentation Of The Thoracolumbar Spine: A Biomechanical Comparison. *Spine* 1997;22:744-750.
- [93]. Olerud S, Sjöström L, Karlström G, Hamberg M. Spontaneous Effect Of Increased Stability Of The Lower Lumbar Spine In Cases Of Severe Chronic Back Pain. The Answer Of An External Transpeduncular Fixation Test. *Clin Orthop* 1986;203:67-74.
- [94]. Baumgart F, Bensmann G, Haasters J, Et Al. Method For Implanting And Subsequently Removing Mechanical Connecting Elements From Living Tissue. Google Patents, 1979.
- [95]. Steffee Ad, Biscup Rs, Sitkowski D. Segmental Spine Plates With Pedicle Screw Fixation. *Clin Orthop* 1986;203.
- [96]. Horowitch A, Peek Rd, Thomas Jr Jc, Et Al. The Wiltse Pedicle Screw Fixation System. Early Clinical Results. *Spine* 1989;14:461.
- [97]. Harrington Pr, Dickson Jh. Spinal Instrumentation In The Treatment Of Severe Progressive Spondylolisthesis. *Clinical Orthopaedics And Related Research* 1976:157-163.
- [98]. Hu Ss, Bradford Ds, Transfeldt Ee, Cohen M. Reduction Of High-Grade Spondylolisthesis Using Edwards Instrumentation. *Spine* 1996;21:367-371.
- [99]. Mcqueen Mm, Court-Brown C, Scott Jh. Stabilisation Of Spondylolisthesis Using Dwyer Instrumentation. *The Journal Of Bone And Joint Surgery British Volume* 1986;68:185-188.
- [100]. O'rouke Mr, Grobler Lj. L4-L5 Degenerative Spondylolisthesis: Indications And Technique For Operative Management. *The Iowa Orthopaedic Journal* 1998;18:76.
- [101]. Farrokhi Mr, Rahmanian A, Masoudi Ms. Posterolateral Versus Posterior Interbody Fusion In Isthmic Spondylolisthesis. *Journal Of Neurotrauma* 2012;29:1567-1573.
- [102]. Matthiass H, Heine J. The Surgical Reduction Of Spondylolisthesis. *Clin Orthop* 1986;203:34-44.
- [103]. Suk Ks, Jeon Ch, Park Ms, Moon Sh, Kim Nh, Lee Hm. Comparison Between Posterolateral Fusion With Pedicle Screw Fixation And Anterior Interbody Fusion With Pedicle Screw Fixation In Adult Spondylolytic Spondylolisthesis. *Yonsei Medical Journal* 2001;42:316-323.
- [104]. Carragee E. Surgical Treatment Of Lumbar Disk Disorders. *Jama: The Journal Of The American Medical Association* 2006;296:2485-2487.
- [105]. Mochida J, Suzuki K, Chiba M. How To Stabilize A Single Level Lesion Of Degenerative Lumbar Spondylolisthesis. *Clinical Orthopaedics And Related Research* 1999:126-134.
- [106]. Wenger M, Sapio N, Markwalder T-M. Long-Term Outcome In 132 Consecutive Patients After Posterior Internal Fixation And Fusion For Grade I And Ii Isthmic Spondylolisthesis. *Journal Of Neurosurgery Spine* 2005;2:289-297.
- [107]. Lisai P, Rinonapoli G, Doria C, Manunta A, Crissantu L, De Santis E. The Surgical Treatment Of Spondylolisthesis With Transpedicular Stabilization: A Review Of 25 Cases. *La Chirurgia Degli Organi Di Movimento* 1998;83:369-374.
- [108]. Kaneda K, Kazama H, Satoh H, Fujiya M. Follow-Up Study Of Medial Facetectomies And Posterolateral Fusion With Instrumentation In Unstable Degenerative Spondylolisthesis. *Clinical Orthopaedics And Related Research* 1986;203:159-167.
- [109]. Schnee Cl, Freese A, Ansell Lv. Outcome Analysis For Adults With Spondylolisthesis Treated With Posterolateral Fusion And Transpedicular Screw Fixation. *Journal Of Neurosurgery* 1997;86:56-63.
- [110]. Thalgot J, Sasso Rc, Cotler Hb, Aebi M, Larocca Sh. Adult Spondylolisthesis Treated With Posterolateral Lumbar Fusion And Pedicular Instrumentation With Ao Dc Plates. *Journal Of Spinal Disorders* 1997;10:204-208.
- [111]. Ani N, Keppler L, Biscup Rs, Steffee Ad. Reduction Of High-Grade Slips (Grades Iii-V) With Vsp Instrumentation. Report Of A Series Of 41 Cases. *Spine* 1991;16:S302-310.
- [112]. Newton Po, Johnston Ce. Analysis And Treatment Of Poor Outcomes Following In Situ Arthrodesis In Adolescent Spondylolisthesis. *Journal Of Pediatric Orthopedics* 1997;17:754-761.
- [113]. Butt Mf, Dhar Sa, Hakeem I, Et Al. In Situ Instrumented Posterolateral Fusion Without Decompression In Symptomatic Low-Grade Isthmic Spondylolisthesis In Adults. *International Orthopaedics* 2008;32:663-669.
- [114]. Chen Jy, Chen Wj, Huang Tj, Shih Ch. Posterior Transpediculate Zielke Instrumentation In Spondylolisthesis. *Orthopaedic Review* 1992;21:75-80.
- [115]. Kho Vk-S, Chen W-C. Posterolateral Fusion Using Laminectomy Bone Chips In The Treatment Of Lumbar Spondylolisthesis. *International Orthopaedics* 2008;32:115-119.
- [116]. Kaneda K, Satoh S, Nohara Y, Oguma T. Distraction Rod Instrumentation With Posterolateral Fusion In Isthmic Spondylolisthesis. 53 Cases Followed For 18-89 Months. *Spine* 1985;10:383-389.
- [117]. Steffee Ad, Sitkowski Dj. Reduction And Stabilization Of Grade Iv Spondylolisthesis. *Clinical Orthopaedics And Related Research* 1988;227:82.
- [118]. Roca J, Ubierna Mt, Cáceres E, Iborra M. One-Stage Decompression And Posterolateral And Interbody Fusion For Severe Spondylolisthesis. An Analysis Of 14 Patients. *Spine* 1999;24:709-714.
- [119]. Pihlajamäki H, Bøostman O, Ruuskanen M, Myllynen P, Kinnunen J, Karaharju E. Posterolateral Lumbosacral Fusion With Transpedicular Fixation: 63 Consecutive Cases Followed For 4 (2-6) Years. *Acta Orthopaedica* 1996;67:63-68.
- [120]. Park Yk, Chung Hs. Instrumented Facet Fusion For The Degenerative Lumbar Disorders. *Acta Neurochirurgica* 1999;141:915-920.
- [121]. Booth Kc, Bridwell Kh, Eisenberg Ba, Baldus Cr, Lenke Lg. Minimum 5- Year Results Of Degenerative Spondylolisthesis Treated With Decompression And Instrumented Posterior Fusion. *Spine* 1999;24:1721-1727.
- [122]. McAfee Pc, Farey Id, Sutterlin Ce, Gurr Kr, Warden Ke, Cunningham Bw. The Effect Of Spinal Implant Rigidity On Vertebral Bone Density. A Canine Model. *Spine* 1991;16:S190-197.

- [123]. Chang P, Seow Kh, Tan Sk. Comparison Of The Results Of Spinal Fusion For Spondylolisthesis In Patients Who Are Instrumented With Patients Who Are Not. Singapore Medical Journal 1993;34:511-514.
- [124]. Kakiuchi M. Repair Of The Defect In Spondylolysis. Durable Fixation With Pedicle Screws And Laminar Hooks*. The Journal Of Bone & Joint Surgery 1997;79:818-825.
- [125]. Nork Se, Hu Ss, Workman Kl, Glazer Pa, Bradford Ds. Patient Outcomes After Decompression And Instrumented Posterior Spinal Fusion For Degenerative Spondylolisthesis. Spine 1999;24:561-569.
- [126]. Garfin Sr. Surgical Indications For Spinal Instrumentation In Degenerative Diseases. Western Journal Of Medicine 1995;163:571.
- [127]. Axelsson P, Johnsson R, Strömqvist B, Arvidsson M, Herrlin K. Posterolateral Lumbar Fusion. Outcome Of 71 Consecutive Operations After 4 (2-7) Years. Acta Orthopaedica Scandinavica 1994;65:309-314.
- [128]. Madan S, Boeree Nr. Outcome Of Posterior Lumbar Interbody Fusion Versus Posterolateral Fusion For Spondylolytic Spondylolisthesis. Spine 2002;27:1536-1542.
- [129]. Ekman P, Möller H, Tullberg T, Neumann P, Hedlund R. Posterior Lumbar Interbody Fusion Versus Posterolateral Fusion In Adult Isthmic Spondylolisthesis. Spine 2007;32:2178-2183.
- [130]. Ogilvie Jw. Complications In Spondylolisthesis Surgery. Spine 2005;30:S97-101.
- [131]. Hacker Rj. Comparison Of Interbody Fusion Approaches For Disabling Low Back Pain. Spine 1997;22:660-665; Discussion 665.
- [132]. Lin Pm. Posterior Lumbar Interbody Fusion Technique: Complications And Pitfalls. Clinical Orthopaedics And Related Research 1985;90-102.
- [133]. Wetzel Ft, Larocca H. The Failed Posterior Lumbar Interbody Fusion. Spine 1991;16:839-845.
- [134]. Dickman Ca, Fessler Rg, Macmillan M, Haid Rw. Transpedicular Screw-Rod Fixation Of The Lumbar Spine: Operative Technique And Outcome In 104 Cases. Journal Of Neurosurgery 1992;77:860-870.
- [135]. Matthiass Hh, Heine J. The Surgical Reduction Of Spondylolisthesis. Clinical Orthopaedics And Related Research 1986:34-44.
- [136]. Naderi S, Manisali M, Acar F, Ozaksoy D, Mertol T, Arda Mn. Factors Affecting Reduction In Low-Grade Lumbosacral Spondylolisthesis. Journal Of Neurosurgery 2003;99:151-156.
- [137]. Poussa M, Schlenzka D, Seitsalo S, Ylikoski M, Hurri H, Osterman K. Surgical Treatment Of Severe Isthmic Spondylolisthesis In Adolescents. Reduction Or Fusion In Situ. Spine 1993;18:894-901.
- [138]. Turner Ja, Ersek M, Herron L, Et Al. Patient Outcomes After Lumbar Spinal Fusions. Jama : The Journal Of The American Medical Association 1992;268:907-911.
- [139]. Cheng L, Nie L, Zhang L. Posterior Lumbar Interbody Fusion Versus Posterolateral Fusion In Spondylolisthesis: A Prospective Controlled Study In The Han Nationality. International Orthopaedics 2009;33:1043-1047.
- [140]. Swan J, Hurwitz E, Malek F, Et Al. Surgical Treatment For Unstable Low-Grade Isthmic Spondylolisthesis In Adults: A Prospective Controlled Study Of Posterior Instrumented Fusion Compared With Combined Anterior-Posterior Fusion. The Spine Journal : Official Journal Of The North American Spine Society 2006;6:606-614.
- [141]. Weatherley Cr, Prickett Cf, O'brien Jp. Discogenic Pain Persisting Despite Solid Posterior Fusion. The Journal Of Bone And Joint Surgery British Volume 1986;68:142-143.
- [142]. Thomsen K, Christensen Fb, Eiskjaer Sp, Hansen Es, Fruensgaard S, Bünger
- [143]. Ce. 1997 Volvo Award Winner In Clinical Studies. The Effect Of Pedicle Screw Instrumentation On Functional Outcome And Fusion Rates In Posterolateral Lumbar Spinal Fusion: A Prospective, Randomized Clinical Study. Spine 1997;22:2813-2822.
- [144]. Chauhan C, Francis Ga, Kemeny Aa. The Avoidance Of Surgery In The Treatment Of Subarachnoid Cutaneous Fistula By The Use Of An Epidural Blood Patch:
- [145]. Technical Case Report. Neurosurgery 1995;36:612-613; Discussion 613.

Dr.Ramesh Benguluri "Surgical Management of Spondylolisthesis by Pedicular Screw Rod System and Postero-Lateral Fusion" IOSR Journal of Dental and Medical Sciences (IOSR-JDMS), vol. 17, no. 4, 2018, pp 61-70.