

Pulse Oximetry Screening to Detect Cyanotic Congenital Heart Disease in Sick Neonates in a Neonatal Intensive Care Unit

Dr. Pramod kumar Raju S., Dr. Partha kumar Chaudari.

(Junior resident dept. Paediatrics RIMS Ranchi.)

(Associate professor dept. paediatrics RIMS Ranchi)

Professor Dr. A K Chaudhary. (Professor and HOD dept. Paediatrics RIMS Ranchi.)

Corresponding author :- Dr. Partha Kumar Chaudari.

Abstract: Objective: To evaluate pulse oximetry for detection of congenital cyanotic heart disease in sick neonates using echocardiography as gold standard.

Methods: Pulse oximetry readings were taken at admission from 500 neonates from right upper limb and either foot with infant breathing room air. Pulse oximetry was considered abnormal if oxygen saturation at room air measured <90% or difference between right hand and foot was more than 3%. Persistent abnormality was considered positive result. Echocardiography was performed on all neonates with positive pulse oximetry (study group) as well as on neonates with negative pulse oximetry (controls).

Results: Pulse oximetry was positive in 24 neonates. It detected 9 out of 10 (90 %) true positives. The sensitivity, specificity, positive predictive value, negative predictive value and odds ratio (95% CI) of pulse oximetry was 90 %, 55.58 %, 5.62 %, 99.47 and 11.3 , respectively.

Conclusion: Pulse oximetry screening is useful in detecting cyanotic heart disease.

Congenital heart diseases (CHDs) account for 6 -10 % of all the infant deaths, and 20 - 40 % of all infant deaths from malformations [1]. About 25% of CHDs are life threatening and manifest before the first routine clinical examination [1,2].

The existing pulse oximetry monitoring protocol to detect critical congenital heart disease, is restricted to neonates in infant nursery [5] . Pulse oximetry as a screening test for congenital cyanotic heart disease has been evaluated among in sick neonates. The present study was designed to evaluate the utility of pulse oximetry screening in detecting congenital cyanotic heart disease among sick neonates in a referral neonatal unit catering to outborn neonates.

Date of Submission: 26-04-2018

Date of acceptance: 15-05-2018

I. Methods

The study was conducted in the Referral Neonatal Unit of a teaching hospital between April 2017 and December 2017. The unit caters exclusively to outborn sick neonates referred from community hospitals of Ranchi and surrounding states, or to those born at home and transported to the hospital directly by the parents. All neonates admitted to the unit during the study period were eligible for inclusion. Neonates in whom stable pulse oximeter signals could not be obtained were excluded. Informed written consent was obtained from the parents of all enrolled subjects.

All neonates at admission were clinically evaluated by a resident doctor for temperature, heart rate, respiratory rate (RR), chest retractions, central cyanosis, femoral pulses, other peripheral pulses, capillary filling time, peripheries (cool or warm) and clubbing. Presence of either tachypnea (RR >60/min), retractions, central cyanosis, poor femoral pulses, precordial pulsations, hepatomegaly or murmur was considered as positive clinical examination suggestive of congenital heart disease [11]. Pulse oximetry readings (Measupro digit pulse oximetry, model no 0*250) were taken at admission from right upper limb and either foot with infant breathing room air. The recordings were noted one minutes after stable signals were obtained. Pulse oximetry was considered abnormal if oxygen saturation at room air or on oxygen therapy measured <90% or there was more than 3% difference between right hand and foot [5]. All neonates with abnormal pulse oximetry were subjected to three observations each, separated by at least 60 minutes. Screen was considered positive only if the abnormality persisted till the last reading. Echocardiography (Philips iE33 xMATRIX echocardiography system) was performed by a pediatric cardiologist on all neonates with a positive pulse oximetry screen (study group) and on one subsequently enrolled neonate with negative screen per neonate with positive screen (controls).

Sensitivity, specificity, positive and negative predictive value, positive likelihood ratio and negative likelihood ratio of pulse oximetry in detecting cyanotic heart disease in sick neonates were calculated.

II. Results

A total of 500 neonates admitted in referral neonatal unit during the study period were screened. Pulse oximetry was positive in 160 neonates, and in ten neonates, stable pulse oximeter signals could not be obtained.

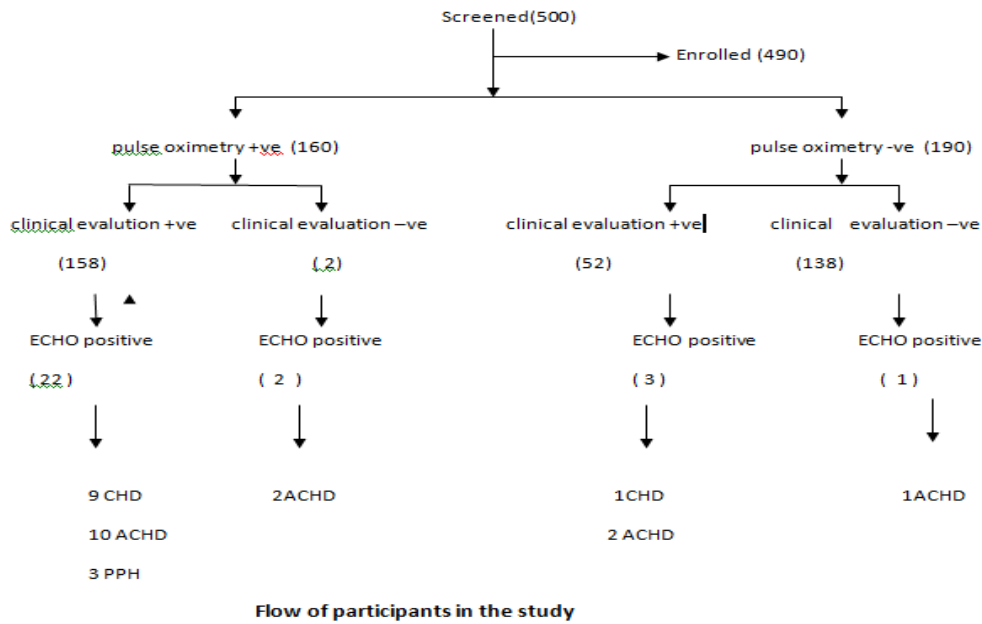


Table I compares the baseline demographic and clinical characteristics of cases and controls. Pulse oximetry was positive in 9 out of 10 (90 %) neonates with echocardiography proven cyanotic heart disease (d-transposition of great arteries, n=2), (tetralogy of Fallot, n=3); (hypoplastic left heart n=1), (tricuspid atresia n=2), (Total anomalous pulmonary venous connection n=2). Pulse oximetry was negative in neonate with tetralogy of Fallot with mild pulmonary stenosis and large left to right shunt.

Table II shows pulse oximetry findings in study population. The pre-post ductal difference was >3%.

	SpO ₂ <90 %	Pre-post ductal difference >3%	SpO ₂ 90-<95%	SpO ₂ ≥95%
Cyanotic heart disease (n=10)	10 (90 %)	2 (20 %)	1 (10 %)	0
Acyanotic heart disease (n=15)	12 (80 %)	2 (13.3 %)	2 (13.3 %)	1 (6.6 %)
Persistent pulmonary hypertension (n=3)	3 (100%)	1 (33.3%)	0	0
Respiratory diseases (n=120)	95 (79.1 %)	0	2 (13.3 %)	10 (8.3 %)
Shock (n=30)	22 (73.3 %)	0	6 (20%)	2 (6.6 %)
Others (n=110)	0	0	66 (60 %)	44 (40 %)

TABLE I Comparison of Characteristics of Cases and Controls

Characteristics	Cases (n=160)	Controls (n=190)
Clinical significance, No. (%)		
Tachycardia > 160 / min	15 (9.3%)	7 (3.68%)
Tachypnea > 60 / min	10 (6.25%)	23 (12.1%)
Chest retractions	10 (6.25%)	58 (30.5%)
Central cyanosis	10 (6.25%)	0
Murmur	10 (6.25%)	8 (4.7%)
Fewer fetal pulses	10 (6.25%)	9 (4.3%)
Hepatic enlargement	10 (6.25%)	12 (6.31%)
Diastolic ejection	10 (6.25%)	0
Cyanotic heart disease	10 (6.25%)	1 (0.52%)
Acyanotic heart disease	10 (6.25%)	1 (1.57%)
Persistent pulmonary hypertension	10 (6.25%)	0
Respiratory distress	10 (6.25%)	7 (3.15%)
Shock	10 (6.25%)	7 (3.68%)
Other	10 (6.25%)	110 (57.8%)

The sensitivity, specificity, positive predictive value, negative predictive value and odds ratio of pulse oximetry to detect cyanotic congenital heart disease was 90%, 55.58% , 5.62% , 99.47% and 11.3 respectively .

III. Discussion

Since publication of several large studies that used pulse oximetry to screen for congenital heart defects in the newborn, pulse oximetry screening has generated considerable interest among patients care providers and parents group.[13,14]. These studies suggested pulse oximetry screening is feasible, cost-effective, and useful in detection of cardiac lesions .

In this study, we found that neonates with CCHD were have been detected clinically within several hours of birth. Total of 500 neonates were screened for study, among them 350 neonates were screened for pulse oximetry screening test , in that 160 neonates were found to be positive and 190 were negative. All 350 neonates were undergone ECHO testing, in that we have seen only 10 neonates were found to have Congenital heart disease, among them 9 CCHD neonates were detected in pulse oximetry positive group, and 1 neonate was detected from pulse oximetry negative group.

In our study, only one case of cyanotic heart disease (teralogy of Fallot) had a saturation persisting between 90% and 95% , because of this reading we have added this neonate under pulse oximetry negative group. The sensitivity and negative predictive values of pulse oximetry screening to detect cyanotic heart disease and critical congenital heart disease were high.

Majority of the studies done in well infant nurseries had used the saturation cut-off of less than 95% for abnormal pulse oximetry [7,9,10]. The working group [5] recommended any saturation below 90% as abnormal for pulse oximetry screening in infant nursery, and recommended three repeated saturations taken 60 minutes, if the saturation is between 90% and 95%. Specificity of pulse oximetry was low because it was also positive in cases of respiratory diseases, acyanotic heart diseases with congestive heart failure, shock and persistent pulmonary hypertension which are common in neonatal intensive care settings.

To conclude, pulse oximetry screening is useful in detecting cyanotic heart diseases in a setting catering to sick out born neonates. Negative predictive value of pulse oximetry is high, making it useful to reliably rule out critical congenital heart disease or PPHN among sick neonates, thus avoiding need for an urgent echocardiography.

What This Study Adds?

- Pulse oximetry screening is useful in detecting cyanotic heart diseases, critical duct-dependent systemic lesions and persistent pulmonary hypertension in sick neonates.

References

- [1]. Wren C, Reinhardt Z, Khwaja K. Twenty year trends in diagnosis of life threatening neonatal cardiovascular malformations. Arch Dis Child Fetal Neonatal Ed. 2008;93:F33-7.
- [2]. Vaidyanathan B, Satish G, Mohannan ST, Sundaram KR, Warriar KKR, Kumar RK. Clinical screening for congenital heart disease at birth: A prospective study in a community hospital in Kerala. Indian Pediatr. 2011;48:25-30.
- [3]. Bakshi KD, Vaidyanathan B, Sundaram KR, Roth SJ, Shivaprakasha K, Rao SG, et al. Determinants of early outcome after neonatal heart surgery in a developing country. J Thoracic Cardio Vascular Surgery. 2007;134:765-71.
- [4]. Brown KL, Ridout DA, Hoskote A, Verhulst L, Ricci M, Bull C. Delayed diagnosis of congenital heart disease worsens preoperative condition and outcome of surgery in neonates. Heart. 2006;92:1298-302.
- [5]. Kemper AR, Mahle WT, Martin GR, Cooley WC, Kumar P, Morrow WR, et al. Strategies for implementing screening for critical congenital heart disease. Pediatrics. 2011;128:e1259-67.
- [6]. Sendelbach DM, Jackson GL, Lai SS, Fixler DE, Stehel EK, Engle WD. Pulse oximetry screening at 4 hours of age to detect critical congenital heart defects. Pediatrics. 2008;122:e815-20.
- [7]. Ewer AK, Middleton LJ, Furnston AT, Bhoyar A, Daniels JP, Thangaratnam S, et al. Pulseox Study Group. Pulse oximetry screening for congenital heart defects in newborn infants (Pulseox): A test accuracy study. Lancet. 2011;378:785-94.
- [8]. Arlettaz R, Bauschatz AS, Monkoff Messers B, Bauersfeld U. The contribution of pulse oximetry for early diagnosis of congenital heart disease in newborns. Eur J Pediatr. 2006;165:94-8.
- [9]. de-Wahl Granelli A, Wennergren M, Sandberg K, Mellander M, Bejlum C, Inganas N, et al. Impact of pulse oximetry screening on the detection of duct dependent congenital heart disease: A Swedish prospective screening study in 39,821 newborns. BMJ. 2009;338: a3037.
- [10]. Meberg A, Andreasson A, Brunvand L, Markestad T, Moster D, Nietsch L, et al. Pulse oximetry screening as a complimentary strategy to detect critical congenital heart defects. Acta Paediatr. 2009;98:682-6.

- [11]. Koppel LR, Druschel CM, Carter T, Goldberg BE, Mehta PN, Talwar R, et al. Effectiveness of pulse oximetry screening for congenital heart disease in asymptomatic newborns. *Pediatrics*. 2003;111:451-5.
- [12]. Thangaratinam S, Brown K, Zamora J, Khan KS, Ewer AK. Pulse oximetry screening for critical congenital heart defects in asymptomatic newborn babies: a systematic review and meta-analysis. *Lancet*. 2012;379:2459-64.
- [13]. Haq FU, Jalil F, Hashmi S, Jumani MI, Imdad A, Jabeen M, et al. Risk factors predisposing to congenital heart defects. *Ann Pediatr Cardiol*. 2011;4:117-21.

Dr. Pramod kumar Raju S "Pulse Oximetry Screening to Detect Cyanotic Congenital Heart Disease in Sick Neonates In A Neonatal Intensive Care Unit "IOSR Journal of Dental and Medical Sciences (IOSR-JDMS), vol. 17, no. 5, 2018, pp 01-04