

Negative Pressure Wound Therapy using locally available resources in managing wounds in orthopaedics: Our experience and Review of literature.

Dr. Thejaswi.S.G*¹, Dr. Ujjawal Pradhan², Dr. Papa Naik. H³, Dr. Jowas Rai⁴

¹Assistant Professor, Department of Orthopaedics, Sikkim Manipal Institute of Medical Sciences, Sikkim.

²Assistant Professor, Department of Orthopaedics, Sikkim Manipal Institute of Medical Sciences, Sikkim.

³Professor Department of Orthopaedics, Sikkim Manipal Institute of Medical Sciences, Sikkim

⁴Senior Resident, Department of Orthopaedics, Sikkim Manipal Institute of Medical Sciences, Sikkim

*corresponding author. Dr. Thejaswi.S.G

Abstract: Negative Pressure Wound Therapy (NPWT) has remained one of the popular methods of managing complex wounds across surgical branches, including orthopaedics. Creating a sub atmospheric pressure on wound bed helps in granulation tissue formation. Many commercial forms of NPWT are being used worldwide. Unfortunately, these commercial devices come with huge monetary burden to patient. In order to make this sub atmospheric therapy available to unaffordable patients many modifications have been made. This present study evaluates the efficacy of NPWT given by using locally available materials at hospital and cost effectiveness of the treatment along with a review of literature.

Methods and materials: The study included 32 wounds in 32 patients who were treated at our institution. After debriding wounds, negative pressure was applied using pre sterilised polyurethane foam, suction catheter, suction apparatus and transparent adhesive sealing material (Tegaderm, Ioban. 3M). Intermittent negative pressure of -50 to -125 mmHg was applied. Dressing was changed every 48hrs.

Results: Average size of wounds at the beginning of NPWT was 102.9 sq.cm and at the end of therapy wound size reduced by ~30% in surface area. An average of 5.2 dressings were required to achieve desired result. Mean duration of NPWT was 12 days. 23 of 32 wounds were covered by split skin graft once healthy granulation bed was prepared, 8 wounds healed by secondary intention. Average cost per dressing was 300 INR. No NPWT associated complications were found. All wounds healed without any wound breakdown.

Conclusion: By using principles of NPWT, effective use of locally available resources can be utilized to provide sub atmospheric pressure to achieve similar results as of commercial NPWT but with significant cost reduction. Further long term controlled studies are needed in this aspect which would help in providing affordable wound management.

Key words: Negative pressure wound therapy, NPWT, indigenous NPWT, suction therapy, orthopaedic wounds.

Date of Submission: 22-06-2018

Date Of Acceptance: 05-07-2018

I. Introduction

Negative pressure wound therapy (NPWT) in its present form was first described by Fleischmann et al¹ in 1993. They used sub atmospheric pressure to treat open fracture wounds and achieved good results. Ever since its introduction, NPWT has remained one of the popular methods of managing complex wounds across surgical branches. NPWT is being used successfully in treatment of wounds such as open abdominal wounds^{2,3,4}, dehisced sternal wounds following cardiac surgery^{5,6} and as a valuable agent in complex non-healing wounds.^{7,8} In orthopaedics it has gained popularity in past 2 decades for management of acute open fractures, pressure sores as well as chronic wounds associated with osteomyelitis⁹.

In 1996, KCI USA introduced and widely popularized Vacuum Assisted Closure device (VAC®)¹⁰. Negative pressure wound therapy was approved by the FDA in 1997. Many other commercial forms of NPWT are being used worldwide. Principle components of these system include filling wound with polyurethane sponge and sealing with adhesive cover, a drainage tube connected to suction device. This creates sub atmospheric pressure on wound bed which helps in granulation tissue formation. Unfortunately, these

commercial devices comes with huge monetary burden to patient. Average estimated cost to patient is around \$7500 for unit and \$75 for each dressing¹¹. In order to make this sub atmospheric therapy available to unaffordable patients many modifications have been done in past which are collectively called as “homemade NPWT”.

In a similar attempt, we at our institution provided NPWT using locally available materials to manage orthopaedic wounds. This present study evaluates the efficacy of NPWT given by using locally available materials like sponge, sterile adhesive coverage(Tegaderm,Ioban), suction tubes and suction apparatus at hospital and cost effectiveness of the treatment.

Objectives:

To assess the effectiveness of indigenously made NPWT in terms of number of dressings needed and final procedure to close the wound. Secondary objective was to assess the cost effectiveness of such a therapy in a set up where commercial VAC was not feasible.

II. Methods and materials:

The study included 32 wounds in 32 patients who were treated at our institution between January 2016 to January 2018. All wounds were primarily debrided and then NPWT was applied. At each dressing change wounds were examined for size of wound, granulation tissue formation, infection, amount of drainage. At the beginning of study wound size after debridement were measured and at the end of study number of dressings needed to achieve desired end point, number of days of admission and treatment cost were analysed.

Method of applying NPWT:

Under suitable anaesthesia, wounds were debrided. After excising dead and necrotic tissues, wounds were measured. Pre-sterilized polyurethane foam was trimmed according to shape of the wound. First layer of foam was placed on the wound bed. To ensure effective distribution of suction effect, multiple holes were made in a suction catheter to suit the length of the wound. A second layer of foam was placed over the first layer after keeping the suction catheter sandwiched between sponge layers. A transparent semipermeable drape(Tegaderm for small wounds,Ioban,3M for larger wounds) was placed over the foam coverage creating a sealed sterile environment. Suction tube was then connected to suction apparatus[figure 1]. Sealing was checked for any leakage. Suction was kept on for 1 hour at -50 to -125mmHg (as tolerated by patient)and off for 15min. This cycle was repeated throughout the day for 2 days. Dressing was changed every 48hours, under aseptic conditions. NPWT was continued till healthy granulation bed was created. Care was taken not to apply negative pressure over blood vessels, nerves or directly over tendons. The apparatus was checked frequently by attending nursing staff for any leakage.

III. Results:

32 patients were included in the study which included 28 male and 4 female patients.Wounds that received NPWT consisted of one case each of chronic osteomyelitis,post traumatic raw area (PTRA) over shoulder and one pressure sore over sacrum. 2 cases of Morel-Lavallée lesionover upper thigh and buttocks. 1 caseeach of open Lisfranc’s fracture dislocation,degloving injury over foot and open calcaneal fracture. Remaining 24 cases were of Grade 2 and grade 3 open fracture of tibia[Table 1][figure 2,3]. In one case(case10) NPWT was applied after failureof reverse sural flap and the wound healed satisfactorily with NPWT.Average size of wounds at the beginning of NPWT was9.8cm x 10.4cm(102.9 sq.cm) and at the end of therapy was 7.8cm x 9.6cm(75.2sq.cm) thus reducing the wound size by~ 30% in surface area. An average of 5.2 dressings were required to achieve desired result. Mean duration of NPWT was 12 days. All wounds showed initial response of granulation tissue except pressure sore over sacrum. However, pressure sore improved on subsequent dressings. 23 of 32 wounds were covered by split skin graft once healthy granulation bed was prepared, 8 wounds healed by secondary intension, one patient (case no20) expired during treatment due to associated co-morbidities unrelated to suction therapy. Average cost per dressing was and average cost per patient was 300INR. There were no clinical signs of infection in any of the wounds at the time of definitive closure. No NPWT associated complications were found. At the end of 6 months follow up no disfiguring deformities were seen and all wounds had healed without any wound breakdown [Table 2].

Case	Diagnosis	Wound size in cm. (in sq.cm)	No.Dressing changes	Final outcome
1.	Type 3b open proximal tibia fracture	15cm x 12cm (180)	8	SSG
2.	Chronic osteomyelitis of tibia	4cm x 6cm (24)	5	Healing by SI
3.	Type 2 open fracture of tibia	8cm x 6cm (42)	3	SSG
4.	Type 3b open fracture distal tibia	10cm x 12cm (120)	10	SSG
5.	Type 2 open fracture tibia	8cm x 5cm (40)	5	SSG
6.	Type 2 open fracture tibia	6cm x 4cm (24)	3	SSG
7.	Raw area after debridement of Morel-Lavallée	18cm x 20cm (360)	10	SSG

	lesion over buttocks			
8.	Type 3b open fracture tibia	11cm x 7cm (77)	6	SSG
9.	Type 3b open fracture tibia	10cm x 12cm (120)	4	SSG
10.	Open calcaneal fracture (failed reverse flap surgery)	10cm x 12cm (120)	8	Healing by SI
11.	Type 3b open fracture tibia	13cm x 12cm (156)	7	SSG
12.	Type 3b open fracture tibia	15cm x 18cm (270)	8	SSG
13.	Type 2 open fracture tibia	8cm x 3cm (24)	3	SSG
14.	Type 2 open fracture tibia	6cm x 5cm (30)	3	SSG
15.	Type 2 open fracture tibia	5cm x 4cm (20)	3	Healing by SI
16.	Open fracture dislocation of Lisfranc's joint	18cm x 12cm (216)	8	SSG
17.	Type 2 open fracture tibia	4cm x 6cm (24)	2	Healing by SI
18.	post traumatic raw area over shoulder	8cm x 6cm (42)	3	SSG
19.	Type 3b open fracture tibia	8cm x 4cm (32)	3	SSG
20.	Grade 4 pressure sore over sacrum	6cm x 6cm (36)	3	Patient expired
21.	Type 3b open fracture tibia	10cm x 11cm (110)	5	SSG
22.	Degloving injury of foot	15cm x 18cm (270)	8	SSG
23.	Type 3b open fracture tibia	12cm x 8cm (86)	7	SSG
24.	Type 2 open fracture tibia	6cm x 8cm (42)	4	SSG
25.	Raw area after debridement of Morel-Lavallée lesion over thigh	10cm x 12cm (120)	3	SSG
26.	Type 3b open fracture tibia	13cm x 8cm (104)	6	SSG
27.	Type 3b open fracture tibia	8cm x 8cm (64)	4	SSG
28.	Type 3b open fracture tibia	12cm x 11cm (132)	6	SSG
29.	Type 2 open fracture tibia	8cm x 6cm (42)	4	SSG
30.	Type 3b open fracture tibia	10cm x 12cm (120)	5	SSG
31.	Type 3b open fracture tibia	15cm x 12cm (180)	7	SSG
32.	Type 3b open fracture tibia	6cm x 11cm (66)	5	SSG

Table 1: Details of cases

Indications	No.cases
Open tibia fracture	24
Foot and ankle injury	3
Post traumatic raw area	2
Morel-Lavallée lesions	1
Osteomyelitis	1
Pressure sore	1
Average size	102.9 Sq.cm
Mean No. dressing	5.2
Mean duration of NPWT	12 days
Final wound closure	
Split Skin Graft	23
Healing by secondary intention	8
Mean cost per dressing	300INR
Complications	Nil

Table 2: Summary

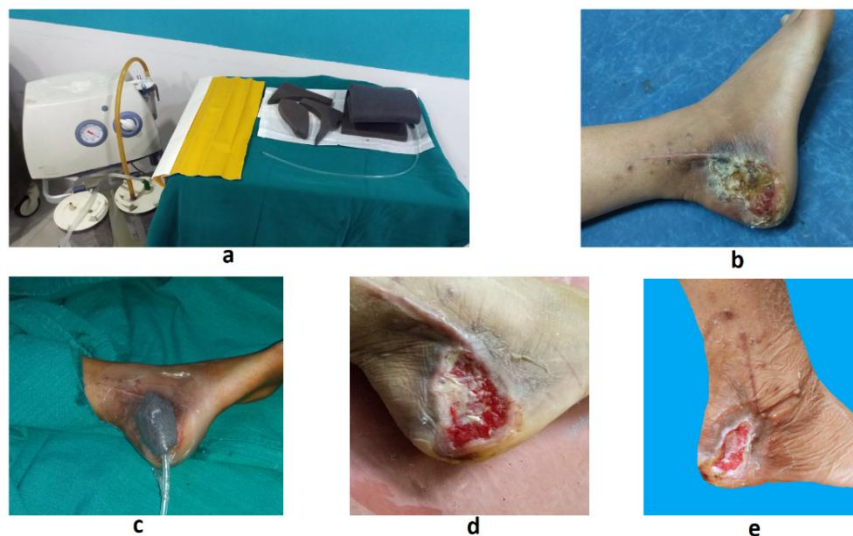


Figure 1: a. materials used. b- wound before application. c- NPWT applied. d&e- progressive granulation tissue and shrinkage of wound.

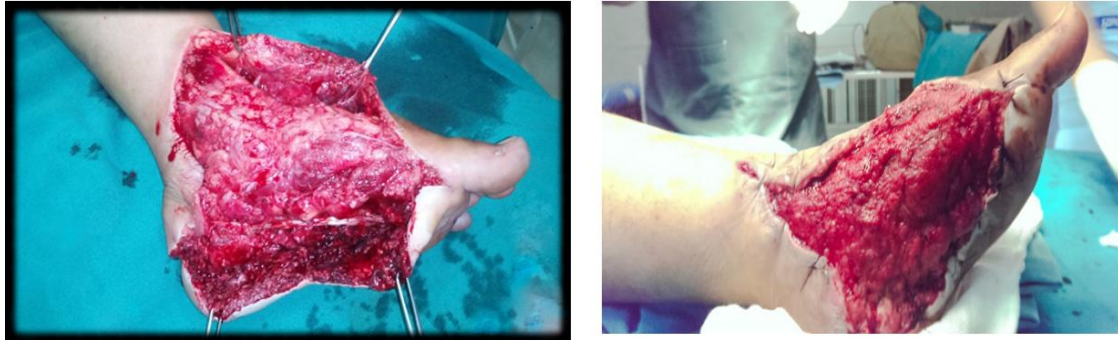

Figure 2: (A) degloving injury over foot after debridement. (B) granulation tissue coverage after NPWT.

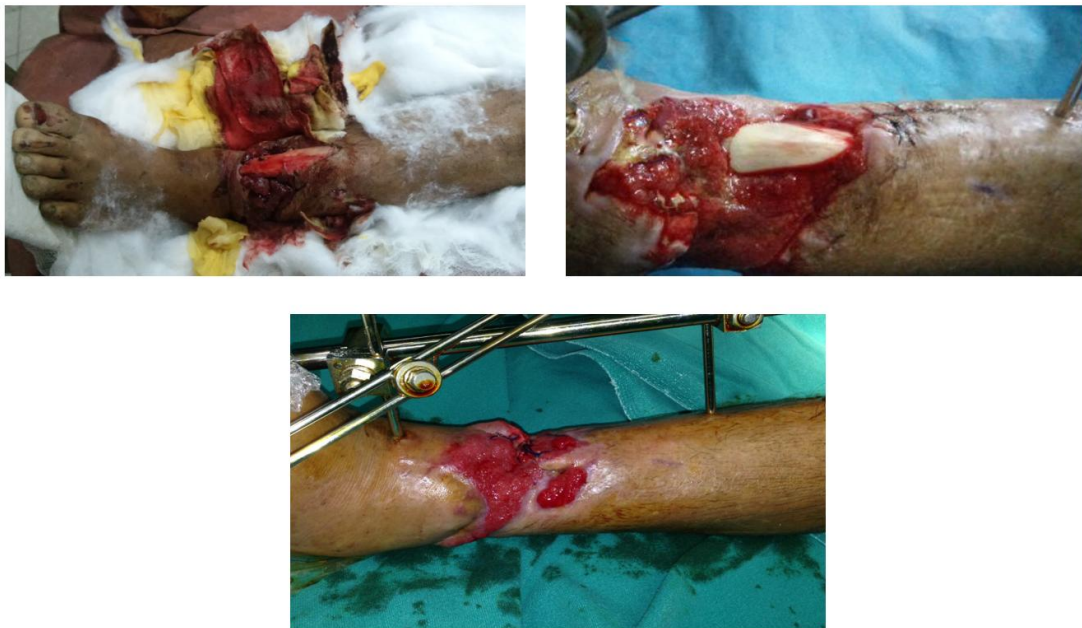

Figure 3: (A) type 3b open fracture tibia. (B) progressive granulation tissue coverage with NPWT, (C) complete granulation tissue coverage with shrinkage of wound.

IV. Review of literature and discussion:

In our literature review we searched articles to answers for the following questions.

- 1) What are the recommended indications for NPWT?
- 2) What should be the optimum pressure to get desired effect?
- 3) What mode is preferred- continuous or intermittent?
- 4) How long NPWT can be administered?
- 5) How frequently dressings have to be changed?
- 6) Cost effectiveness and final outcome of commercial vs indigenous NPWT.

a. Background:

Literature is not clear in crediting specific author in describing development of first NPWT. However, one of the first published data on NPWT were given by Miller M in 1979¹² and Chraker et al. in 1989¹³. Chraker et al, in their study described a nascent suction drainage system for the management of incisional and cutaneous fistulae. In 1993, Fleischmann et al^{14,15}, described a more familiar version of NPWT using a polyurethane sponge. Argenta and Morykwas^{16,17}, in their studies reported the positive effect of the negative pressure on blood flow in the wound and in the adjacent tissue (via Doppler evaluation), on the rate of granulation tissue formation and on the reduction of bacterial load.

Based on these positive findings KCI, USA, introduced V.A.C.® Therapy which is one of the most commonly used commercial NPWT. According to KCI since the introduction of V.A.C.® Therapy, V.A.C.® Therapy remains the most published of all commercial systems¹⁸. Since then commercial availability of NPWT has grown and at present more than a dozen systems are available for clinical use. However, when it comes developing countries and to treating poor patients these systems have limited applications owing to their unavailability in non-metro cities and to unaffordability. This has led to many modifications and have been

variedly called as “home-made NPWT”, “poor man’s VAC”^{11,19}. In 2011, Nauman Ahmad Gill et al, described one such modification where they used open cell sponge, adhesive covering and suction apparatus to provide NPWT¹¹. Mody et al, described one such modification where they used a bellow pump to provide hand-generated negative pressure therapy²⁰. In their study, Saraiya and Shah used continuous negative pressure using simple wound suction drain and available medical supplies in treating patients with diabetic foot²¹.

Similarly we in our study used in hospital available materials to provide NPWT in managing various orthopaedic wounds.

b. Effect of NPWT:

When negative pressure is applied to a wound following clinically significant benefits can be seen²². [figure 4]

- Reduction of the wound area (wound retraction)
- Stimulation of granulation tissue formation
- Removal of small tissue debris by suction
- Reduction of interstitial oedema with consecutive improvement of microcirculation, stimulation of blood flow and oxygenation.

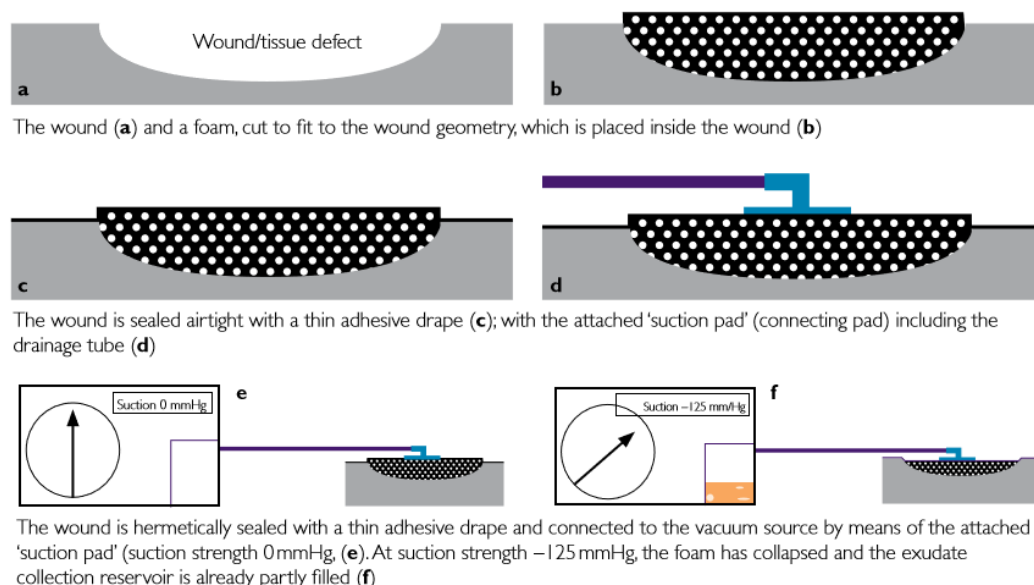


Figure 4: Diagrammatic representation of principle of NPWT*. (reproduced with permission)²².

*This figure was originally published by Apelqvist, J., Willy, C., Fagerdahl, A.M. et al. in the publication “Negative Pressure Wound Therapy – overview, challenges and perspectives” in *J Wound Care* 2017; 26: 3, Suppl 3, S1–S113.

c. Indications:

Although one of the first available literature which gave us the present day NPWT was on open fractures¹, NPWT has been used widely across surgical fields in managing variety of wounds.

In orthopaedics it finds its place in settings of acute trauma specially in cases of open fracture management to prepare wound bed either for flap coverage or for skin coverage. Apart from fractures it is indicated in compartment syndrome after dermatofasciotomy, Morel-Lavallée lesion, incision wound coverage after replacement surgeries, stab injuries, combatrelated extremity injuries and wounds with soft tissue defects which need step wise coverage. NPWT has been used effectively to cover soft tissue defects over tendons and bone as an alternative to flap coverage^{23,24}. NPWT has also shown to be useful in treating chronic osteomyelitis wounds, pressure sore. Owing to our better understanding of NPWT and sufficient encouraging results, the concept of open fracture management has changed from ‘Fix and Flap’ to ‘Fix and NPWT and Flap’.²⁵ [figure 5].

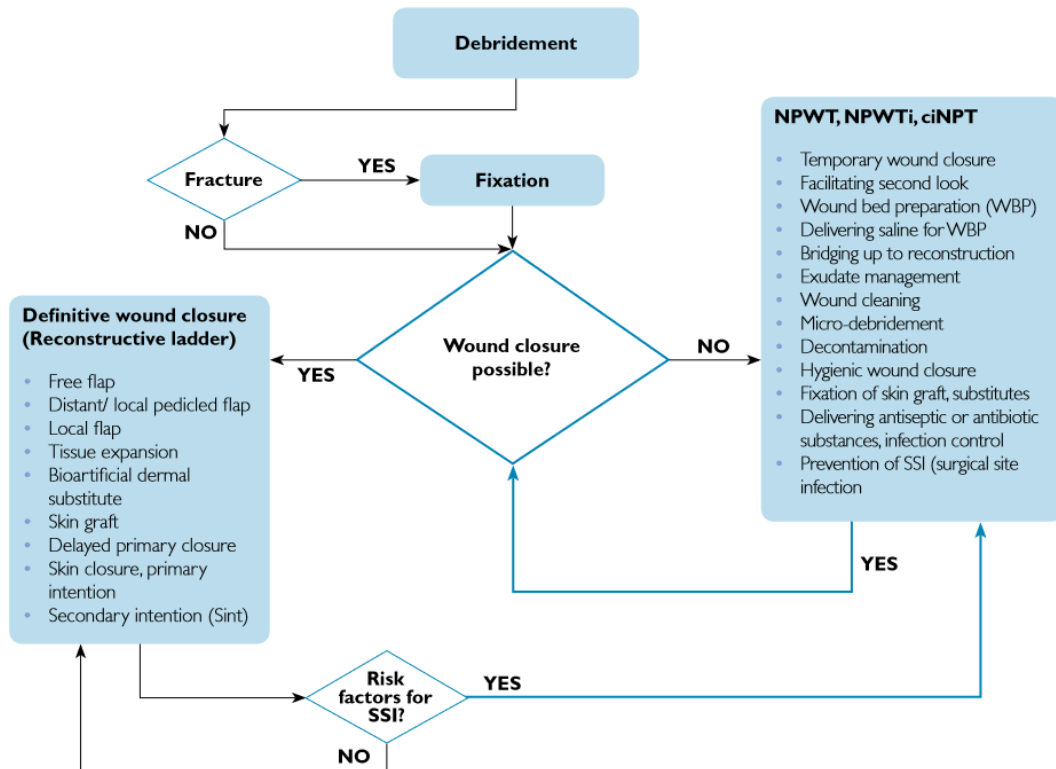


Figure 5: Algorithm for management of open fracture. From 'Fix and Flap' to 'Fix - NPWT-Flap'.
^[22][reproduced with permission] * NPWTi- Negative pressure wound therapy with instillation ,ciNPT-Closed incision Negative pressure therapy.
 *This figure was originally published by Apelqvist, J., Willy, C., Fagerdahl, A.M. et al. in the publication “Negative Pressure Wound Therapy – overview, challenges and perspectives” in J Wound Care 2017; 26: 3, Suppl 3, S1–S113.

Literature support use of NPWT in all the above indications except for pressure sores. Dumville et al., in their study on treating pressure ulcers using negative pressure that ‘This comprehensive review of current randomised controlled trial evidence has highlighted the current uncertainty regarding the effectiveness of negative pressure wound therapy (NPWT) as a treatment for pressure ulcers’²⁶.

Similar to previous studies in our study most common indication was open tibial fractures (24 out of 32) other indications included osteomyelitis, Morel-Lavallée lesion, degloving injuries, PTRAs, pressure sore. In accordance with previous studies, we also noted that granulation tissue formation was delayed and required prolonged negative pressure therapy in case of pressure sore.

d. Optimum Pressure for NPWT:

Morykwas et al. in their animal study suggested a suction level of -125 mmHg as the optimal suction strength for new tissue formation and wound cleansing. Isagoet al and Morykwas et al, in two separate studies studied the effects of different suction strengths on wound healing^{27,28}. Morykwas et al, investigated wound healing and new granulation tissue formation at -25, -125 and -500 mmHg¹⁶ and Isagoet al²⁷, investigated same at -25, -50, -75 and -150 mmHg. These two studies concluded that a suction of around -25 mmHg is less effective than a suction of -125 mmHg. No significant difference in the wound area was found between the suction strengths of -50, -75 and -125 mmHg. Unfortunately, none of the research groups analysed the suction range of -50 to -200 mmHg, which is normally used (commercially available vacuum sources)²². Pressures as low as -40 mmHg may be used for the treatment of sensitive, poorly perfused tissue and levels of negative pressure higher than -80 mmHg are seldom necessary²⁹. Experimental studies in pigs have shown that the maximal biological effects on the wound edges in terms of wound contraction, regional blood flow and the formation of granulation tissue are obtained at -80 mmHg^{29,30}.

Among home-made NPWT, Gill et al used negative pressure of -125mmHg and reported a marked reduction in wound edema and granulation tissue formation by 2 days of therapy. Mody et al were able to get negative pressure of -75mmHg using bellow pump²⁰. In our present study we used negative pressure of -50 to -125mmHg. Unlike other studies that were discussed earlier our pressure determinant were amount of drainage

as well as patient tolerability as higher pressures were associated with pain. Even when the pressure was not fixed at one value we could achieve almost 15% wound size reduction and early granulation tissue generation.

e. Mode of pressure: Continuous mode(CM) or Intermittent mode(IM)?

Morykwas et al., showed that new granulation tissue formation is significantly greater in intermittent suction mode than in continuous suction mode¹⁶. Studies have shown that NPWT applied with intermittent mode produces a mechanical stimulation of the wound bed³¹ and a greater circulatory stimuli³², oxygenation and angiogenesis, and presumably a lower risk of occurrence of ischaemic damage. However, in clinical practice, the continuous mode is still the most widely used NPWT option. This is against the background of the literature supporting wound healing using the intermittent mode in comparison with the continuous mode. Thus, there is a disparity between science (valid reasons to use the IM) and the current practice (almost no use of IM)³³.

When using indigenous therapy, it is difficult to provide or control standardised continuous pressure. Based on the available data which favours intermittent pressure and for technical difficulties studies we used intermittent negative pressure which was given in cycles of one hour on and 15 min off. This was similar to what was used by Gill et al in their study¹¹. Other indigenous NPWT have used continuous negative pressure using closed suction tube system.

However, there are no proper randomised control studies available to compare the difference between continuous mode and intermittent mode in home-made NPWT system.

f. Frequency of dressing changes:

There are no evidence-based time intervals specifying when NPWT should be changed after initial placement. However, manufacturer's instructions of commercial NPWT specify 48–72 hours between dressing changes²². Almost all of studies available follow these guidelines barring few. Same principles have been used in applying indigenous NPWT in studies. Milind and Satish³⁴ in their study changed dressing every other day and Raghupathy et al³⁵ in their study changed dressing 2 or 3 times a week depending on the filling material used. However, Gill et al. in one of the earliest study of 'home-made' NPWT changed dressings every 4 days. They recommend this interval to facilitate dressing changes to be done in sterile OT environment¹¹. In our study we changed dressings every 48 hrs to prevent ingrowth of granulation tissue into foam which makes dressing changes painful for the patient. We observed that when pore size of foam was more dressing changes could be delayed upto 72 hrs and was less painful.

All the above studies, including our present study have shown similar results irrespective of different frequency of dressing changes. But it is difficult form a protocol on frequency of dressing as no significant evidence based studies are available on effect of frequency of dressing on end results of NPWT. Hence it is safe to conclude that dressing changes should be tailored according to patient and wound morphology.

g. Total duration

End point of NPWT can either be wound bed is prepared for cases either skin grafting or flap coverage or enough reduction in wound size to facilitate secondary closure or healing by secondary intention. Hou, et al. suggested that prolonged periods of NPWT usage, >7 days, should be avoided to reduce infection and amputation risks³⁶. But according to available data there is no controversy to follow with NPWT for 10–14 days²² Under ideal conditions (especially in the absence of infection), well perfused wounds will respond quickly (i.e within one week) with evidence of granulation tissue formation³⁷. Daniel in his review found on comparing 10 studies on NPWT that total time for use of negative pressure wound therapy ranged from 7 to 53 days across all 10 studies³⁸.

In one of the earliest papers on NPWT Fleischmann and his colleagues used vacuum therapy in the treatment of the 313 patients with infected wounds for an average duration of 16.7 days with an average of 3.1 dressing changes¹⁵.

While using 'home-made' NPWT in their study by Gill, et al. total number of treatment days from the first NPWT dressing application to the time the wounds were ready for coverage ranged from 9 to 26 days (average 13 days) and it was 12 to 14 days in a similar study by Milind R^{11,34}.

We found that an average of 12 days of indigenous NPWT was required in our study to achieve end results, which is similar to above mentioned studies. It is seen from data available that there is not much of difference in total duration of commercial NPWT and indigenous NPWT to achieve desired end result.

h. Outcome and cost effectiveness:

Efficacy of NPWT in treating traumatic wounds has been well established. Most of the studies using commercial NPWT have claimed good results in the form of achieving healthy granulation tissue for skin or flap coverage, in reducing size of wound, reducing infection rate or in controlling infection in cases of infected wound. Similar to these commercial NPWT studies on indigenous NPWT have also achieved same expected results but at a much less economic burden to patients.

European Wound Management and Association(EWMA) in their review and recommendation article on NPWT note that there are no national system in place, leaving it up to regional or hospital budgets to allow for the reimbursement in most of countries. Also, while the device might not be reimbursed, the treatment might be reimbursed as a dressing change. EWMA also states that non-commercial NPWT-systems prove to be cost-effective compared with commercial ones²².

The scenario is same in India, where VAC and other commercially available NPWT is not covered under insurance or re-imburement while dressing changes are covered. Thus making commercially available NPWT almost unaffordable to majority of patients. By using indigenous NPWT, Gill, et al. reported average expenditure of \$7 USD to \$12USD and Milind R showed cost per dressing could be as low as Rs 400(\$8USD).

Similarly in our study 27 of 32 wounds were covered by split skin grafting after good wound preparation by NPWT. Wound size reduced by 15% at a rate of 3% surface area reduction per dressing. Average cost incurred per dressing was around 300INR(approx. \$5 USD) which is considerably lower than average cost in commercial NWPT(22.000INR or 440USD). None of the patients required flap coverage or complex surgeries. No NPWT related complications were noted.

V. Conclusion:

NPWT is a valuable tool in managing complex wounds in orthopaedics. By using principles of NPWT, effective use of locally available resources can be utilized to provide sub atmospheric pressure to achieve similar results as of commercial NPWT but with significant cost reduction. Further long term controlled studies are needed in this aspect which would help in providing affordable wound management.

References:

- [1]. Fleischmann W, Strecker W, Bombelli M, Kinzl L., Vacuum sealing as treatment of soft tissue damage in open fractures. *Der Unfallchirurg* 1993; 96(9): 488-92
- [2]. Acosta, S., Bjarnason, T., Petersson, U. et al. Multicentre prospective study of fascial closure rate after open abdomen with vacuum and mesh-mediated fascial traction. *Br J Surg* 2011; 98: 5, 735–743.
- [3]. Kaplan, M. Negative pressure wound therapy in the management of abdominal compartment syndrome. *Ostomy Wound Manage* 2005; 51: 2A Suppl, 29S–35S.
- [4]. Swan, M., Banwell, P. Topical negative pressure. *Advanced management of the open abdomen*. Oxford Wound Healing Society. 2003.
- [5]. Fuchs, U., Zittermann, A., Stuetgen, B. et al. Clinical outcome of patients with deep sternal wound infection managed by vacuum-assisted closure compared to conventional therapy with open packing: a retrospective analysis. *Ann Thorac Surg* 2005; 79: 2, 526–531.
- [6]. Fleck, T., Gustafsson, R., Harding, K. et al. The management of deep sternal wound infections using vacuum assisted closure? (V.A.C.®) therapy. *Int Wound J* 2006; 3: 4, 273–280.
- [7]. Armstrong, D.G., Lavery, L.A., Diabetic Foot Study Consortium. Negative pressure wound therapy after partial diabetic foot amputation: a multicentre, randomised controlled trial. *Lancet* 2005; 366: 9498, 1704–1710.
- [8]. Blume, P.A., Walters, J., Payne, W. et al. Comparison of negative pressure wound therapy using vacuum-assisted closure with advanced moist wound therapy in the treatment of diabetic foot ulcers: a multicenter randomized controlled trial. *Diabetes Care* 2008; 31:4, 631–636.
- [9]. Zhonghua Wai Ke Za Zhi et al, Treatment of acute and chronic osteomyelitis with negative pressure wound therapy. 2008 Jun 1; 46(11):806-8)
- [10]. KCI Connect newsletter, Published by KCI Medical India Pvt. Ltd. www.kci-medical.in
- [11]. Nauman Ahmad Gill, Abdul Hameed, Yawar Sajjad, Zeeshan Ahmad, Mohammad Ali Rafique Mirza: “Homemade” Negative Pressure Wound Therapy: Treatment of Complex Wounds Under Challenging Conditions. *WOUNDS* 2011; 23(4):84–92
- [12]. Miller M. The Kremlin papers. *Technology Wound Journal*. 2008; 1:22–24
- [13]. Chariker ME, Jeter KF, Tintle TE, Bottsford JE. Effective management of incisional and cutaneous fistulae with closed suction wound drainage. *Contemp Surg* 1989; 34: 59-63
- [14]. Fleischmann W, Lang E, Kinzl L. Vacuum assisted wound closure after dermatofasciotomy of the lower extremity. *Unfallchirurg* 1996; 99(4):283-7. 3.
- [15]. Fleischmann W, Lang E, Russ M. Treatment of infection by vacuum sealing. *Unfallchirurg* 1997; 100(4):301-4.
- [16]. Morykwas, M.J., Argenta, L.C., Shelton-Brown, E.I., McGuirt, W. Vacuum-assisted closure: a new method for wound control and treatment: animal studies and basic foundation. *Ann Plast Surg* 1997; 38: 6, 553–562
- [17]. Argenta, L.C., Morykwas, M.J. Vacuum-assisted closure: a new method for wound control and treatment: clinical experience. *Ann Plast Surg* 1997; 38: 6, 563–577
- [18]. A comprehensive guide to the V.A.C.® Negative Pressure Wound Therapy System from KCI. KCI product bench study data, November 2013.
- [19]. M Singh, R Singh, S Singh, V Pandey, D Singh. Vacuum assisted Closure in wound management – Poor man’s VAC®. *The Internet Journal of Plastic Surgery*. 2008 Volume 6 Number 1.
- [20]. Mody GN, Zurovcik DR, Joharifard S, Kansayisa G, Uwimana G, Baganizi E, Ntakiyiruta G, Mugenzi D, Riviello R. Biomechanical and safety testing of a simplified negative pressure wound therapy device. *Plast Reconstr Surg* 2015 Apr; 135(4):1140-1146
- [21]. Saraiya HA, Shah MN. Use of indigenously made negative pressure wound therapy system for patients with diabetic foot. *Adv Skin Wound Care* 2013 Feb; 26(2):74-77
- [22]. Apelqvist, J., Willy, C., Fagerdahl, A.M. et al. Negative Pressure Wound Therapy – overview, challenges and perspectives. *J Wound Care* 2017; 26: 3, Suppl 3, S1–S113.
- [23]. Steiert, A.E., Gohritz, A., Schreiber, T.C. et al. Delayed flap coverage of open extremity fractures after previous vacuum-assisted closure (VAC®) therapy – worse or worth? *J Plast Reconstr Aesthet Surg* 2009; 62: 5, 675–683.

- [24]. Vaseanon, T., Somsuk, W. Negative pressure wound therapy for traumatic foot and ankle wound: two case reports and review of the literature. *J Med Assoc Thai* 2015; 98: 1, 111–116.
- [25]. Mehta, S., Williams, W. Fix and flap: the radical orthopaedic and plastic treatment of severe open fractures of the tibia. *J Bone Joint Surg Br* 2001; 83: 5, 773–774.
- [26]. Dumville, J.C., Webster, J., Evans, D., Land, L. Negative pressure wound therapy for treating pressure ulcers. *Cochrane Database Syst Rev* 2015; 5: 5, CD011334.
- [27]. Isago, T., Nozaki, M., Kikuchi, Y. et al. Effects of different negative pressures on reduction of wounds in negative pressure dressings. *J Dermatol* 2003; 30: 8, 596–601.
- [28]. Morykwas, M.J., Faler, B.J., Pearce, D.J., Argenta, L.C. Effects of varying levels of subatmospheric pressure on the rate of granulation tissue formation in experimental wounds in swine. *Ann Plast Surg* 2001; 47: 5, 547–551.
- [29]. Borgquist, O., Ingemansson, R., Malmjö, M. Wound edge microvascular blood flow during negative-pressure wound therapy: examining the effects of pressures from –10 to –175 mmHg. *Plast Reconstr Surg* 2010; 125: 2, 502–509.
- [30]. Borgquist, O., Gustafson, L., Ingemansson, R., Malmjö, M. Tissue ingrowth into foam but not into gauze during negative pressure wound therapy. *Wounds* 2009; 21: 11, 302–309.
- [31]. Malmjö, M., Ingemansson, R..Variable, intermittent and continuous negative pressure wound therapy using foam or gauze: the biological effects on the wound bed including, blood flow, micro and macro deformation, granulation tissue quantity, wound bed character. *Symposium on Advanced Wound Care and the Wound Healing Society Meeting; 2010 17-20 April; Orlando, Florida.*
- [32]. Borgquist, O., Ingemansson, R., Malmjö, M. The effect of intermittent and variable negative pressure wound therapy on wound edge microvascular blood flow. *Ostomy Wound Manage* 2010; 56: 3, 60–67.
- [33]. Ahearn, C. Intermittent NPWT and lower negative pressures exploring the disparity between science and current practice: a review. *Ostomy Wound Manage* 2009; 55: 6, 22–28.
- [34]. Milind Ruke, Satish Puranik; Indigenous Negative Pressure Wound Therapy for poor patients in India-an observational case series. *The Journal of Diabetic Foot Complications*, 2013; Volume 5, Issue 3, No. 3, Pages - 73 – 77]
- [35]. Raghupathy, Sabrena, Vaithiswaran A, et al. A prospective randomized trial of vacuum-assisted closure versus standard therapy of chronic non-healing wounds. *J. Evolution Med. Dent. Sci.* 2016;5(49):3162-3167, DOI: 10.14260/jemds/2016/733
- [36]. Hou, Z., Irgit, K., Strohecker, K.A. et al. Delayed flap reconstruction with vacuum-assisted closure management of the open IIIB tibial fracture. *J Trauma* 2011; 71: 6, 1705–1708
- [37]. World Union of Wound Healing Societies (WUWHS). Principles of best practice: Vacuum assisted closure: recommendations for use. A consensus document. London: MEP Ltd, 2008.
- [38]. Daniel R. Schlatterer; Negative Pressure Wound Therapy in Grade IIIB Tibial Fractures: Fewer Infections and Fewer Flap Procedures?. *Clin Orthop Relat Res* (2015) 473:1802–1811.

Dr. Thejaswi.S.G "Negative Pressure Wound Therapy using locally available resources in managing wounds in orthopaedics: Our experience and Review of literature.. "IOSR Journal of Dental and Medical Sciences (IOSR-JDMS), vol. 17, no. 7, 2018, pp 54-62.