

Study of Electrocardiographic Changes in Patients of Diabetic Nephropathy of Type 2 Diabetes Mellitus with Background Hypertension

Dr. Ravish Kumar Sinha, Dr. Manjulata* and Dr. Sandeep Kumar*

Department of Physiology, Rajendra institute of Medical Sciences (RIMS), Ranchi, India

Corresponding Author: Dr. Manjulata

Abstract: Type 2 Diabetes patients with Diabetic nephropathy and background hypertension have excessive cardiovascular mortality. It is thus important to know the electrocardiographic changes occurring in patients of Diabetic nephropathy especially in Type 2 Diabetes mellitus and with background hypertension whose prevalence is increasing in Indian population and also worldwide. The objective of this study was to find out the prevalence of cardiovascular ailments in Type 2 Diabetic patients with nephropathy and background hypertension and to help clinicians with screening, diagnosis and timely decision making and also in future and ongoing research. The study was conducted over 100 patients with Diabetic nephropathy of Type 2 Diabetes with background hypertension attending the outpatient and inpatient services of RIMS, Ranchi, India. The study was approved by the ethical committee of the institute. The study showed that 74% of the patients had ECG changes while 26% had normal ECG tracings. Thus, cardiovascular assessment is must in Type 2 Diabetes mellitus patients with nephropathy and background hypertension.

Keywords –Electrocardiography , Diabetic nephropathy , Type 2 Diabetes mellitus , Background hypertension

Date of Submission: 23-07-2018

Date Of Acceptance: 06-08-2018

I. Introduction

Diabetes mellitus is a clinical syndrome characterized by hyperglycemia due to absolute or relative insulin deficiency. Hyperglycemia represents an independent risk factor for development of microvascular and macrovascular diseases. If untreated, hyperglycemia is associated with significant risk of microvascular diseases like diabetic nephropathy , retinopathy , neuropathy and to some extent dermatopathy. The prevalence of both types of diabetes varies considerably around the world. Type 2 diabetes is a major burden in health care facilities in all countries. Type 2 diabetes is now being observed in children and adolescents. Diabetic nephropathy is a complication of diabetes and is associated with increased cardiovascular mortality and decrease in quality of life. It is a major factor in development of chronic kidney disease and is the leading cause of End Stage Renal Disease. It is associated with development of other diabetes related complications. Type 2 Diabetes contributes about 99% of Diabetes in Indian population and only about 1% are Type 1. With increase of diabetic population in India and worldwide, it is obvious that incidence of diabetes related complications like nephropathy is going to be a formidable challenge to the medical fraternity. Cardiovascular causes is a major cause of mortality in Diabetic nephropathy. Study of prevalence of various cardiovascular ailments in Diabetic nephropathy patients would help in proper and timely intervention and reducing the mortality in Diabetic nephropathy patients.

II. Materials And Method

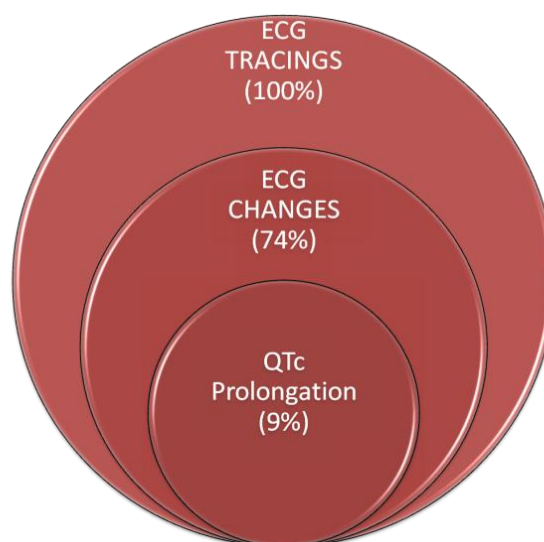
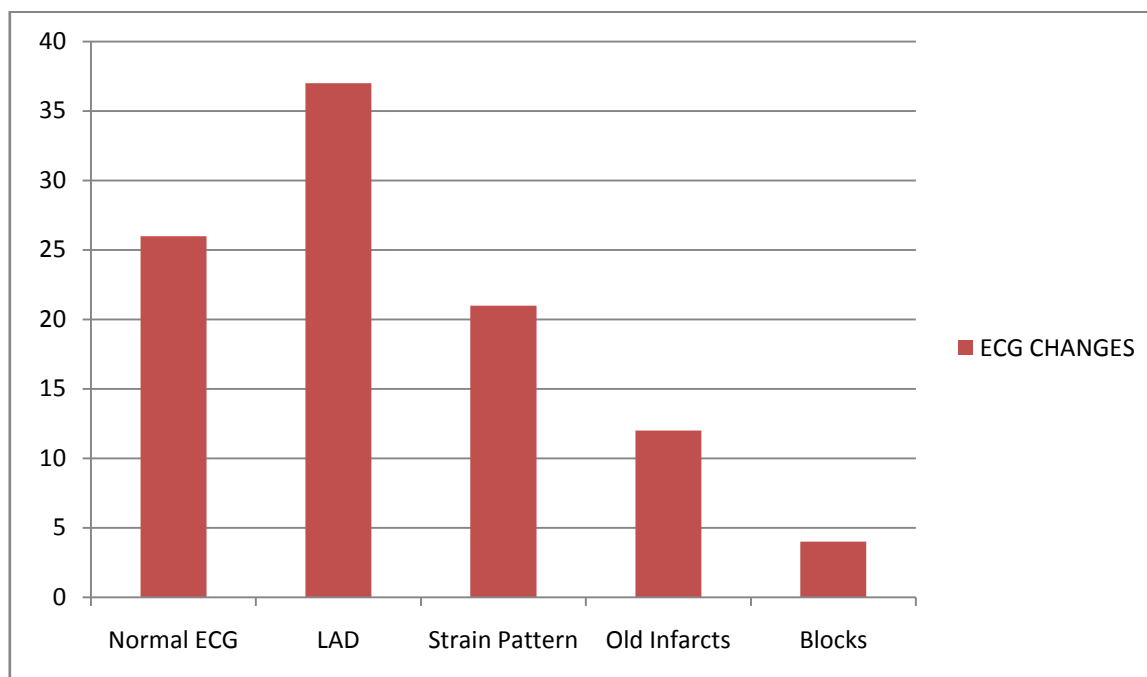
A resting standard 12 lead ECG was done and data collected over 100 patients attending outpatient and inpatient services in RIMS, Ranchi, India .The study was approved by the ethical committee of the institute. The study was carried between March 2016 and September 2017. The patients fulfilled the criteria of Diabetic nephropathy , Type 2 Diabetes mellitus and background hypertension.

Exclusion criteria

1. Type 1 Diabetes mellitus patients are excluded.
2. Patients without background hypertension(SBP >140mm Hg and/or DBP >90 mm Hg) are excluded.
3. Patients with renal diseases without diabetes are excluded.

III. Observation And Result

1. In the study conducted over 100 patients with Diabetic nephropathy and background hypertension in Type 2 Diabetes , 74% showed ECG changes.
2. Amongst these most common was Left axis deviation or LAD(37%), followed by Strain pattern(21%), Old myocardial infarcts(12%) and Blocks(4%). 9% showed QT_C prolongation which overlapped with the above findings.
3. 26% showed normal ECG tracings.



IV. Discussion

The relationship between blood pressure and renal disease is complex. Hypertension may either be a cause or consequence of renal disease or it may be both. Hypertension and Diabetic nephropathy both can lead to cardiovascular ailments. The renal hemodynamic abnormality is similar in both Type 1 and Type 2 Diabetes mellitus. An early physiological abnormality is glomerular hyperfiltration associated with intraglomerular hypertension. This is accompanied by microalbuminuria which is the first clinical sign of Diabetic nephropathy. Diabetic nephropathy is caused by both metabolic(hyperglycemia and hyperlipidemia) and hemodynamic (systemic and glomerular hypertension)alterations. Oxidative stress, inflammatory cytokines and endothelial

dysfunction too plays a role. Oxidative stress consumes nitric oxide which prevents flow mediated dilation of blood vessels (endothelial dysfunction) subjecting the endothelium to injury. This leads to production of cytokines , acceleration of inflammation, worsening of blood vessel rigidity due to atherosclerosis and further impairment of flow mediated dilation and susceptibility to oxidative stress. Inflammation, endothelial dysfunction and oxidative stress forms a vicious cycle that leads to significant kidney damage and cardiovascular events.

V. Conclusion

The above findings suggest that cardiac assessment is must for evaluation of patients with Diabetic nephropathy in Type 2 Diabetes mellitus. The present study again lays emphasis on cardiac assessment for early intervention and decreasing the mortality in patients with Diabetic nephropathy and background hypertension in Type 2 Diabetes mellitus patients.

References

- [1]. Katie Bennett, Bhandari Sumer Aditya : An overview of Diabetic nephropathy, Epidemiology Pathophysiology and treatment. www.thejournalofdiabetesnursing.co.uk
- [2]. ADA: Consensus development conference on the diagnosis and management of nephropathy in patient with diabetes mellitus, Diabetes care, 1998, 17:1357-61
- [3]. Mogensen CE: Early diabetic renal involvement and diabetic nephropathy. Diabetes Annual iii, 1987, 306-21
- [4]. Mogensen CE: The kidney and hypertension in diabetes mellitus, Kluwer Acad Publ, Boston, 1994, 415-516
- [5]. Rollo J: Cases of Diabetes Mellitus. In: Brenner BM (ed) Brenner's the kidney, 5th edition, 1995, 1864-9
- [6]. Fabre J , Balant LP, Dayer PG, et al. The kidney in maturity onset diabetes mellitus. A clinical study of 510 patients. Kidney int 21:730, 1982
- [7]. Grenfall A, Watkins PJ: clinical diabetic nephropathy. Natural history and complications. Clinical endocr Metab 15:783-805, 1986
- [8]. Chugh CS, Asian nephrology, Oxford university press, 656-659, 1994
- [9]. Gale MA, Nielsen FS, Smidt UM, Parving HH: The course of kidney function in Type 2 diabetes mellitus patient with diabetic nephropathy, Diabetologia 36:1071-1078, 1993
- [10]. Larkins RG, Dunlop ME: The link between hyperglycemia and diabetic nephropathy. Diabetologia 35:499-504, 1992
- [11]. Va Hance P, Calver A, Collier J, The vascular endothelium in diabetes and hypertension. J Hypertens 10(suppl)525, 1992
- [12]. Joslin: Long term complications of Diabetes mellitus, 13th edition, 1996
- [13]. Uusitupa M, Siitonen a, Aro A : Prevalance of coronary heart disease, left ventricular failure and hypertension in middle aged, newly diagnosed Type 2 diabetes patients. Diabetologia 28:22-27, 1985
- [14]. Oeckert T : Nephropathy and coronary death, The fatal twins in diabetes mellitus, Nephrol dial transplant 9:1069-1071, 1994
- [15]. Parving HH: Dyslipidemia and cardiovascular disease in NIDDM patients with and without diabetic nephropathy. J. Intern Med(suppl)716: H9-94, 1994
- [16]. Preventive and social medicine: Park's Textbook 19th edition

Dr. Ravish Kumar Sinha " Study of Electrocardiographic Changes in Patients of Diabetic Nephropathy of Type 2 Diabetes Mellitus with Background Hypertension." IOSR Journal of Dental and Medical Sciences (IOSR-JDMS), vol. 17, no. 8, 2018, pp 24-26.