

Biopsy- A Crucial diagnostic aid for oral lesions

Junia Devassy¹, Dr. Bindu R Nayar²

¹P.G Student, ²Professor and HOD, Department of Periodontics, Govt Dental College, Thiruvananthapuram

Corresponding Author: Junia Devassy

ABSTRACT: Biopsy is a valuable aid in diagnosis of diseases which consists of obtaining a specimen of living tissue in order to study its structure, both macro and microscopically. This procedure makes it possible to confirm or deny a diagnosis, as well as to determine the nature and characteristics of the lesion to establish a final diagnosis. As with any disease process in dentistry and medicine, prevention is the best form of therapy and early diagnosis and treatment is the best way of managing pathologic entities. The present paper provides an update on the different biopsy techniques and their indications.

Key Words: Biopsy, oral biopsy, surgical considerations in biopsy, oral diagnosis

Date of Submission: 22-08-2018

Date Of Acceptance: 04-09-2018

I. Introduction

Biopsy, a Greek-derived word (bio-life; opsia-to see) loosely translated as “view of the living”, is defined as removal of tissue from the living organisms for the purpose of microscopic examination and diagnosis. The term “Biopsy” was introduced into medical terminology in 1879 by Ernest Besnier¹. The correlation of the clinical findings with the histopathological observations is useful for diagnosing certain oral lesions². When a lesion is discovered, several important, orderly steps should be undertaken to identify and characterize it (Fig.no.1)³. These steps include the health history, history of the specific lesion, clinical examination, radiographic examination, laboratory investigation, and, if indicated, surgical procedures to obtain a specimen for pathologic examination.³

INDICATIONS

In application to any lip or oral mucosal lesions following the exclusion of local irritants (of traumatic or inflammatory origin), when the lesions in question are seen to persist for more than two weeks, and may be suggestive of malignancy. In general, lesions appearing in the oral mucosa should be explored and evaluated for the possible presence of local irritative factors. If such factors are identified, they must be eliminated, after which an observation period of approximately 15-20 days is indicated. After this period of time, and if the lesions persist, histopathological study is required to discard possible malignancy.

Also for those oral mucosal surfaces that show important and persistent color changes (becoming very white, red or pigmented) or changes in appearance (cracking, proliferation or ulceration), with deep-lying hard masses detected upon palpation. Likewise, evaluation is required of premalignant mucosal lesions or states such as lichen planus or leukoplakia, in persistent atrophic-erosive areas⁴ and for bony lesions that cannot be diagnosed radiographically and which are usually accompanied by pain, sensation alterations or other symptoms.

Any abnormal tissue removed from the oral cavity should be sent for histopathological analysis however confident the clinician may be with the diagnosis⁵. It is useful for the detection of certain systemic illnesses requiring histological confirmation in order to establish the definitive diagnosis, e.g., lupus, amyloidosis, scleroderma, or Sjogren's syndrome - which can be confirmed by an oral tissue biopsy. As an example, confirmation of Sjogren's syndrome requires the obtainment of a sample of the lesser salivary glands of the lips^{4,5}. (Fig.no.2)³

CONTRAINDICATIONS

A biopsy should be avoided in the case of lesions located in very deep regions or in areas of difficult access where the surgical technique proves complicated or hazardous, with the risk of damage to neighboring structures.⁴ It is also contraindicated in very seriously ill patients, in those subjects with some systemic disorder that may worsen, or where secondary complications may develop⁵. It is not advised in the case of multiple neurofibromas, due to the risk of neurosarcomatous transformation, or in tumors of the greater salivary glands. Such biopsies must be performed by specialized surgeons, in order to avoid damaging nearby anatomical structures and causing the spread of tumor cells, as this would adversely affect the prognosis⁶.

In turn, a biopsy would be needless in case of normal anatomical variants such as physiological gingival pigmentation, geographic tongue, linea alba, lingual indentations, protuberances, exostosis etc. The potential morbidity associated with a biopsy done in a previously irradiated region should be considered in deciding whether biopsy is advisable.⁴

CLASSIFICATION OF BIOPSY

Biopsies can also be classified according to the technique used, the material employed, the clinical timing, the location of the target lesion, processing of the sample, and the purpose⁴

1. According to Technique Employed:

- a) Incisional
- b) Excisional
- c) Aspiration
- d) Exfoliative
- e) Stab and Roll
- f) Velscope

a) INCISIONAL BIOPSY:

The incisional technique involves the removal of a representative portion of the target lesion and of a part of healthy tissue. The incisional biopsy is also termed as diagnostic biopsy⁷

Controversy exists as to the possibility that incisional biopsies of malignant lesions may increase the risk of metastasis, by disrupting the barrier preventing migration of the neoplastic cells and thus favouring invasion of the bloodstream at the site of the surgical wound⁸. In certain tumors such as hemangioma or melanoma, the biopsy should be performed with complete and extensive resection of the lesion, in order to avoid severe bleeding or metastatic spread, respectively⁹.

Indications: If the area under investigation appears difficult to excise because of its extensive size (i.e., larger than 1 cm in diameter), hazardous location, or whenever the clinician suspects malignancy, incisional biopsy is indicated.

Principles: A biopsy in wedge fashion should be performed on representative areas of the lesion. The biopsy site should be selected in an area that shows complete tissue changes (the lesion extends into normal tissue at the base or margin [or both] of the lesion)(Fig no.3). Necrotic tissue should be avoided, because it is useless in diagnosis. The material should be taken from the edge of the lesion to include some normal tissue. However, care must be taken to include an adequate amount of abnormal tissue. It is much better to take a deep, narrow biopsy rather than a broad, shallow one, because superficial changes may be quite different from those deeper in the tissue. (fig 3.1)

b) EXCISIONAL BIOPSY:

An excisional biopsy implies removal of the entire lesion, with slight peripheral and in-depth safety margins, applicable to papillomas, fibromas or granulomas. Such biopsies play a diagnostic and therapeutic role, since complete removal of the lesion is carried out, ensuring the inclusion of a peripheral margin of normal tissue⁵. The biopsy should include surrounding normal tissue with adequate depth of underlying connective tissue⁷.

Indications. Excisional biopsy should be used with smaller lesions (less than 1 cm in diameter) that on clinical examination appear to be benign. Any lesion that can be removed completely without mutilating the patient is best treated by excisional biopsy. Pigmented and small vascular lesions should also be removed in their entirety.

Principles

The entire lesion, along with 2 to 3 mm of normal-appearing surrounding tissue, is excised.(fig 4)

c) ASPIRATION BIOPSY:

Aspiration biopsy is the use of a needle and syringe to penetrate a lesion for aspiration of its contents. Two main types of aspiration biopsy are used in clinical practice: The first is used only to determine whether or not a lesion contains fluid or air; the second is used to remove cellular material for diagnostic examination by a pathologist. The latter technique is usually performed by a pathologist trained in the technique of fine needle aspiration (FNA). Patients are frequently referred to pathologists for FNA when a soft tissue mass is detected below the surface of the skin or mucosa during clinical examination. Aspiration of a lesion to determine whether or not it contains fluid is done routinely before opening into radiolucent lesions of the jaws. Inability to aspirate

fluid or air indicates that the mass is probably solid. Aspiration of a lesion can yield extremely valuable information about its nature.

A radiolucent lesion in the jaw that yields straw colored fluid on aspiration is most likely a cystic lesion. If pus is aspirated, an inflammatory or infectious process should be considered (i.e., abscess). Air on aspiration may indicate that a traumatic bone cavity has been entered. Blood on aspiration could represent several lesions, the most important of which is a vascular malformation in the jaw. However, other vascular lesions may produce blood on aspiration. Aneurysmal bone cysts, central giant cell granulomas, and other lesions can produce a bloody aspirate. A fluctuant mass in the soft tissues should also be aspirated to determine its contents before definitive treatment. Any radiolucency in the bone of the jaws should be aspirated before surgical intervention to rule out a vascular lesion that could result in life-threatening hemorrhage if incised. Material obtained by aspiration can be submitted for pathologic examination, chemical analysis, or microbiologic culturing.³

Indications.

Aspiration should be carried out on all lesions thought to contain fluid (with the possible exception of a mucocele) or any intraosseous lesion before surgical exploration

Technique. An 18-gauge needle is connected to a 5 or 10ml syringe. The area is anesthetized and the 18-gauge needle inserted into the depth of the mass during aspiration. The tip of the needle may have to be repeatedly repositioned in an effort to locate a fluid center. For intraosseous lesions, if expansion and thinning of the cortical plates has occurred, the needle may be firmly applied directly through mucoperiosteum to the bone and twisted until it perforates the cortical plate. If this fails, a small mucoperiosteal flap may be elevated and a bur used to penetrate the cortical plate. The needle is then advanced through the cortical hole.³(fig 5)

The aspirated material is smeared on a glass slide and immersed in Hoffman solution (95% ethyl alcohol solution and 5% ether solution) in equal parts. Cytological examination is then performed.¹²

d) EXFOLIATIVE CYTOLOGY:

Two main forms of oral cytology can be used in clinical practice-differing in the method of cellular collection and in diagnosis. The first is exfoliative cytologic examination for tumor cells, which was first described as a diagnostic procedure for detection of uterine cervical malignancy. Although application to the oral cavity has been advocated, it should be used as an adjunct to, not a substitute for, incisional or excisional biopsy. Studies have shown exfoliative oral cytology to be unreliable³.

The second form, oral brush biopsy, is a recent development that is being heavily marketed to dentists. Oral brush cytology uses a special brush to collect the epithelial cells.(fig 3)

Technique of Exfoliative cytology

The lesion is scraped using a cement spatula or tongue depressor. The superficial cells scraped from the area are smeared evenly on a glass slide. The fixation procedure that follows is the same as that for aspiration biopsy, after which the cells are stained.¹²

Technique of Oral Brush Cytology.

The brush is placed in contact with oral epithelium and rotated with firm pressure 5 to 10 times. Properly performed, the brush collects cells from all three layers of the epithelium: (1) the basal,(2)intermediate, and (3) superficial layers. The cellular material collected on the brush is transferred to a glass slide and flooded with fixative.After the slide is dry it is sent to laboratory where the specimen is evaluated by both a computer system and a pathologist to first determine that the biopsy brush has penetrated to the basement membrane. If the biopsy has not collected cells from the full thickness of the epithelium, the dentist will be informed that the sample was inadequate for analysis. The brush cytology should then be repeated. If the sample is adequate, a computer that is specifically programmed to detect oral epithelial dysplastic and malignant cells scans each brush cytology specimen. Images of abnormal cells identified by the computer system are individually displayed on a high-resolution, color video monitor and reviewed by pathologists who are specially trained in computer-assisted analysis of oral brush biopsies.(Fig no.6)

The pathologist classifies the oral brush cytology specimen into one of three categories: (1) negative, (2) positive, and (3) atypical. If a result is positive, the patient should always be referred for scalpel biopsy and histology to grade and stage the lesion.

Indications:

Oral brush cytology may be a good tool for "monitoring" patients with chronic mucosal changes, such as leukoplakia, lichen planus, postirradiation, and patients with a history of oral cancer who require long-term surveillance of their ongoing mucosal changes. The greatest advantage in oral cytology is that it is a chair side test that does not require any topical or local anesthesia and results in minimal discomfort or bleeding. It takes only seconds to perform, and it may therefore be used with more frequency than one might perform or refer for

standard incisional or excisional biopsy. All oral lesions with abnormal brush cytology results, that is, those that are "positive" and "atypical," require scalpel biopsy and histologic evaluation to characterize the lesion completely. Difficulties besetting exfoliative techniques occur when normal epithelium has overgrown the site of a surgical procedure, such as a biopsy or extraction carried out elsewhere, and when only keratinized cells can be found in smears from well-differentiated lesions.¹⁰

(5) Stab and Roll Biopsy:

A stab and-roll technique was used to procure the gingival tissue. This technique is designed to prevent the epithelium from peeling off the biopsy specimen. The occurrence of shear force can be avoided with this technique

Principles: Local anesthetic infiltration was injected around the periphery of the tissue. Direct infiltration into the biopsy site was avoided because hemorrhage or artificial separation of epithelium from its underlying CT could be produced. In this technique, all cutting forces are directed internally to bone. The operator applied gentle pressure on the gingiva with the tip of a no. 15 blade until the bone surface was reached, and then the blade was rolled from the tip along the entire cutting edge (Fig. 3). This allowed the cutting force to be directed in one direction only (internally) rather than internally and laterally as is customary with a conventional cutting stroke. If a larger specimen had been required, the procedure could have been repeated by replacing the tip of the blade into the incision line and performing the rolling stroke until the desired length and angulation were achieved.¹³

(Fig 7)

(6) Velscope:

Visually Enhanced Lesion Scope (VELScope) is a simple, noninvasive, handheld device that permits direct visualization of alterations to tissue fluorescence and is marketed as a screening device for oral cancer.

Principles: VELScope produces a blue excitation light in the wavelength range of 400 to 460 nm which aims to excite green fluorescence from endogenous fluorophores in oral tissue. Optical changes are said to reveal metabolic, biochemical, and structural information about the mucosal cells and map the field of cancerization. Normal oral mucosa emits a pale green autofluorescence and is said to retain fluorescence while abnormal tissue shows loss of autofluorescence and appears dark in contrast. (Fig no.8)

Indications: The device is intended to be used by a surgeon to help identify diseased tissue around a clinically apparent lesion and thus aid in determining the appropriate margin for surgical excision.¹⁴

2. According to Material used:

- a) Conventional scalpel
- b) Punch
- c) Bforceps
- d) Electrocautery
- e) CO₂ Laser

A number of cutting instruments can be used when performing a biopsy: a conventional scalpel, a punch, and the so-called B-forceps. Electroscalpels and CO₂ laser scalpels deserve separate mention, for although they are used by some authors, their associated inconveniences make them scantily recommendable for obtaining a biopsy sample⁴.

The oral mucosal punch is a rapid, simple, safe and inexpensive technique for obtaining a representative sample of most oral zones. The punch is able to obtain several samples at the same time, and at different points, and generates less patient anxiety than the conventional scalpel. However, the punch is unable to remove large lesions, and cannot be used in intensely vascularized or innervated areas. It is likewise not applicable to deep lesions, and is limited to epithelial or superficial mesenchymal target tissues¹¹. (fig no.9)

Other instruments, such as the so-called B forceps, can also be used to obtain a biopsy. This instrument was developed by Bermejo and facilitates, simplifies and especially homogenizes soft tissue biopsies of the oral cavity and of the lesser salivary glands. These forceps are equipped with two cusps - one with a window - to allow compression of the target tissue between them. The target zone is positioned exposed within the window, and the compressive effect of the cusps allows us to work in an ischemic field within the window¹².

Lasers and electrosurgical knives are also often used to perform oral biopsies. These techniques have the advantage of producing a completely bloodless surgical area, but it can induce thermal artifacts. Hence, it is best to excise with a scalpel and use electrosurgery to control hemorrhage at the biopsy site¹².

3. According to Clinical Timing of Sampling

- a) Intraoperative
- b) Extraoperative

Depending on the clinical timing of the biopsy, the procedure can be classified as intraoperative or extraoperative. An intraoperative biopsy allows a rapid histopathological diagnosis. The sampled material is processed without fixation, frozen with dry ice. In this sense, freezing at a temperature of between -40°C and -60°C produces a tissue consistency that allows sectioning with the microtome. The quality of the preparation under such conditions is less ideal, the analysis is more difficult, and the pathologist faces only three diagnostic options: positive, negative or doubtful. On the other hand, an extraoperative biopsy requires a longer processing time. The fixed tissue sample is processed and embedded in paraffin, followed by the cutting and staining of thin sections. These preparations offer greater quality than frozen samples, and histopathological evaluation is therefore easier⁴.

4. According to Sampling location

Depending on the topography involved, the biopsy can be obtained from different locations, the salivary glands, bone, lymph nodes, and other head and neck tissues.

Regarding the salivary glands, it is very common and easy to obtain a biopsy of the lesser salivary glands of the lips for diagnosing or confirming an autoimmune condition such as Sjögren's syndrome. Following local anesthetic infiltration of the zone, a small incision measuring approximately 10 mm is made in the mucosa of the lower lip; the thickness of the sample should be sufficient to obtain the glands without affecting the muscle layer or arteries. In the case of retention cysts such as lip mucoceles, an excisional biopsy is indicated. On the other hand, when biopsying the greater salivary glands, and specifically the parotid gland, fine-needle aspiration biopsies (FNAB) are increasingly used, due to their non-invasive nature⁴.

A bone biopsy in turn constitutes an indirect technique. These procedures are usually more difficult, and require the raising of a soft tissue flap and an adequate approach to the bone layer. After raising the mucoperiosteal flap, a chisel and mallet are used, or the target zone is drilled to obtain the specimen. In this sense, mention should be made of the trephine drill, composed of a hollow cylinder with a cutting edge, that allows the harvesting of bone cylinders of different sizes. In the case of certain bone tumors, a piece of trabecular bone can be collected using a curette.

Lymph node biopsy is also an indirect procedure. In this context, adenopathies are commonly the result of inflammatory or neoplastic processes. Prior clinical evaluation and laboratory testing is required before biopsying lymph nodes.

HOW TO PERFORM AN ORAL BIOPSY

The materials and instrumentation required to perform an oral biopsy are not particularly sophisticated. The necessary instruments are limited to those commonly employed in surgery, such as a mouth mirror, exploratory probe, toothless dissection forceps, mosquito forceps, scalpel handpiece and number 15 blade, syringe for anesthesia, pressure forceps, scissors, periostome, needle carriers and suturing kit. For bone biopsies we can use a chisel and mallet, a motor-driven handpiece with drills, and curettes. As to the required material, an ejector, gauze, sterile gloves and a plastic or glass bottle containing 10% formalin solution is advised. As with any surgical procedure, a biopsy requires due sterilization of the instrumentation and disinfection of the surgical field.⁴

Most target lesions are found in soft tissues such as the tongue, cheek mucosa or lips, or in more adhered regions such as the palate and gums. Anaesthesia with a vasoconstrictor to minimize bleeding should not be applied in the actual biopsy target zone but rather at a certain distance, to avoid alterations.

Traction suture or tissue forceps are to be used to fix the tissue to be removed. Traction sutures offer the advantage of orienting at least one lesion surface for the pathologist. Surgery is moreover facilitated, and compression or destruction of the specimen is avoided⁴.

The specimen should be obtained by means of a clean and deep cut, taking care in extraction to avoid tearing or compression, as this could cause alterations. In excisional biopsies, the lesion is to be palpated carefully, determining its depth, and the incisions should slightly exceed the total depth of the lesion. In incisional biopsies, any depth within the lesion allowing the obtainment of sufficient material for study is considered acceptable. The incision should include a significant portion of the suspect tissue and a part of adjacent normal tissue¹³.

Specimen Care

After removal the tissue should be immediately placed in 10% formalin solution (4% formaldehyde) that is at least 20 times the volume of the surgical specimen. The tissue must be immersed in the solution, and care should

be taken to be sure that the tissue has not become lodged on the wall of the container above the level of the formalin. The container in which the specimen is placed should have a wide opening, as it may be difficult to retrieve from a container with narrow opening.

ARTIFACTS

The specimens obtained with oral biopsy procedures are typically small, and the risk of artifacts is considerable. These artifacts, which are sometimes seen under the microscope, may pose a problem for establishing a correct histopathological diagnosis. Biopsy artifacts are due to defective sampling techniques, problems during transport, or incorrect processing of the tissue in the laboratory. A small sample usually consists of a narrow strip of delicate mucosa, which tends to fold onto itself during fixation. When this happens, the junction between the epithelial and connective tissue components is usually lost – particularly if the specimen lacks an underlying submucosal or muscle tissue layer. On one hand, when the tissue is removed with excessive force, the epithelium and connective component may suffer important damage.⁴

Different techniques to minimise artifacts

A. Traditional method of using the toothed tissue forceps to grasp the specimen should be avoided. Alternatively, blunt forceps instead of toothed forceps can be used to grasp the tissue and to grasp the tissue away from the main site of interest.

B. A better option to handle the tissue is to pass the suture and hold it with the artery forceps, which provides the traction and controls the specimen, aiding biopsy

Punch biopsy technique induces fewer artifacts compared with the conventional incisional scalpel biopsy. But, this oral mucosal punch may be difficult to biopsy freely movable tissues (e.g., soft palate, floor of mouth).¹⁵

COMPLICATIONS

Oral cavity biopsies can give rise to complications, though in most cases such problems can be minimized by making use of a careful surgical technique. Bleeding may occur in the first 24 hours after the procedure, as a result of clot disruption during the early healing period, or secondary to suture loosening. Minor bleeding responds to local pressure application, while more important bleeding requires ligation, cauterization or the closure of some bleeding point⁴. Another possible complication of oral biopsies is sensory impairment. This type of problem may result from a defective surgical technique, and can be avoided. Sensory defects are secondary to sensory nerve damage during the biopsy procedure. The symptoms are paresthesia of variable intensity that can persist for hours or even several months, depending on the magnitude of the damage caused.

II. Conclusion

For entities of uncertain significance or etiology, a biopsy provides the simplest and most speedy means of obtaining the perfect diagnosis. It is important for dentists to be aware of how to deal with pathology and to understand about the investigating techniques that might assist in fetching the diagnosis.

References

- [1]. Zerbino DD. Biopsy: Its history, current and future outlook. 1994;3(4):1-9
- [2]. Jornet P, Nicolas A, Beneyto Y, Soria M. Attitude towards oral biopsy. *Med Oral Patol Oral Cir Bucal*. 2007;12:E116-21
- [3]. Peterson L J, Hupp J R, Ellis E, Tucker M R. Management of oral pathological lesions. Chapter 21. *Contemporary of Oral and Maxillofacial Surgery*. 4th ed. 2003:457-478.
- [4]. Ramirez A M, Silvestre F J, Simo J M. Oral biopsy in dental practice. *Med Oral Patol Oral Cir Bucal*. 2007;12(7):E504-10.
- [5]. Gandolfo S, Carbone M, Carozzo M, Scamuzzi S. Biopsy technics in oral oncology: excisional or incisional biopsy? A critical review of the literature and the authors' personal contribution. *Minerva Stomatol*. 1993;42(3):69-75
- [6]. Kumaraswamy K L, Vidhya M, Rao P, Mukunda A. Oral biopsy: Oral pathologist's perspective. *Journal of Cancer Research and Therapeutics*. 2012; 8 (2):192-200
- [7]. Shafer WG. A textbook of oral pathology. 5th ed. Philadelphia: WB Saunders. 2005:821-4.
- [8]. Shklar G. The effect of manipulation and incision on experimental carcinoma of hamster buccal pouch. *Cancer Res*. 1968 Nov;28(11):2180-2
- [9]. Bramley PA, Smith CJ. Oral cancer and precancer: establishing a diagnosis. *Br Dent J*. 1990;168(3):103-7.
- [10]. Cooke B. Exfoliative Cytology in Evaluating Oral Lesions. *J. dent. Res. Supplement*. 1963;42:343-347
- [11]. Lynch DP, Morris LF. The oral mucosal punch biopsy: indications and technique. *J Am Dent Assoc*. 1990;121(1):145-9.
- [12]. Frangos. Chapter 11. Biopsy and Histopathological Examination. *Oral Surgery*. Springer. :281-298
- [13]. Endo H, Rees, Allen et al. A Stab-and-Roll Biopsy Technique to Maintain Gingival Epithelium for Desquamative Gingivitis. *J Periodontol*. 2014 ;85(6):801-809
- [14]. Farah CS, McIntosh L, Georgiou A. Efficacy Of Tissue Autofluorescence Imaging (Velscope) In The Visualization Of Oral Mucosal Lesions. *Wiley Online Library*. 2011;1-5
- [15]. Eisen D. The oral mucosal punch biopsy. A report of 140 cases. *Arch Dermatol*. 1992;128(6):815-7
- [16]. Keszler A. Biopsies: practical standards for correct technic. *Rev Asoc Odontol Argent*. 1988;76(3):100

Fig no.1

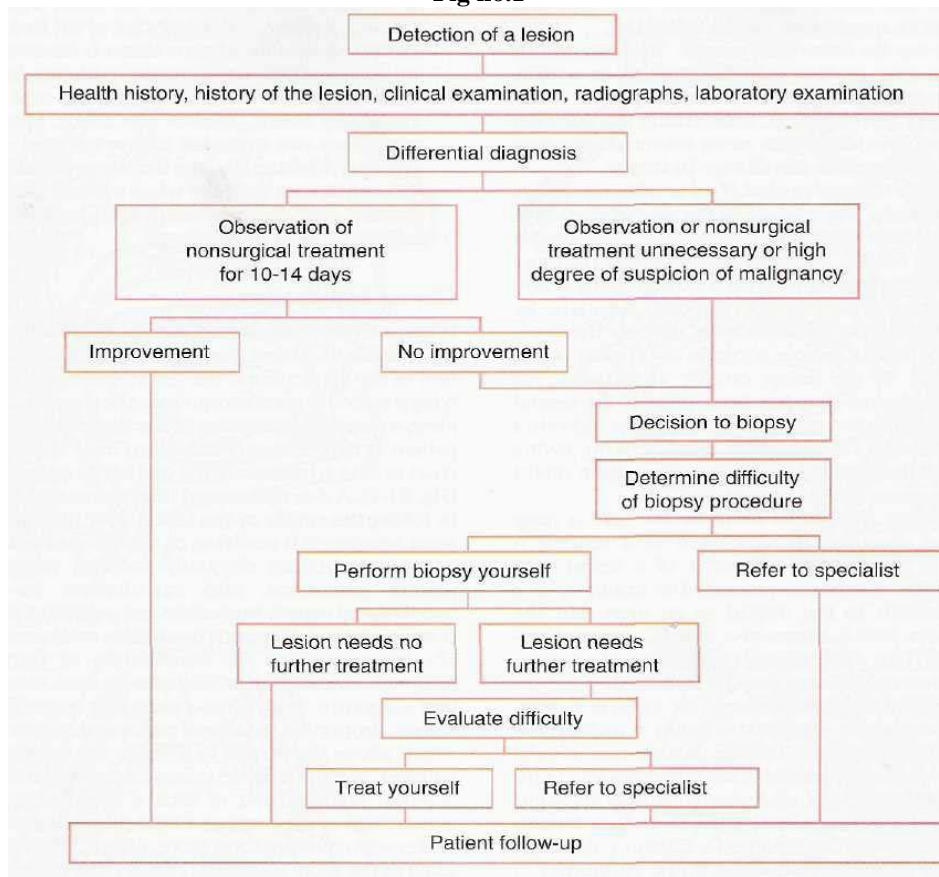


Fig no.2 **INDICATIONS**

- Any lesion that persists for more than 2 weeks with no apparent cause
- Any inflammatory lesion that does not respond to local treatment after 10 to 14 days (after removing local irritant)
- Persistent hyperkeratotic changes in surface tissues
- Any persistent tumescence, either visible or palpable beneath relatively normal tissue
- Inflammatory changes of unknown cause that persist for long periods
- Lesions that interfere with local function (e.g., fibroma)
- Bone lesions not specifically identified by clinical and radiographic findings
- Any lesion that has the characteristics of malignancy (Box 21-3)

Fig no.3

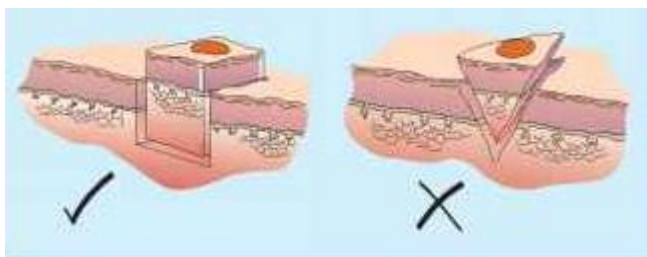


Fig no.3.1

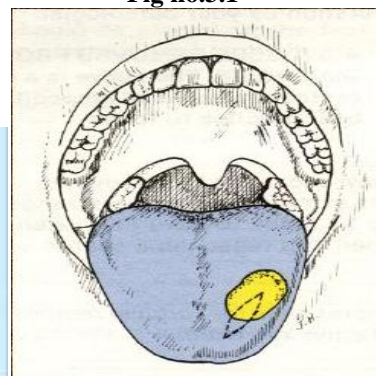


Fig no. 4

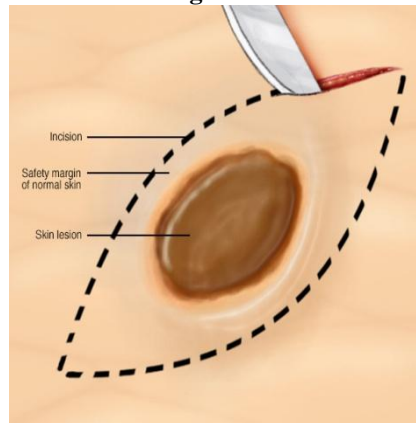


Fig no.5

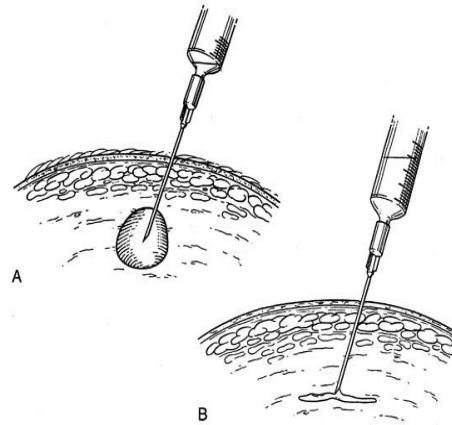
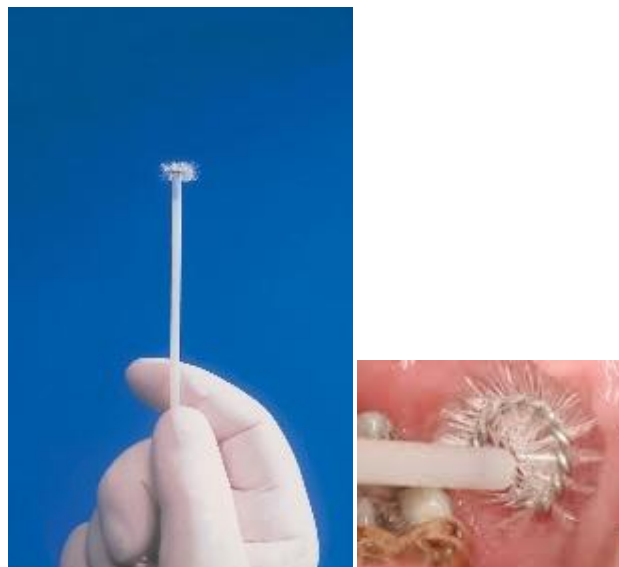
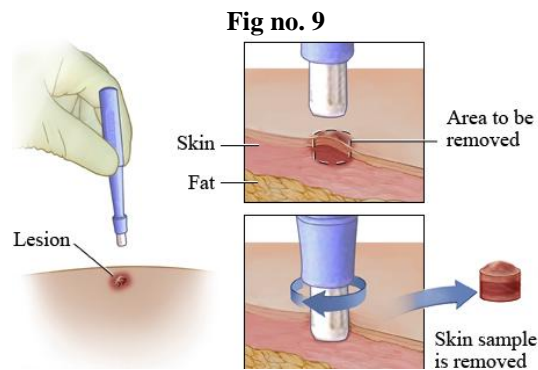
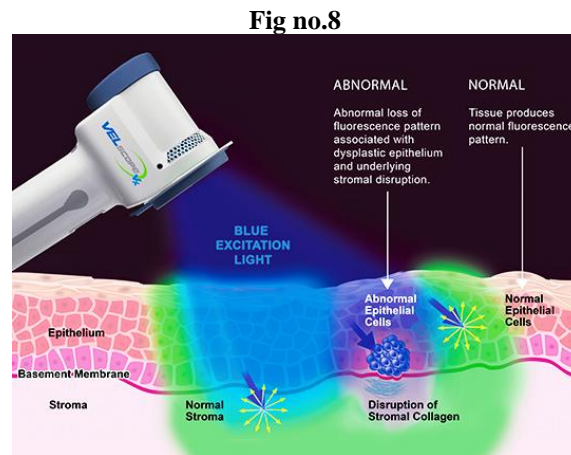
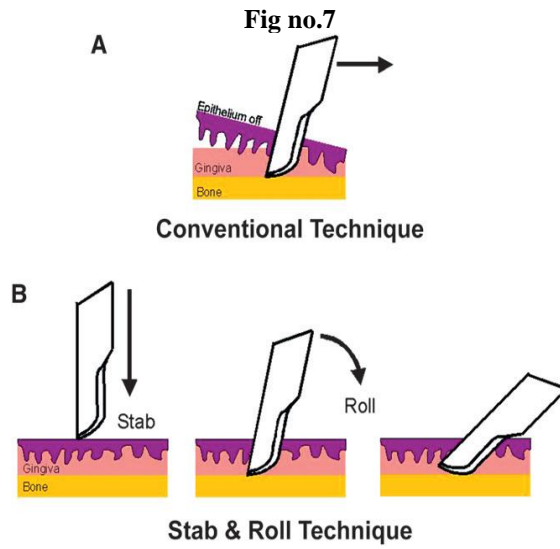


Fig no. 6





Junia Devassy." Biopsy- A Crucial diagnostic aid for oral lesions."IOSR Journal of Dental and Medical Sciences (IOSR-JDMS), vol. 17, no. 9, 2018, pp 16-24.