

## Role of Hysteroscopic Evaluation in Abnormal Uterine Bleeding and its histopathological co-relation.

Sabrina Mhapankar, Swapna kadam, Ajita goli, Sushil Kumar

Correspondence author: Sabrina Mhapankar

**Abstract:** The present study was conducted to assess the feasibility and accuracy of hysteroscopy in evaluation of intrauterine abnormalities in women with abnormal uterine bleeding and to correlate it with histopathological evaluation. 50 women in the reproductive, perimenopausal and postmenopausal age group, up to the age of 65 years presenting with AUB were included as per the inclusion and exclusion criteria. All patients underwent a hysteroscopic examination followed by a biopsy and histopathological evaluation. Hysteroscopic findings were noted and compared with histopathological findings. Sensitivity, specificity, PPV, NPV and accuracy of hysteroscopy was calculated.

**Results:** Maximum age incidence was between 41-50 years (46%). Of the 100 patients, maximum number of women (66%) had symptoms for less than 6 months, 13 patients (26%) had symptoms for 6 months to 1 year and 4 patients (8%) had symptoms for more than 1 year. Out of total 50 patients, 42% presented with Menorrhagia. The second commonest presentation was metrorrhagia (32%). There were 7 cases (14%) with Polymenorrhoea and 14 (28%) patients with post-menopausal bleeding and 6% had intermenstrual spotting. Of the 50 patients, 46 cases (92%) were Multiparous, and 4 cases (8%) were Nulliparous. Abnormal findings were seen in 35 patients (70%), while in the remaining 15 patients (29%), no abnormality was detected (negative hysteroscopic view). The most common abnormality was endometrial Hyperplasia (20% cases), followed by Endometrial Polyps (18%) and submucosal fibroids (16%). There were also 7 cases (14%) of endometrial atrophy and 1 case of endometrial carcinoma. Of the 50 cases, 23 (46%) were normal on histopathology. The most common abnormality observed was polyp (20% cases), followed by submucosal fibroids (16%), endometrial Hyperplasia (14%) and endometrial carcinoma (4%). The sensitivity, specificity, PPV and NPV of Hysteroscopy to diagnose polyp was 90%, 100%, 100% and 97.6% respectively. All the cases of fibroids were correctly diagnosed by hysteroscopy, thus sensitivity, specificity, PPV and NPV of Hysteroscopy were all 100%.

The sensitivity, specificity, PPV and NPV of Hysteroscopy to diagnose endometrial hyperplasia was 85.7%, 90.7%, 60% and 97.5% respectively. The sensitivity, specificity, PPV and NPV of Hysteroscopy to diagnose endometrial carcinoma was 50%, 100%, 100% and 98% respectively.

Date of Submission: 12-09-2018

Date of acceptance: 28-09-2018

### I. Introduction

Abnormal uterine bleeding (AUB) is a term used to describe any change in the duration of a menstrual cycle, the amount or duration of blood loss. Up to 33% of women referred to gynecological outpatient clinics present with AUB and the proportion rises in perimenopausal and postmenopausal women (1, 2). Although AUB may be due to various causes, FIGO has classified the aetiologies into nine main categories, namely (PALM-COEIN): polyp, adenomyosis, leiomyoma, malignancy and hyperplasia, coagulopathy, ovulatory dysfunction, endometrial, iatrogenic, and not yet classified. The components of PALM group are discrete (structural) entities that can be measured visually with imaging techniques and/ or histopathology, whereas the COEIN group is related to entities that are not defined by imaging or histopathology (nonstructural) (3). AUB affects a woman adversely with respect to her social life, quality of living and thereby her efficiency. Diagnosing the aetiology of AUB can be difficult even with a thorough history and clinical examination. Various diagnostic techniques like dilatation and curettage (D&C), transvaginal ultrasonography and saline infusion sonography and hysteroscopy have evolved over a period of time to determine the etiology of abnormal uterine bleeding. The judicious use of hysteroscopy to manage this medical entity adds a new dimension in handling this often-perplexing problem. This technique has replaced dilatation and curettage (D&C), which is a blind technique with a high diagnostic failure rate (4,5). Hysteroscopy as an outpatient procedure is an important diagnostic tool in AUB. Although, the major role of out-patient hysteroscopy in the management of AUB is diagnostic, there is scope for simple operative procedures such as polypectomy and targeted endometrial biopsy. Since hysteroscopy and its directed biopsy is more accurate than dilatation and curettage, it is considered an accurate 'gold standard' in uterine pathology (6,7). The present study was thus taken up to assess

the feasibility and accuracy of hysteroscopy in evaluation of intrauterine abnormalities in women with abnormal uterine bleeding and to correlate it with histopathological evaluation.

## **II. Material and methods**

### **Study Design**

Hospital Based Screening Test Study

### **Study Duration**

July 2015 - June 2017

### **Study Area**

Department of Obstetrics and Gynecology, MGM Hospital and medical college, Navi Mumbai.

### **Sampling Technique & Sample Size:**

Consecutive type of non-probability sampling was used for selection of study subjects. A total of 50 consecutive cases of AUB were taken up for the study after informed consent.

### **Inclusion criteria**

1. Age  $\geq$  18 years
2. Patients not on any extrinsic hormonal therapy
3. Normal PAP smear findings
4. No obvious extra-uterine pathology on USG

### **Exclusion criteria**

1. Abnormal PAP smear findings
2. Acute Pelvic Infection (positive swab test)
3. Pregnancy
4. Anaemia
5. Coagulation disorders

### **Study Methodology**

All 50 patients in reproductive, perimenopausal and postmenopausal age group upto the age of 65 years presenting with AUB were included after informed consent. Demographic details and clinical history was taken for all patients. General, systemic and local pelvic examination to record the size and position of the uterus, its mobility and the presence of any cervical or adnexal masses was also carried out. After the necessary preoperative investigations all patients were admitted and standard preoperative preparations were carried out.

Hysteroscopy followed by guided biopsy was performed for all patients under total intravenous anesthesia (TIVA). Patient was put in lithotomy position and the findings of examination under anesthesia (EUA) were recorded. We used a rigid continuous flow panoramic hysteroscope, 25 cm in length, 2.9 mm in diameter with an outer sheath of 4 mm and a 30-degree fibro optic lens (Karl Storz, Germany). A fibro optic cable was connected to the light source and to the hysteroscope. Hysteroscopy was performed with normal saline as distention media.

Hysteroscope was inserted inside the uterus gradually after negotiating the external os and cervical canal. once the cavity was entered, a panoramic view of the uterine cavity was taken to exclude uterine malformations or a deformed cavity. Examination was then done systematically, first the fundus, anterior, posterior and lateral walls of the uterus ending by visualization of the uterotubal junctions.

In case of any intrauterine pathology detected, the shape, size and site of it was noted. The thickness, color, vasculature and consistency of the mucous membrane covering the uterine cavity was observed and recorded.

### **Diagnostic Criteria for**

#### **Endometrial hyperplasia: (8)**

- i) Increased endometrial thickness
- ii) Non-homogenous endometrial regeneration
- iii) Increased vascularisation
- iv) Polypoid formation
- v) Cystic dilatation
- vi) Necrotic areas

**Endometrial carcinoma(8)**

- i) Irregular, polylobular, delicate excrescences which are partly necrotic or bleeding,
- ii) Vascularization is also irregular and anarchic.

Biopsy or gross specimen of pathological lesion if any was obtained and sent for histopathological evaluation.

**Statistical Analysis**

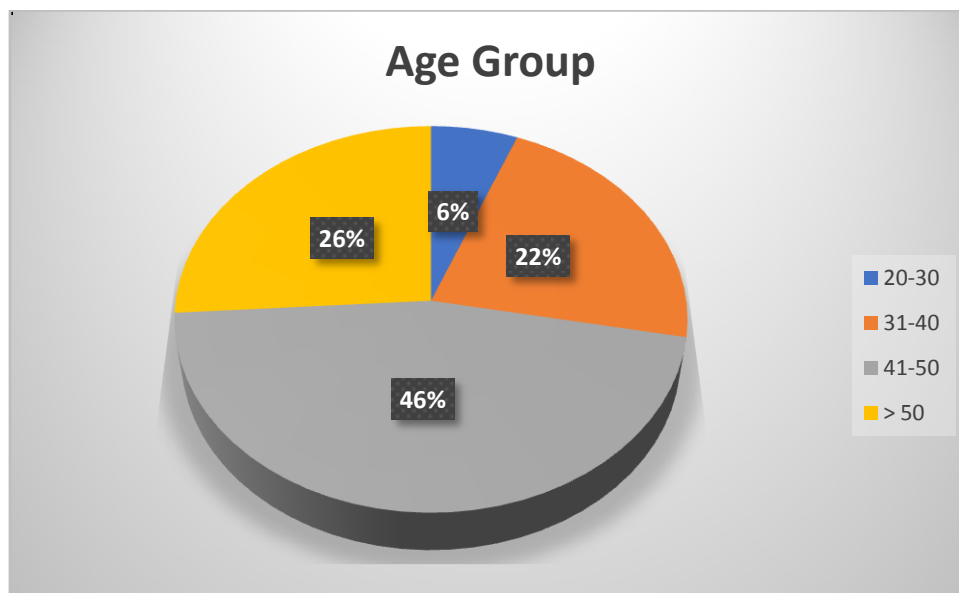
All the collected data was entered in Microsoft Excel Sheet 2007. The data was then transferred and analyzed using SPSS ver. 21. Qualitative data was represented in the form of frequency and percentage while quantitative data was represented using Mean +/- S.D. Appropriate statistical evaluation was carried out as per the type and distribution of data. A p-value of < 0.05 was taken as level of significance

**III. Results**

**Table 1. Distribution of subjects based on Age group**

Age Group (years)	N	%
20-30	3	6.0%
31-40	11	22.0%
41-50	23	46.0%
> 50	13	26.0%
<b>Total</b>	<b>50</b>	<b>100.0%</b>

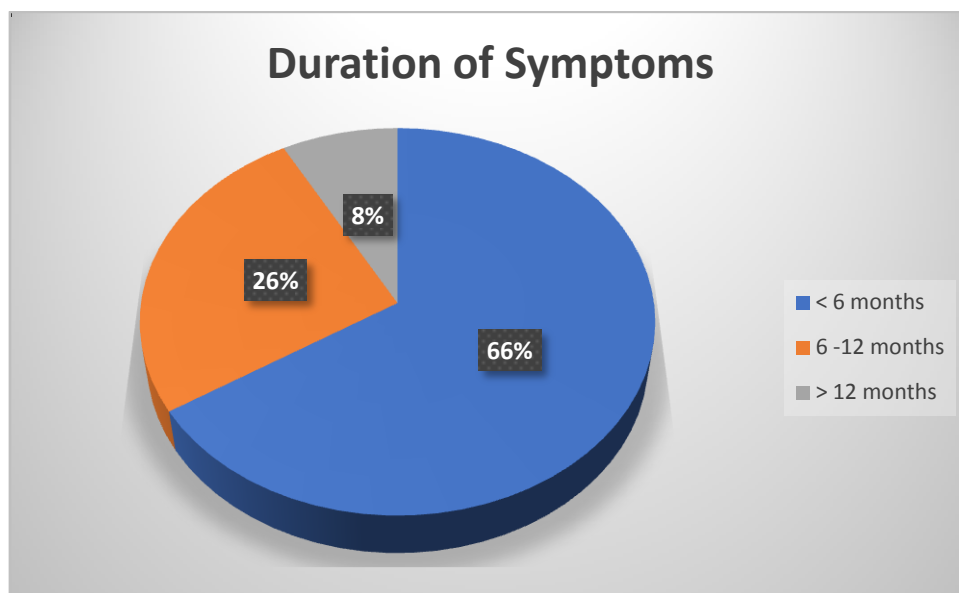
In the present study, maximum age incidence was between 41-50 years (46%). The youngest patient in this study was 22 years old and the oldest was 68 years old.



**Table 2. Distribution of subjects based on duration of symptoms**

Duration of Symptoms	N	%
< 6 months	33	66.0%
6 -12 months	13	26.0%
> 12 months	4	8.0%
<b>Total</b>	<b>50</b>	<b>100.0%</b>

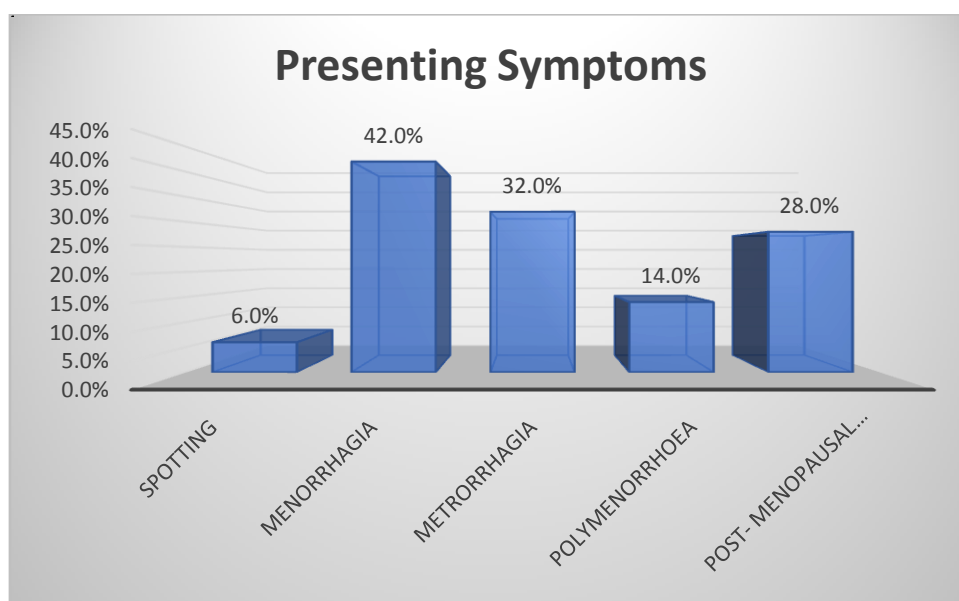
Of the 100 patients, maximum number of women (66%) had symptoms for less than 6 months, 13 patients (26%) had symptoms for 6 months to 1 year and 4 patients (8%) had symptoms for more than 1 year.



**Table 3. Distribution of subjects based on presenting symptoms**

Symptoms	N	%
Intermenstrual spotting	3	6.0%
Menorrhagia	21	42.0%
Metrorrhagia	16	32.0%
Polymenorrhoea	7	14.0%
Post- menopausal bleeding	14	28.0%

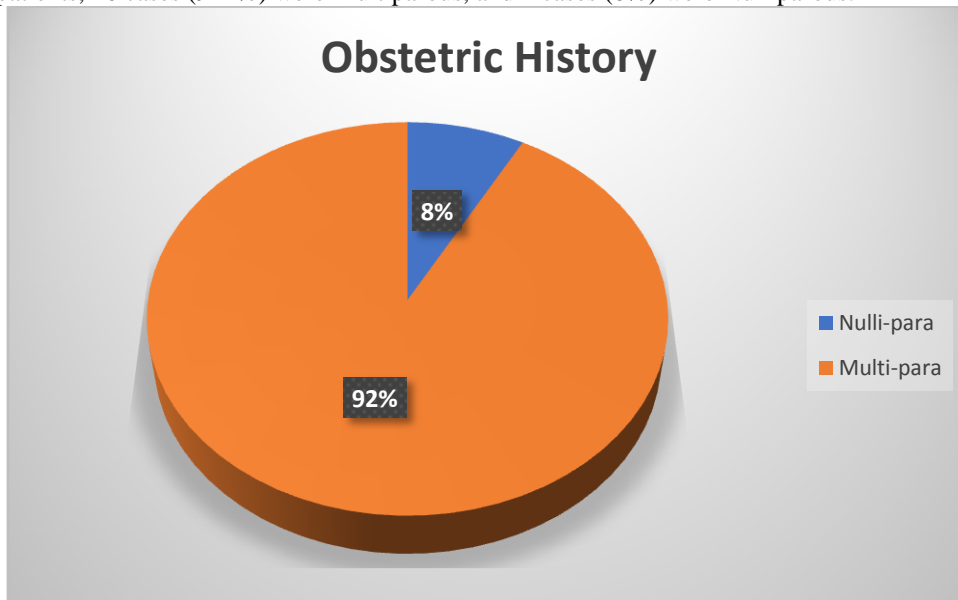
Out of total 50 patients, 42% presented with Menorrhagia. The second commonest presentation was metrorrhagia (32%). There were 7 cases (14%) with Polymenorrhoea and 14 (28%) patients with post-menopausal bleeding and 6% had intermenstrual spotting.



**Table 4. Distribution of subjects based on Obstetric History**

Obstetric History	N	%
Nulli-para	4	8.0%
Multi-para	46	92.0%
Total	50	100.0%

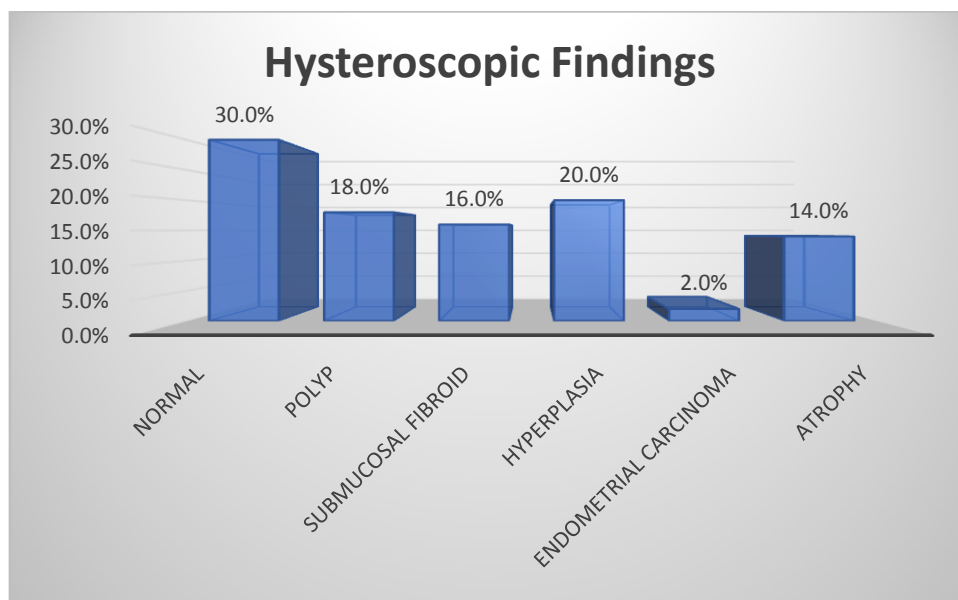
Of the 50 patients, 46 cases (92%) were Multiparous, and 4 cases (8%) were Nulliparous.



**Table 5. Distribution of subjects based on Hysteroscopic findings**

Hysteroscopic Findings	N	%
Normal	15	30.0%
Polyp	9	18.0%
Submucosal Fibroid	8	16.0%
Hyperplasia	10	20.0%
Endometrial Carcinoma	1	2.0%
Atrophy	7	14.0%
<b>Total</b>	<b>50</b>	<b>100.0%</b>

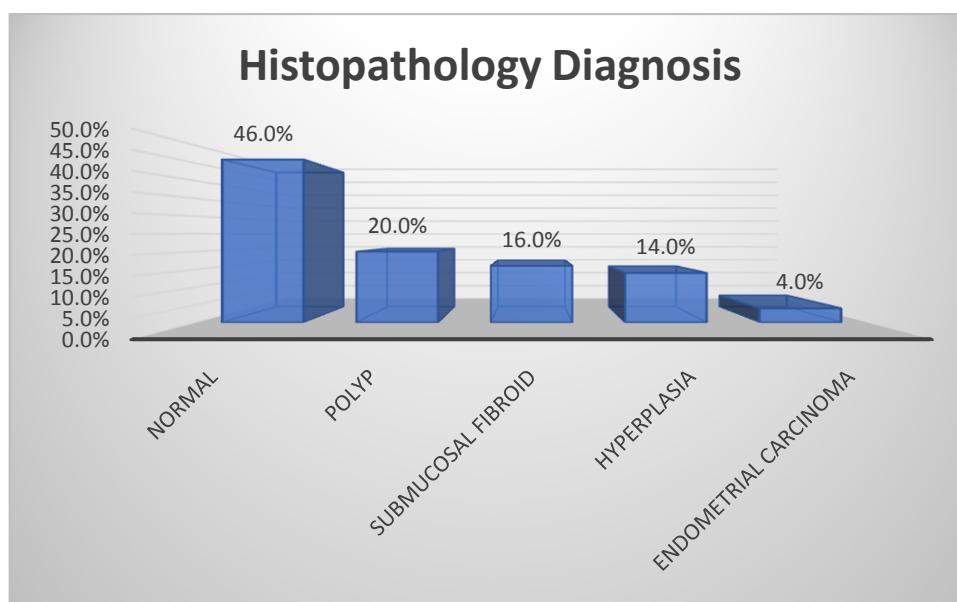
Abnormal findings were seen in 35 patients (70%), while in the remaining 15 patients (29%), no abnormality was detected (negative hysteroscopic view). The most common abnormality was endometrial Hyperplasia (20% cases), followed by Endometrial Polyps (18%) and submucosal fibroids (16%). There were also 7 cases (14%) of endometrial atrophy and 1 case of endometrial carcinoma.



**Table 6. Distribution of subjects based on Histopathological Diagnosis**

Histopathological Diagnosis	N	%
Normal	23	46.0%
Polyp	10	20.0%
Submucosal Fibroid	8	16.0%
Hyperplasia	7	14.0%
Endometrial Carcinoma	2	4.0%
<b>Total</b>	<b>50</b>	<b>100.0%</b>

Of the 50 cases, 23 (46%) were normal on histopathology. The most common abnormality observed was polyp (20% cases), followed by submucosal fibroids (16%), endometrial Hyperplasia (14%) and endometrial carcinoma (4%).



**Table 7. Diagnostic efficacy of Hysteroscopy for polyps**

Hysteroscopy – Polyp	Histopath - Polyp		Total
	Yes	No	
Yes	9	0	9
No	1	40	41
<b>Total</b>	<b>10</b>	<b>40</b>	<b>50</b>

Parameters	%
Sensitivity	90.0%
Specificity	100.0%
Positive Predictive Value	100.0%
Negative Predictive Value	97.6%

The sensitivity, specificity, Positive Predictive Value and Negative Predictive Value of Hysteroscopy to diagnose polyp was 90%, 100%, 100% and 97.6% respectively.

**Table 8. Diagnostic efficacy of Hysteroscopy for Submucous Fibroid**

Hysteroscopy - Submucos Fibroid	Histopath - Submucos Fibroid		Total
	Yes	No	
Yes	8	0	8
No	0	42	42
Total	8	42	50

Parameters	%
Sensitivity	100.0%
Specificity	100.0%
Positive predictive Value	100.0%
Negative Predictive Value	100.0%

All the case of fibroids were correctly diagnosed by hysteroscopy, thus sensitivity, specificity, Positive predictive Value and Negative Predictive Value of Hysteroscopy were all 100%.

**Table 9. Diagnostic efficacy of Hysteroscopy for Endometrial Hyperplasia**

Hysteroscopy - Endometrial Hyperplasia	Histopath - Endometrial Hyperplasia		Total
	Yes	No	
Yes	6	4	10
No	1	39	40
Total	7	43	50

Parameters	%
Sensitivity	85.7%
Specificity	90.7%
Positive Predictive Value	60.0%
Negative Predictive Value	97.5%

The sensitivity, specificity, Positive Predictive Value and Negative Predictive Value of Hysteroscopy to diagnose endometrial hyperplasia was 85.7%, 90.7%, 60% and 97.5% respectively.

**Table 10. Diagnostic efficacy of Hysteroscopy for Endometrial carcinoma**

Hysteroscopy - Endometrial Carcinoma	Histopath - Endometrial Carcinoma		Total
	Yes	No	
Yes	1	0	1
No	1	48	49
Total	2	48	50

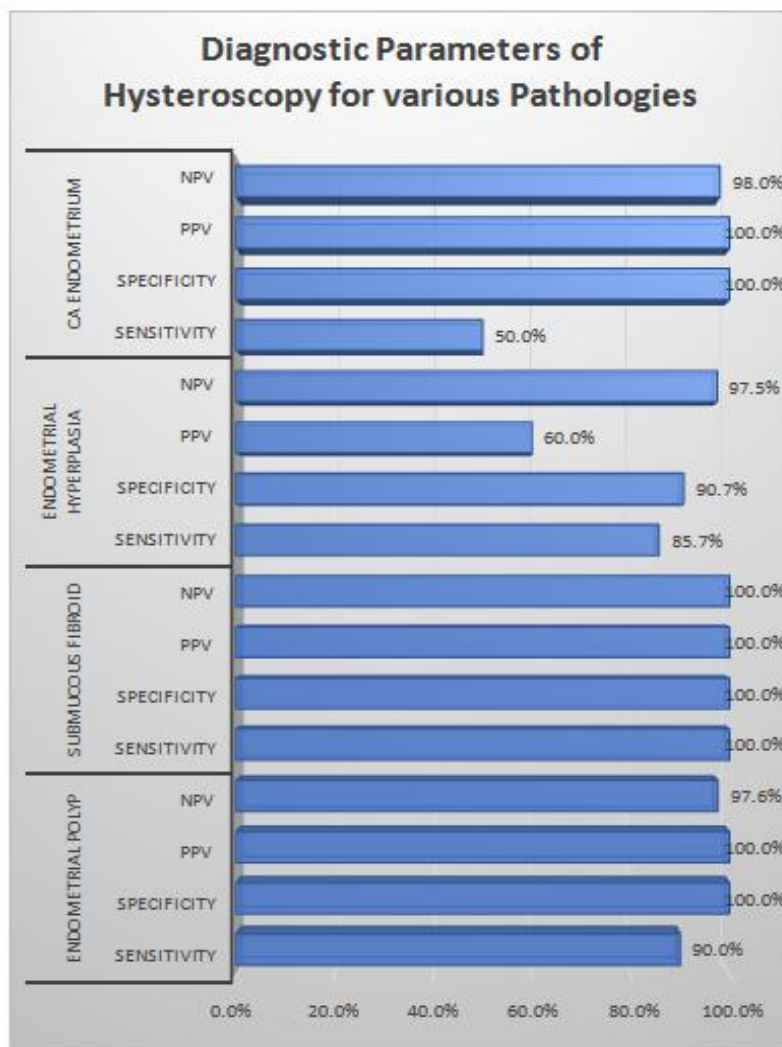
Parameters	%
Sensitivity	50.0%
Specificity	100.0%
Positive Predictive Value	100.0%
Negative Predictive Value	98.0%

*Role of Hysteroscopic Evaluation in Abnormal Uterine Bleeding and its histopathological co-relation.*

The sensitivity, specificity, Positive Predictive Value and Negative Predictive Value of Hysteroscopy to diagnose endometrial carcinoma was 50%, 100%, 100 and 98% respectively.

**Table 11. Diagnostic efficacy of Hysteroscopy for all pathologies**

Pathological lesions	Accuracy	Hysteroscopy
Endometrial Polyp	Sensitivity	90.0%
	Specificity	100.0%
	Positive Predictive Value	100.0%
	Negative Predictive Value	97.6%
Submucous Fibroid	Sensitivity	100.0%
	Specificity	100.0%
	Positive Predictive Value	100.0%
	Negative Predictive Value	100.0%
Endometrial Hyperplasia	Sensitivity	85.7%
	Specificity	90.7%
	Positive Predictive Value	60.0%
	Negative Predictive Value	97.5%
CA Endometrium	Sensitivity	50.0%
	Specificity	100.0%
	Positive Predictive Value	100.0%
	Negative Predictive Value	98.0%





#### IV. Discussion

Hysteroscopy is an important method for the diagnosis of intrauterine pathology in several gynecologic complaints including abnormal uterine bleeding (AUB). Sensitivity and specificity of hysteroscopy is high in a large series of hysteroscopies performed in cases of Abnormal uterine bleeding (9-12). The various causes of AUB namely endometrial polyp, submucous myoma etc. are often missed on conventional diagnostic procedures like USG and dilatation and curettage (13). The present study was thus conducted to assess the feasibility and accuracy of hysteroscopy in evaluation of intrauterine abnormalities in women with abnormal uterine bleeding.

##### Age Distribution

In the present study, maximum age incidence was between 41-50 years (46%). The youngest patient in this study was 22 years old and the oldest was 68 years old.

Panda et al. (14) found that maximum age incidence was between 35-45 years in range between 25-70 years. In Gianninoto's (15) series, age range was 30-80 years and commonest incidence was between 30-45 years. Trotsenburg (16) reported maximum age incidence between 41-50 years. Similar observations were also made by other authors (9,10,11,12,17,18).

##### Clinical Presentation

In present study, out of total 50 patients, 42% presented with Menorrhagia. The second commonest presentation was metrorrhagia (32%). There were 7 cases (14%) with Polymenorrhagia and 14 (28%) patients with post-menopausal bleeding and 6% had intermenstrual spotting.

Panda et al. [14] series had 60% cases of menorrhagia followed by Polymenorrhagia and Metrorrhagia. Similar findings were also observed by Gita G et al. (17). and Sunitha et al. (18). Goyal et al. in their study also observed menorrhagia as the commonest presenting symptom in the study population (58%) followed by metrorrhagia, menometrorrhagia and continuous bleeding >21 days (11). In a study, Chhikara A et al. assessed the accuracy of the hysteroscopic diagnosis with that of histopathological reports obtained by endometrial sampling. The most common symptom was menorrhagia (40%) followed by metrorrhagia 38%, polymenorrhagia (12%) and postmenopausal bleeding (10%). (12)

##### Hysteroscopy Findings

Abnormal findings were seen in 35 patients (70%), while in the remaining 15 patients (29%), no abnormality was detected (negative hysteroscopic view). The most common abnormality was endometrial Hyperplasia (20% cases), followed by Endometrial Polyps (18%) and submucosal fibroids (16%). There were also 7 cases (14%) of endometrial atrophy and 1 case of endometrial carcinoma. Overall percentage of abnormal findings observed on Hysteroscopy in abnormal uterine bleeding cases by various authors is given in table below.

Author	Abnormal Hysteroscopy (%)
Wamsteker et al. (19)	58.5
Gimpelso et al. (7)	40
Loffer et al. (20)	51.44
Sheth et al. (21)	56
Neumann et al. (22)	44.8
Panda et al. (14)	53.4
Gianninoto et al. (15)	75
de Wit AC et al. (23)	75.8
Present Series	70

##### Etiology of Abnormal Uterine Bleeding

The most common abnormality observed on Histopathology was polyp (20% cases), followed by submucosal fibroids (16%), endometrial Hyperplasia (14%) and endometrial carcinoma (4%).

Panda (14) found endometrial hyperplasia in 28.3%, Wamsteker et al. (19) found endometrial polyp in 19%, endometrial hyperplasia in 12.2% and submucous myoma in 7.8%, Trotsenburg et al. (24) observed myomas and polyps in 14% and deLewit (23) reported myomas in 21% and polyps in 14.4%. Incidence of endometrial polyps has ranged from 9.1% in Hamous' (25) to 45.9% in Pasqualotto (26) series.

### Diagnostic Accuracy of Hysteroscopy

The sensitivity, specificity, PPV and NPV of Hysteroscopy to diagnose polyp was 90%, 100%, 100% and 97.6% respectively. All the case of fibroids were correctly diagnosed by hysteroscopy, thus sensitivity, specificity, PPV and NPV of Hysteroscopy were all 100%. The sensitivity, specificity, PPV and NPV of Hysteroscopy to diagnose endometrial hyperplasia was 85.7%, 90.7%, 60% and 97.5% respectively. The sensitivity, specificity, PPV and NPV of Hysteroscopy to diagnose endometrial carcinoma was 50%, 100%, 100% and 98% respectively.

The diagnostic accuracy of Hysteroscopy for endometrial polyp, submucous fibroid, endometrial hyperplasia and CA endometrium in cases of AUB is as follows:

Study	Parameter	Polyp	Fibroid	Hyperplasia	Carcinoma
Mukhopadhyay S et al. (27)	sensitivity	71.4%	100.0%	50.0%	50.0%
	specificity	100.0%	100.0%	95.8%	100.0%
Islam A et al(28)	sensitivity	100.0%	100.0%	100.0%	73.4%
	specificity	100.0%	100.0%	100.0%	100.0%
Chaudhari et al. (10)	sensitivity	94.0%	91.0%	92.0%	75.0%
	specificity	96.0%	95.0%	92.0%	98.0%
Chhikara et al. (12)	sensitivity	80.0%	100.0%	66.6%	
	specificity	97.5%	100.0%	90.2%	
Present Study	sensitivity	90.0%	100.0%	85.7%	50.0%
	specificity	100.0%	100.0%	90.7%	100.0%

We thus observed that, Hysteroscopy showed a high sensitivity and specificity for most of the cases of AUB. We thus conclude that Hysteroscopy can increase the accuracy of clinical diagnosis and may even serve as an adjunct in the treatment of patients with specific intrauterine pathological conditions.

### V. Conclusion

Hysteroscopy is a valuable tool for diagnosing endometrial inflammation, atrophic endometrium and focal lesions like endometrial polyps and submucosal fibroids. Although hysteroscopy is somewhat less reliable diagnostic modality for endometrial hyperplasia than other pathologies its diagnostic accuracy is still very high. We thus conclude that, since hysteroscopy can increase the accuracy of clinical diagnosis it should be a part of diagnostic workup in cases of AUB. In addition hysteroscopy may even serve as an adjunct in the treatment of patients with specific intrauterine pathological conditions.

### References

- [1]. Mencaglia L, Perino A, Hamou J. Hysteroscopy in premenopausal and postmenopausal women with abnormal uterine bleeding. *J Reprod Med* 1987;32:577-582.
- [2]. Bradlow J, Coulter A, Brooks P. Patterns of referral. A study of referrals to out-patient clinics from general practitioners in the Oxford region. Oxford: Oxford Health Services Research Unit, 1992.
- [3]. Munro MG, Critchley HO, Broder MS, Fraser IS. FIGO classification system (PALM-COHIEN) for causes of abnormal uterine bleeding in nongravid women of reproductive age. *Int J Gynecol Obstet*. 2011;113:3-13.
- [4]. Epstein E, Ramirez A, Skoog L, Valentin L. Dilatation and curettage fails to detect most lesions in the uterine cavity in women with postmenopausal bleeding. *Acta Obstet Gynecol* 2001; 12:1131-6.
- [5]. Grimes D. Diagnostic dilatation and curettage of reappraisal. *Am J Obstet Gynecol* 1982;47:300-6.
- [6]. Gimpelson RJ, Whalen TR. Hysteroscopy as gold standard for evaluation of abnormal uterine bleeding. *American journal of obstetrics and gynecology*. 1995 Nov 30;173(5):1637.
- [7]. Van Dongen H, De Kroon CD, Jacobi CE, Trimbos JB, Jansen FW. Diagnostic hysteroscopy in abnormal uterine bleeding: a systematic review and meta-analysis. *BJOG: An International Journal of Obstetrics & Gynaecology*. 2007 Jun 1;114(6):664-75.
- [8]. Manual of hysteroscopy diagnosis and surgery, Luca MENCAGLIA, Jacques E. HAMOU, 2010, page 29-30.
- [9]. Varadarajan R, Sreekantha SM. Role of hysteroscopy in abnormal uterine bleeding in perimenopausal age group. *Journal of Evolution of Medical and Dental Sciences*. 2013 Mar 11;2(10):1504-9.
- [10]. Chaudhari KR, Sathe P. Role of diagnostic hysteroscopy in evaluation of abnormal uterine bleeding and its histopathological correlation. *Int J Reprod Contracept Obstet Gynecol*. 2014;3:666-70.
- [11]. Goyal BK, Gaur I, Sharma S, Saha A, Das NK. Transvaginal sonography versus hysteroscopy in evaluation of abnormal uterine bleeding. *medical journal armed forces india*. 2015 Apr 30;71(2):120-5.
- [12]. Chhikara A, Bharti A. Role of Hysteroscopy in the Evaluation of Abnormal Uterine Bleeding. *Indian Journal of Applied Research*. 2016 Jul 18;6(6).
- [13]. Brill A. What is the role of hysteroscopy in the management of abnormal uterine bleeding? *Clinical Obstet Gynecol* 1995;38:319-45.

Role of Hysteroscopic Evaluation in Abnormal Uterine Bleeding and its histopathological co-relation.

- [14]. Panda A, Parulekar SV, Gupta A. diagnostic hysteroscopy in abnormal uterine bleeding and its histopathological correlation. J Obst Gyn India 1999; 175: 74-76
- [15]. Giannino A, Morana C, Campione C. Diagnostic hysteroscopy in abnormal uterine bleeding. Five year's experience. Minerva Ginecol 2003; 55: 57-61
- [16]. VanTrotsenburg M, Wieser F, Naegle F. Diagnostic hysteroscopy for the investigation of abnormal uterine bleeding in premenopausal patients. ContribGynecolObstet 2000; 20: 21-26
- [17]. Guin G, Sandhu SK, Lele A, Khare S. Hysteroscopy in evaluation of abnormal uterine bleeding. The Journal of Obstetrics and Gynecology of India. 2011 Oct 1;61(5):546-9.
- [18]. Sunitha CH. A clinical study of diagnostic hysteroscopy in abnormal uterine bleeding and its histopathological correlation. IOSR Journal of Dental and Medical Sciences (IOSR-JDMS). Volume 5, Issue 3 (Mar.- Apr. 2013), PP 43-46.
- [19]. Wamsteker K, Emanuel MH, de Kruif JH. Transcervical hysteroscopic resection of submucous fibroids for abnormal uterine bleeding: results regarding the degree of intramural extension. ObstetGynecol 1993;82(5):736-40.
- [20]. Loffer FD. Hysteroscopy with selective endometrial sampling compared with dilatation and curettage for abnormal uterine bleeding: The value of negative hysteroscopic view. ObstetGynecol 1989; 73: 16-20
- [21]. Sheth SS, Nerurkar NM, Mangeshkar PS. Hysteroscopy in abnormal uterine bleeding. J Obstet Gyn India 1990; 40: 451
- [22]. Neumann T, Astudillo J. Hysteroscopic study in patients with abnormal uterine bleeding. Rev ChilObstetGynecol 1994; 59: 349-52.
- [23]. deWit AC, Vleugels MP, deKruif JH. Diagnostic hysteroscopy: A valuable diagnostic tool in the diagnosis of structural intra-cavitary pathology and endometrial hyperplasia or carcinoma? Six year's of experience with non clinical diagnostic hysteroscopy. Eur J ObstetGynecolReprodBiol 2003; 110: 79-82
- [24]. VanTrotsenburg M, Wieser F, Naegle F. Diagnostic hysteroscopy for the investigation of abnormal uterine bleeding in premenopausal patients. ContribGynecolObstet 2000; 20: 21-26
- [25]. Heineberg A. Uterine endoscopy: an aid to precision in the diagnosis of intrauterine disease. SurgGynecolObstet 1914; 18: 513
- [26]. Rubin IC. Uterine endoscopy, endometroscopy with the aid of uterine insufflation. Am J ObstetGynecol 1925; 10: 313.
- [27]. Mukhopadhyay S, Bhattacharyya SK, Ganguly RP, Patra KK, Bhattacharya N, Barman SC J. Comparative evaluation of perimenopausal abnormal uterine bleeding by transvaginal sonography, hysteroscopy and endometrial biopsy. Indian Med Assoc. 2007 Nov;105(11):624, 626, 628 passim.
- [28]. Aliya Islam. Transvaginal sonography and AUB: A study from Ghazala Professional Military Hospital, Rawalpindi. Med J Jan - Mar 2009;16(1):127-34

Sabrina Mhapankar." Role of Hysteroscopic Evaluation in Abnormal Uterine Bleeding and its histopathological co-relation.. ." IOSR Journal of Dental and Medical Sciences (IOSR-JDMS), vol. 17, no. 9, 2018, pp 32-42.