

Outcomes after phacoemulsification surgery in eyes with white mature cataracts: Results from a Military Hospital in Western India

First author: Dr Ranjit Goenka
Corresponding Author: Dr B V Rao

Abstract

Background: The aim of this study was to assess the postoperative visual outcomes of phacoemulsification in patients with white mature cataract from a western Indian population who were operated in a military Hospital from Jan 2016 to Dec 2017.

Methods: The study comprised of 58 eyes with unilateral white mature cataract that underwent cataract surgery by phacoemulsification. A detailed preoperative assessment including visual acuity, slit lamp examination, intraocular pressure measurement, keratometry, biometry for axial length measurement and B-scan ultrasonography was done for all the patients. Patients had phacoemulsification through a 2.8 mm superotemporal clear corneal incision. Intraoperative and postoperative complications, prevalence of corneal decompensation and post operative visual outcome one month after surgeries were analyzed.

Results: A total of 58 eyes with unilateral white mature cataract were operated within the study period. The mean age of the 28 males (48.2%) and 30 females (51.7%) was 59.9 years (range 38-90 years). Continuous curvilinear capsulorhexis was achieved in 57 eyes (98.2%) and in the bag IOL was implanted in 57 eyes (98.2%). Zonular dialysis with nucleus drop occurred in one patient (1.7%). Post operatively thirty one eyes (53.44%) had central corneal edema on the first postoperative day. Epithelial and stromal edema resolved by 7 days in all the cases. At the end of 1 month, 52 eyes (89.2%) achieved a best corrected visual acuity (BCVA) of 6/9 to 6/6. Five eyes had a BCVA of 6/18 to 6/12. There was no case of corneal decompensation, endophthalmitis or toxic anterior segment syndrome in this study.

Conclusion: Our study shows that white mature cataracts can be safely removed with current phacoemulsification techniques with excellent post operative visual results.

Keywords: white mature cataract, trypan blue dye, viscoelastic devices, phacoemulsification

Date of Submission: 28-08-2018

Date of acceptance: 10-09-2018

I. Introduction

White, mature, senile cataracts (total opacification of nucleus and cortex of lens precluding visualisation of red reflex) represent one of the advanced forms of cataract disease. Although rare in developed countries, white mature cataracts constitutes a significant proportion of cataracts in developing countries like India. Removal of intumescent white cataract is one of the most challenging anterior segment surgeries because of unpredictable intraoperative course. A continuous curvilinear capsulorhexis (CCC) is a pre-requisite for safe phacoemulsification. This is the most difficult step in white mature cataracts because of the absence of retroillumination and increased Intracapsular pressure due to liquefied cortex.¹ In addition, nucleotomy poses unique challenges while sculpting, as judging the depth of trench in the absence of red glow is difficult and at times a mature white cataract may also have a hard or brunescient nucleus underlying liquefied cortex.² Conventionally Extra Capsular Cataract Extraction with Posterior Chamber Intraocular Lens Implantation (ECCE-PCIOL) has been the treatment of choice for managing all types of cataracts including white cataracts. However, it has its own problems related to wound suturing with its associated complications and late visual rehabilitation.³ Reports indicate Manual Small Incision Cataract Surgery (MSICS) to be effective alternative in white cataracts.⁴ Phacoemulsification has become the procedure of choice in the management of cataract and use of trypan blue dye for capsular staining, viscoelastic (OVD) devices for protection of corneal endothelium and ultrasound energy modulation have made phacoemulsification safer in white cataracts.⁵ Few studies have reported the results of phacoemulsification of these advanced cataracts.^{6,7} Moreover, there are very few studies on the efficacy and safety of phacoemulsification of such mature white cataracts in Indian scenario. The aim of this study was to assess the postoperative visual outcomes of phacoemulsification in patients with white mature cataract in Indian eyes.

II. Materials and methods

The study was approved by institutional ethics committee and all aspects of the Declaration of Helsinki were observed. The group of patients included patients undergoing cataract surgery at an army hospital. A total of 58 eyes with unilateral white mature cataracts that were operated using phacoemulsification technique in the period between Jan 2016 to Dec 2017 were included in the study. Inclusion criteria were patients with unilateral white mature cataract, normal intraocular pressure, good pupillary dilatation and a clear cornea. The mean age of the 28 males (48.2%) and 30 females (51.7%) was 59.9 years (range 38-90 years). Exclusion criteria were patients with lens induced uveitis, uncontrolled glaucoma, hypermature Morgagnian cataract, phacodonesis, complicated cataracts, poor pupillary dilatation and corneal pathologies or with a history of ocular trauma. Preoperative examination included visual acuity, detailed slit lamp examination and intraocular pressure (IOP) measurement. Cataract was graded as per LOCS classification.⁸ B-scan ultrasonography was performed in all patients to exclude posterior segment pathologies. Intraocular lens power was calculated by keratometry and A-scan biometry using SRK II formula.

III. Surgical technique

All procedures were done by either one of the two surgeons (RG, BVR with more than 10 years of experience doing phacoemulsification) randomly assigned for each case using one of the two advanced phacomachines available at the centre, under peribulbar anaesthesia (a mixture of lignocaine 1%, bupivacaine 0.75%, and hyaluronidase) and a superotemporal 2.8 mm clear corneal incision. A paracentesis was made at 10 o'clock position using a paracentesis knife for performing the continuous curvilinear capsulorhexis (CCC). Anterior capsule was stained with 0.06% trypan blue dye in all the cases after injecting an air bubble to protect the corneal endothelium. Capsulorhexis of 5-6 mm was made under high-viscosity sodium hyaluronate (1.4%) with 26 gauge cystitome needle. If necessary, more viscoelastic was injected to flatten the anterior capsule and control the capsulorhexis. If required, oozing liquefied cortex was aspirated with cystitome needle to maintain clarity of the anterior chamber and to decrease Intracapsular pressure. If the CCC margin extended to the periphery, Ultracapsulorhexis forceps was used to rescue the capsulorhexis. No hydroprocedures were done to hydrodissect or rotate the nucleus. A Sinskey hook was used to rotate the nucleus.

Both dispersive (chondroitin sulphate 4% with sodium hyaluronate 3%) and cohesive viscoelastic (sodium hyaluronate (1.4%)) were used in each patient to deepen the anterior chamber and protect the corneal endothelium. The phaco power (range 30%- 70%) was adjusted according to hardness of each cataract. Phacoemulsification (conventional longitudinal) was done using the stop and chop technique. The technique is suitable even in small capsulorhexis as all the phaco procedures can be done within the capsulorhexis margin. A deep trench was made in the central nucleus. Then a crack was created in the nucleus with phaco probe and a chopper and the nucleus was divided in two halves. The two halves of the nucleus were then divided into multiple small pieces for nucleus consumption. Total phaco time (in seconds) was recorded. Cortical cleanup and capsule polishing were performed if necessary. Note was made of presence of any plaque opacification on the central and peripheral posterior capsule. A hydrophilic or hydrophobic acrylic single piece intraocular lens (IOL) was implanted in the bag. A thorough viscoelastic removal was done and stromal hydration was performed by injecting fluid to the side of the paracentesis and main corneal incision. Intraoperative findings or complications were recorded. The standard post operative treatment included steroid antibiotic eye drops tapered over 04 weeks.

Examinations were done day 1, one week and at the end of 1 month postoperatively. At every visit, Uncorrected Visual Acuity (UCVA) and Best Corrected Visual Acuity (BCVA) were recorded using a Snellen's chart along with slit lamp biomicroscopy, fundus evaluation and intraocular pressure (IOP) measurement by Non contact method.

IV. Results

58 eyes with unilateral white mature cataract were enrolled in the study. The mean age of the 28 males (48.2%) and 30 females (51.7%) was 59.9 years (range 38-90 years). Preoperatively 40 eyes (68.9%) had best corrected visual acuity (BCVA) hand movement (HM) or perception of light (PL), 13 eyes (22.4 %) had counting finger close to face (CFCF) and 5 eyes (12.5%) between 3/60 - 4/60 (Fig1).

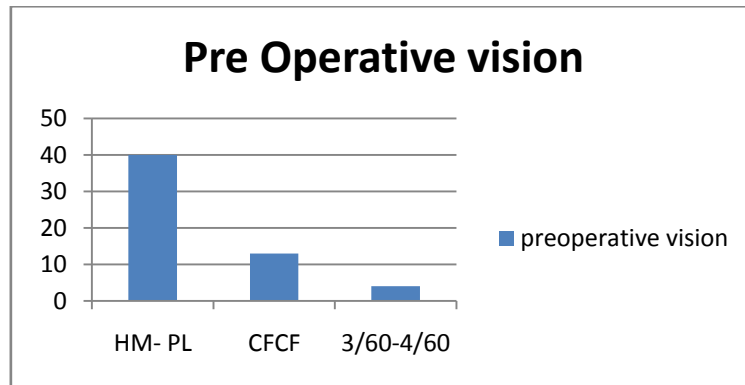


Figure 1

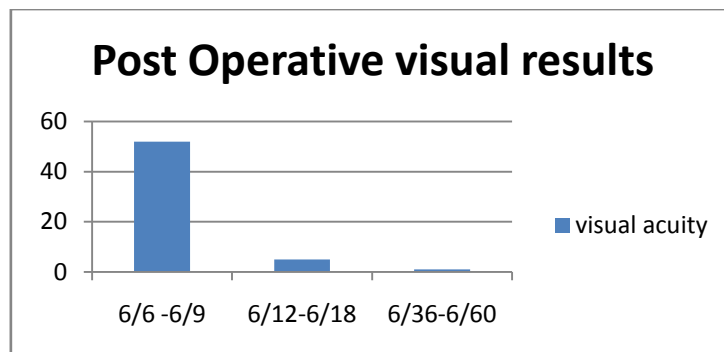


Figure 2

Mean axial length was 22.76 mm (range 21.05 -24.76 mm) and intraocular lens power ranged from 17D – 26.5 D. One eye had cataract with pseudoexfoliation without raised IOP. Continuous curvilinear capsulorhexis was achieved in 57 eyes (98.2%) and in the bag IOL was implanted in 57 eyes (98.2%). Intraoperatively, one eye (1.7) developed uncontrolled peripheral extension (Argentinean flag sign), anterior capsule tear during phacoemulsification without peripheral extension in two eyes (3.4%), and zonular dialysis with nucleus drop in one eye (1.7%). Patient with zonular dialysis was referred to Vitreo retinal surgeon for secondary surgery. He underwent vitrectomy and was implanted with a scleral fixated IOL.

Transient corneal edema was the most common post operative complication. Thirty one eyes (53.44%) had central corneal edema on the first postoperative day. Of these, twenty three eyes (74.1%) had mild to moderate central stromal edema and eight eyes (25.8%) had diffuse stromal edema. Epithelial and stromal edema resolved by 7 days in all the cases. Nine eyes (15.5%) had intra ocular pressure (IOP) greater than 22.0 mm Hg and required topical timolol 0.5% eye drops. There was no case of corneal decompensation, endophthalmitis or toxic anterior segment syndrome in this study.

At the end of 1 month, 52 eyes (89.2%) achieved a best corrected visual acuity (BCVA) of 6/9 to 6/6 (Fig2). The other five eyes had a BCVA of 6/18 to 6/12. This was attributed to presence of ARMD in two patients, cystoid macular edema in one patient and posterior capsule plaque in two patients.

V. Discussion:

White cataracts still occur and form a significant proportion of surgical load at our practice. Phacoemulsification has been shown to be safe technique in immature cataracts but there have not been many reports of phacoemulsification in white cataracts. Creating a continuous curvilinear capsulorhexis (CCC) and emulsification of nucleus is challenging in white cataracts. Absence of red reflex and liquefied cortex obscure the visualisation. Also, there is a possibility of raised Intracapsular pressure in intumescent cataracts leading to uncontrolled peripheral extension or radial tears of anterior capsule. Adjunctive use of trypan blue to stain the anterior capsule enhances the visualisation of capsule and makes CCC safer.⁹Gimbel described two stage capsulorhexis approach for intumescent white cataracts.¹⁰ Recently Femtosecond laser has been shown to be safe and effective modality for CCC in challenging cases.¹¹Findl et al used high-frequency diathermy to achieve CCC in white intumescent cataracts.¹² Intumescent lens fibres can increase the intralenticular pressure. This can be countered with high viscosity cohesive viscoelastic. One eye in our study had uncontrolled peripheral extension of the capsular tear leading to Argentinean flag sign. Two semicircular capsular flaps were created in this case with Vanna's scissors and Utrata's forceps and in the bag IOL was implanted in the end. Some white

cataracts have liquefied lens matter that immediately oozes out as the capsule is punctured. The milky fluid was repeatedly washed with viscoelastic to maintain clarity and deep anterior chamber. We achieved continuous curvilinear capsulorhexis in 57 eyes (98.2%). No case was converted to can-opener technique. Hydrodissection was not required in any case because the nuclei were mobile. Hydrodissection in white cataracts can also increase Intracapsular pressure because limited space and can result in posterior capsular tear.

Nucleus was emulsified with stop and chop technique in all the cases. Every effort was made to maintain deep anterior chamber with use of both dispersive and cohesive viscoelastic to protect the corneal endothelium. One case had nucleus drop during phacoemulsification because of zonular dialysis. The patient was sent to Vitreo retinal surgeon for secondary surgery. He underwent vitrectomy and was implanted with a scleral fixated IOL. No case required conversion to manual extraction.

Postoperatively transient corneal edema was observed in 31 eyes (53.4%) on first post operative day, as compared to less than 10% in immature cataracts at this centre. However, all of them resolved over next one week with medical therapy. This is because many of the cataracts were hard and were camouflaged by the opacified cortex. There was no case of permanent corneal endothelium damage in the study. Intraocular pressure was elevated on day one in nine eyes (15.5%) which required topical timolol 0.5% eye drops. Rise in IOP was most likely due to retained viscoelastic after the surgery. IOP returned to normal in all the patients by one week postoperatively.

Postoperatively at the end of 1 month, 52 eyes (89.2%) achieved a best corrected visual acuity (BCVA) of 6/6 to 6/9 (Fig2), which is similar to results obtained by Chakrabati et al.¹³ The other five eyes had a BCVA of 6/18 to 6/12. This was attributed to presence of ARMD in two patients, posterior capsule plaque in two patients and cystoid macular edema in one patient. Cystoid macular edema (CME) after uncomplicated cataract surgery is uncommon.¹⁴ In our study one patient (1.7%) developed CME and was treated with Intravitreal anti-VEGF injection.

In conclusion our study shows that with extreme patience, surgical experience and appropriate improvisations, a continuous curvilinear capsulorhexis and excellent post-operative visual results, comparable with phacoemulsification in immature cataracts, can be achieved in white cataracts operated with phacoemulsification. Meticulous preoperative assessment of cornea and lens, use of both dispersive and cohesive viscoelastics, newer phaco machines with better fluidics and use of proper phaco techniques can help to protect the corneal endothelium and make phacoemulsification safer in white mature cataracts.

References

- [1]. Vasavada A, Singh R, Desai J. Phacoemulsification of white mature cataracts. *J Cataract Refract Surg* 1998; 24:270-7.
- [2]. Brazitikos PD, Tsinoopoulos IT, Papadopoulos NT, Fotiadis K, Stangos NT. Ultrasonographic classification and phacoemulsification of white senile cataracts. *Ophthalmology*. 1999 Nov; 106(11):2178-83.
- [3]. Dada VK, Sindhu N. Management of cataract-A revolutionary change that occurred during last two decades. *J Indian Med Association*. 1999; 97:313-7.
- [4]. Venkatesh R, Das M, Prashanth S, Muralikrishnan R. Manual small incision cataract surgery in eyes with white cataracts. *Indian Journal of Ophthalmology*. 2005 July 1, 2005;53(3):173-6.
- [5]. Brusini P. Capsulorhexis in mature cataracts: why not? *Documenta ophthalmologica Advances in ophthalmology*. 1992; 81(3):281-4.
- [6]. Mansour AM. Anterior capsulorhexis in hypermature cataracts. *Journal of cataract and refractive surgery*. 1993 Jan; 19(1):116-7.
- [7]. Ermiss SS, Ozturk F, Inan UU. Comparing the efficacy and safety of phacoemulsification in white mature and other types of senile cataracts. *The British journal of ophthalmology*. 2003 Nov; 87(11):1356-9.
- [8]. Chylack LT, Jr., Wolfe JK, Singer DM, Leske MC, Bullimore MA, Bailey IL, et al. The Lens Opacities Classification System III. The Longitudinal Study of Cataract Study Group. *Archives of ophthalmology (Chicago, Ill: 1960)*. 1993 Jun; 111(6):831-6.
- [9]. Jacob S, Agarwal A, Agarwal A, Agarwal S, Chowdhary S, Chowdhary R, et al. Trypan blue as an adjunct for safe phacoemulsification in eyes with white cataract. *Journal of cataract and refractive surgery*. 2002 Oct; 28(10):1819-25.
- [10]. Gimbel HV, Willerscheidt AB. What to do with limited view: the intumescent cataract. *Journal of cataract and refractive surgery*. 1993 Sep; 19(5):657-61.
- [11]. Conrad-Hengerer I, Hengerer FH, Joachim SC, Schultz T, Dick HB. Femtosecond laser-assisted cataract surgery in intumescent white cataracts. *Journal of cataract and refractive surgery*. 2014 Jan; 40(1):44-50.
- [12]. Findl O, Amon M. Anterior capsulotomy created by radiofrequency endodathermy and continuous curvilinear posterior capsulorhexis in a patient with intumescent cataract and primary capsular fibrosis. *Journal of cataract and refractive surgery*. 1998 Jun; 24(6):870-1.
- [13]. Phacoemulsification in eyes with white cataract. Chakrabarti A,*(1) singh S, krishnadas R. *J cataract refract surg* 2000; 26:1041-1047. *American journal of ophthalmology*. 2000 Dec; 130(6):864-5.
- [14]. Menten J, Erakgun T, Afrashi F, Kerci G. Incidence of cystoid macular edema after uncomplicated phacoemulsification. *Ophthalmologica Journal international d'ophtalmologie International journal of ophthalmology Zeitschrift fur Augenheilkunde*. 2003 Nov-Dec; 217(6):408-12.

XXXXX."Outcomes after phacoemulsification surgery in eyes with white mature cataracts: Results from a Military Hospital in Western India."IOSR Journal of Dental and Medical Sciences (IOSR-JDMS), vol. 17, no. 9, 2018, pp 46-49.