

Study of Outcomes of Idiopathic Macular Holes Surgery with Sf6 Gas and Role of Oct.

¹Dr. Nagendra Shekhawat Professor, ²Dr. Rajesh Kumar Saini Assistant Professor

¹Vitreous Retinal Services, Department of Ophthalmology, S.M.S. Medical College & Hospital Jaipur (Rajasthan), India

² Vitreous Retinal Services, Department of Ophthalmology, J. L. N. Medical College & Hospital Ajmer (Rajasthan), India

Corresponding Author: Dr. Rajesh Kumar Saini Assistant Professor

Abstract:

Purpose: Outcomes of idiopathic macular holes surgery with SF6 gas and role of OCT.

Methods : Prospective pre-post operative hospital based case series of 26 eyes of 26 patients with stage 2,3 and 4 macular holes that underwent pars plana vitrectomy, BBG-assisted internal limiting membrane (ILM) peel, sulfur hexafluoride (SF6) gas tamponade and 2 days face-down positioning.

Results: : The anatomical closure rate was 84.61% (22 of 26 eyes) and Visual improvement at 6 weeks 0.152 ± 0.078 (SD) decimal from preoperative BCVA 0.109 ± 0.042 (SD) decimal was found to be significant ($p=0.001$) ; OCT enabled 53.85% (14 of 26 eyes) macular hole closure on second postoperative day with a single operation.

Conclusions: Short-acting gas tamponade in macular hole surgery allows rapid visual rehabilitation. OCT is a very useful investigating tool in predicting and explaining the outcomes after macular hole surgery.

Key words: Macular hole (MH), ILM, SF6 gas, OCT (Optical coherence tomography)

Date of Submission: 19-09-2019

Date of Acceptance: 07-10-2019

I. Introduction

A full thickness macular hole (FTMH) is defined as a defect of all layers of retinal tissue, from the internal limiting membrane (ILM) through segments of the photoreceptor layer, involving the anatomic fovea.¹

Idiopathic macular holes are related to aging and usually occur in people over age of 60 years.^{2,3} Gass classified senile full thickness macular holes and their precursor lesions based on their biomicroscopic and histopathologic analysis⁴.

I Impending hole – Tractional shallow detachment of fovea

Ia – Yellow spot at fovea

Ib – Yellow halo at fovea

II FTMH noted clinically with defect $<400\mu\text{m}$ in diameter

III FTMH $>400\mu\text{m}$ in diameter with surrounding cuff of fluid with or without pseudo-operculum

IV FTMH with further development of a complete PVD with anterior displacement of pseudo-operculum

Vitreous surgery for full thickness macular hole was first initiated by Kelly and Wendel (1991).^{5,6} Since then the techniques of surgery have passed through numerous modification and excellent anatomical (98%) and functional (96%) results are obtained.⁷

Conventional surgery involves pars plana vitrectomy and ILM peeling which would eliminate the forces of secondary vitreoretinal traction. Replacement of intraocular volume with internal gas tamponade provides a smooth template for glial cell migration which would optimize reapproximation of the edges of the macular hole.⁸

Most studies indicate that better anatomical and functional outcomes can be achieved after peeling.⁷⁻¹⁵ Furthermore, ILM peeling may prevent reopening of the macular hole.¹³

To maximize the effects of the gas, a long-acting gas and a long duration of face-down positioning have been used. However, this practice is not easily tolerated by elderly patients and patients with poor cardiopulmonary function. Patients may become distressed and avoid surgery if advised to maintain a face-down position for more than a week postoperatively. Many study shows that macular hole surgery with sulfur

hexafluoride (SF₆) gas achieves similar or higher results to perfluoropropane (C₃F₈), perfluoroethane (C₂F₆), and air is absorbed faster than C₃F₈, allowing quicker visual rehabilitation for the patient.¹⁶⁻²⁰

OCT enabled confirmation of more than half of MH closure (62.5%) the day after surgery even in gas-filled eyes. This imaging method may be a good indicator to determine when to stop posturing for each patient.^{21,22}

Using a tamponade with short-acting gas, only strict postoperative positioning ensures the contact of the gas bubble with foveal tissue and gains significance with reducing bubble size.

The indication of face-down positioning may be important when a short-lasting tamponade is chosen in macular hole surgery.

In the present study, an effort was made to detection of idiopathic macular hole closure with OCT machine, with the use of SF₆, a short-acting gas tamponade, and a short period of 2 days face-down positioning.

II. Materials & Methods

This was a prospective pre-post operativehospital based case series study done at Upgraded Department of Ophthalmology, SMS Medical College, Jaipur. 26 eyes of 26 patients were recruited in the study.

Inclusion criteria:

- Idiopathic macular hole stage 2-4
- Visual acuity < 6/18

Exclusion criteria:

- All type of macular hole caused other than idiopathic origin

Statistical analysis-Qualitative data was summarized in the form of proportion. Quantitative data was summarized in the form of mean and standard deviation. The difference in pre and postoperative mean value was analyzed using paired t test. The level of significance for all statistical analysis was kept 95%.

Ophthalmological examination included best corrected visual acuity (BCVA), slit lamp biomicroscopy, indirect ophthalmoscopy, optical coherence tomography(OCT, TOPCON). Surgical procedure included 23 G pars plana vitrectomy, Brilliant Blue-G satined ILM peeling, 20% SF₆ gas tamponade and postoperatively face-down positioning for 2 days.

III. Results

- In our study the mean age was 60.42±7.30 years. There were 15 female (57.7%) and 11 male (42.3%)
- The anatomical closure rate was 84.61% and; OCT enabled 53.85% macular hole closure on second postoperative day.

Figure 1: OCT picture of a case of full thickness macular hole

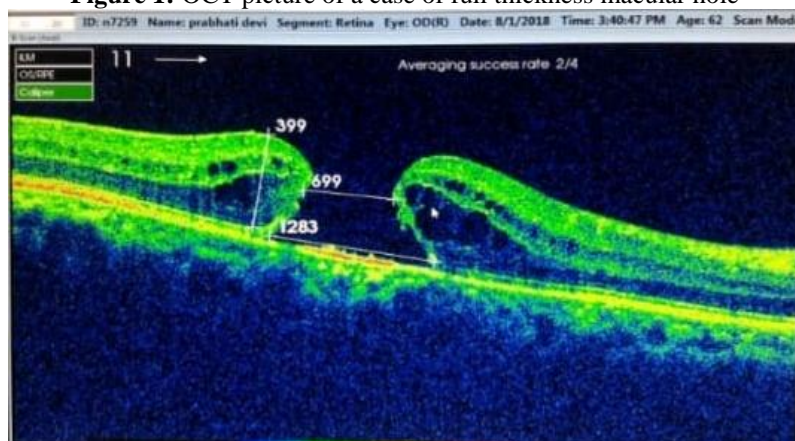


Figure 2: OCT picture of same patient showing closure of macular hole

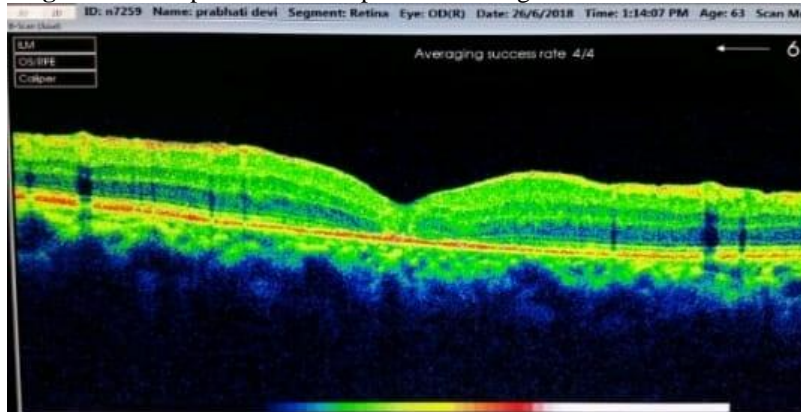
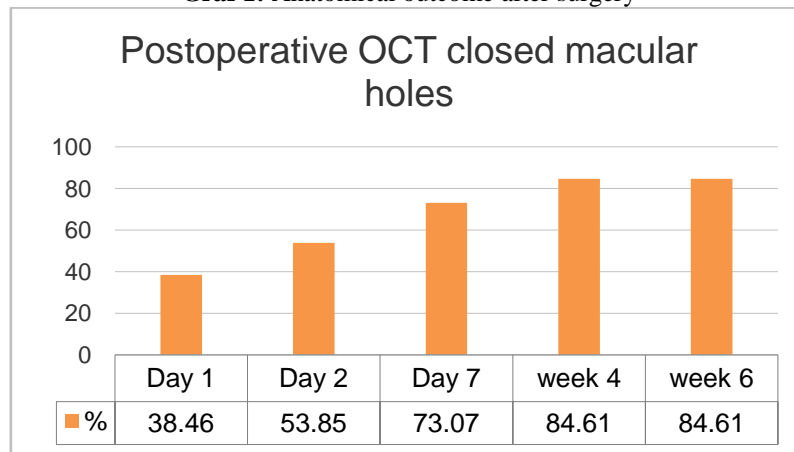


Table 1: Macular hole closure on OCT

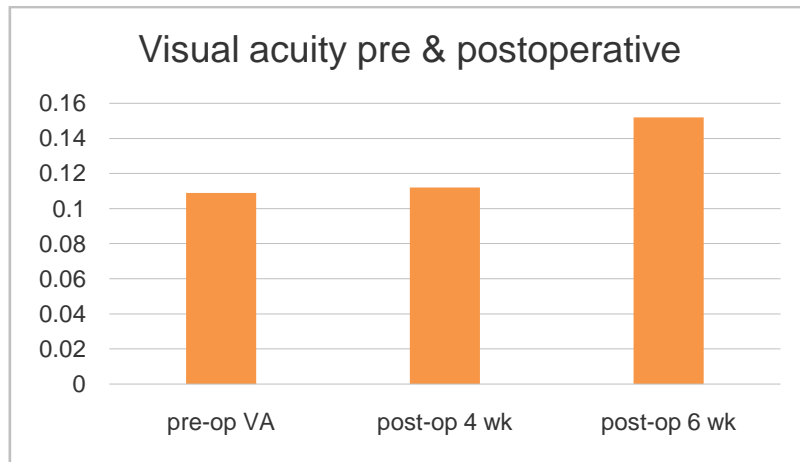
OCT	No.	%
Postoperative		
Day 1	10	38.46
Day 2	14	53.85
Day 7	19	73.07
Week 4	22	84.61
Week 6	22	84.61

Graf 1: Anatomical outcome after surgery



Out of 26 patients 10 patients had hole closure on day 1st, 14 on day 2nd, 19 on day 7th, and 22 on week 4th and 6th. Four patients reported non-closure of hole and hence surgical failure. **So in 73% patients MH was found closed within 7 days after surgery.**

- **Best corrected visual acuity (BCVA)** was determined by Snellens acuity chart and was converted to Decimal values.
 - Changes in BCVA from preoperative 0.109±0.042 (SD) decimal to 4 week BCVA 0.11±0.042 (SD) decimal postoperative were not found to be significant (p=0.688)
 - Improvement in BCVA 0.152±0.078(SD) decimal at 6 week postoperative was found to be significant (p=0.001)



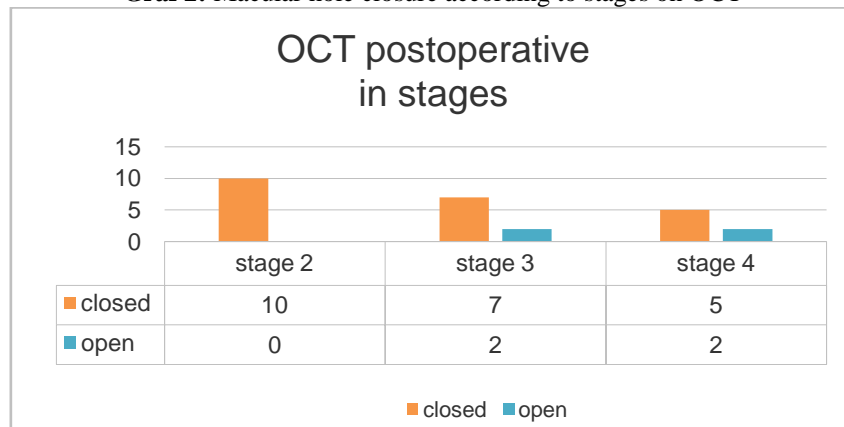
Anatomical closure according to stages

Hole size < 400 μm diameter hole (stage 2) shows 100% closure whereas > 400μm (stage 3 and 4) 75% closure; but this difference was not significant (p=0.2148)

Table 2: Macular hole closure according to stages on OCT

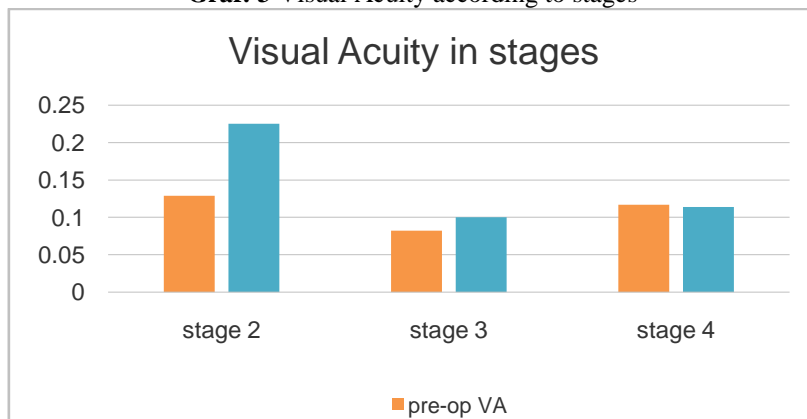
OCT	stage 2	stage 3	stage 4	P value
closed	10	7	5	0.2148
open	0	2	2	
total	10	9	7	

Graf 2: Macular hole closure according to stages on OCT



Mean BCVA at 6 weeks in stage 2 was (0.225±0.055) higher than stage 3 (0.100±0.029) and stage 4 (0.114±0.074); and it was statistically significant (p=0.000)

Graf: 3 Visual Acuity according to stages



- Preoperative mean IOP was 16.15±3.355 mmHg and at 6 weeks was 16.04 ±3.206 mmHg. This change was not statistically significant (p=0.791)

IV. Discussion

The mean age of patients was 61.42 ± 7.30 years. Out of these 15 (57.7%) patients were female and 11 (42.3%) were male. Diagnosed idiopathic macular hole is more prevalent in middle aged women, the similar finding were seen in our study and supported by one study (1994)² Evans JR et al(1998).³

Following macular hole surgery, the overall anatomical closure rate was 84.61%; These findings in accordance with Kelly and Wendell et al (1993)⁶73% closure rate and Kwok et al (2003)¹¹ 90% closure rate whereas Da Mata AP et al (2004)⁷ 98% closure, Kim et al (2008)¹⁶ 90% closure rate, Christensen UC et al (2009)¹⁴ 95% closure rate for stage 2 and 3, this difference was probably because of small sample size and or preoperative differences in stages of macular hole.

The improvement in visual acuity at 6 weeks was found to be statistically significant p= 0.001. These findings are consistent with Kelly and Wendell (1993),⁶Da Mata AP et al (2004)⁷, Kwok et al (2003)¹¹, Christensen UC et al (2009)¹⁴ all of them have reported significant improvement in visual acuity postoperatively.

Even after successful hole closure, visual acuity does not return to normal. This can be better explained to some extent by OCT as type of macular hole, its pathology, disruptions to the retinal pigment epithelium, photoreceptor IS/OS status, choriocapillary complex and Ellipsoid zone external limiting membrane.²³⁻²⁵

According to hole size, hole with < 400 µm diameter hole (stage 2) shows 100% closure whereas > 400µm (stage 3 and 4) 75% closure. Also, better BCVA was noticed in small diameter hole and it was statistically significant. BCVA in stage 2 was higher than stage 3 and stage 4 with statistically significant. These findings are consistent with the finding of Michael S. Ip et al (2002)²⁶ reported 92% closure with preoperative macular hole diameter < 400 µm whereas only 56% closure with hole diameter > 400µm.

In our study OCT enabled 53.85% (14/26) macular hole closure on second postoperative day. These findings are somewhat inferior to Masuyama et al (2009)²¹ who reported 62.5% MH closure the day after surgery and Niladri saha et al (2011)²² concluded that macular holes can close within 24 hours postoperatively. This difference may be due to gas-tissue interface, small sample size and /or preoperative differences in stages of macular hole.

In our study two patients developed rise in intraocular pressure and were managed medically whereas four patients developed cataract.

V. Conclusion

The following conclusion can be drawn from the present study;

- Short-acting gas tamponade allows macular holes to be closed with a high success rate, short duration of visual impairment and rapid postoperative rehabilitation.
- More than half of macular holes close after second postoperative day.
- Even after successful hole closure, visual acuity does not return to normal. OCT also may help in explaining to some extent in the poor visual gain even after surgical success ie; Macular bed changes with duration (RPE-Choriocapillaris complex and ellipsoid zone), External limiting membrane changes, IS/OS junction etc.
- OCT is a very useful investigating tool, in predicting the outcomes after macular hole surgery.

References

- [1]. Ho AC, Guyer DR, Fine SL: Macular hole. *SurvOphthalmol*. 1998 Mar-Apr;42(5):393-416. Review.
- [2]. The Eye Disease Case-Control Study Group. Risk factors for idiopathic macular holes. *Am J Ophthalmol* 1994;118:754-61.
- [3]. Evans JR1, Schwartz SD, McHugh JD, Thamby-Rajah Y, Hodgson SA, Wormald RP, Gregor ZJ. Systemic risk factors for idiopathic macular holes: a case-control study. *Eye (Lond)*. 1998;12 (Pt 2):256-9
- [4]. Gass JD: Reappraisal of biomicroscopic classification of stages of development of a macular hole. *Am J Ophthalmol* 119:752-759, 1995.
- [5]. Kelly NE, Wendel RT : Vitreous surgery for idiopathic macular holes : Results of a pilot study. *Arch Ophthalmol* 109:654-659, 1991.
- [6]. Kelly NE, Wendel RT : Vitreous surgery for macular holes. *Ophthalmology* 1993; 100:1671-1676
- [7]. Da Mata AP, Burk SE, Foster RE, et al: Long term followup of ICG assisted ILM peeling during vitrectomy surgery for idiopathic macular hole repair. *Ophthalmology* 111(12): 2246-2253, 2004
- [8]. Jonson RN, Gass JD. Idiopathic macular holes: Observation, stages of formation and implications for surgical intervention. *Ophthalmology* 1988; 95:917-924.
- [9]. Da Mata AP, Burk SE, et al: ICG assisted peeling of the retinal ILM during vitrectomy surgery for macular hole repair. *Ophthalmology* 108(7): 1187-1192, 2001.
- [10]. Uemoto R1, Yamamoto S, Aoki T, Tsukahara I, Yamamoto T, Takeuchi S. Macular configuration determined by optical coherence tomography after idiopathic macular hole surgery with or without internal limiting membrane peeling. *Br J Ophthalmol*. 2002 Nov;86(11):1240-2

- [11]. A K H Kwok, T Y Y Lai, W Man-Chan, and D C F Woo. Indocyanine green assisted retinal internal limiting membrane removal in stage 3 or 4 macular hole surgery. *Br J Ophthalmol.* 2003 Jan; 87(1): 71–74.
- [12]. R Tadayoni, A Gaudric, B Haouchine, and P Massin Relationship between macular hole size and the potential benefit of internal limiting membrane peeling *Br J Ophthalmol.* 2006 Oct; 90(10): 1239–1241.
- [13]. John T. Thompson, MD THE EFFECT OF INTERNAL LIMITING MEMBRANE REMOVAL AND INDOCYANINE GREEN ON THE SUCCESS OF MACULAR HOLE SURGERY. *Trans Am Ophthalmol Soc.* Dec 2007; 105: 198–206.
- [14]. Christensen UC. Value of internal limiting membrane peeling in surgery for idiopathic macular hole and the correlation between function and retinal morphology. *Acta Ophthalmol.* 2009;87 Thesis 2:1–23.
- [15]. Spiteri Cornish K1, Lois N, Scott N, Burr J, Cook J, Boachie C, Tadayoni R, la Cour M, Christensen U, Kwok A. Vitrectomy with internal limiting membrane (ILM) peeling versus vitrectomy with no peeling for idiopathic full-thickness macular hole (FTMH). *Ophthalmology.* 2014 Mar;121(3):649-55
- [16]. Kim SS, Smiddy WE, Feuer WJ, Shi W. Outcomes of sulfur hexafluoride (SF6) versus perfluoropropane (C3F8) gas tamponade for macular hole surgery. *Retina.* 2008;28(10):1408–1415
- [17]. Eckardt C, Eckert T, Eckardt U, Porkert U, Gesser C. Macular hole surgery with air tamponade and optical coherence tomography-based duration of face-down positioning. *Retina.* 2008;28(8):1087–1096.
- [18]. Gesser C, Eckert T, Eckardt U, Porkert U, Eckardt C. Macular hole surgery with air tamponade. Does air suffice for short-term tamponade? *Ophthalmologie.* 2010;107(11):1043–1050. German.
- [19]. Dhawahir-Scala FE, Maino A, Saha K, Mokashi AA, McLauchlan R, Charles S. To posture or not to posture after macular hole surgery. *Retina.* 2008;28(1):60–65.
- [20]. Rubina Rahman, Indira Madgula, Kamron Khan Outcomes of sulfur hexafluoride (SF6) versus perfluoroethane (C2F6) gas tamponade for non-posturing macular-hole surgery *Br J Ophthalmol* 2012;96:185-188
- [21]. Masuyama K1, Yamakiri K, Arimura N, Sonoda Y, Doi N, Sakamoto T Posturing time after macular hole surgery modified by optical coherence tomography images: a pilot study. *Am J Ophthalmol.* 2009 Mar;147(3):481-488.
- [22]. Niladri Saha, Stewart Lake, and Bob Z Wang. Early imaging of a macular hole following vitrectomy with primary silicone oil tamponade. *Clin Ophthalmol.* 2011; 5: 1637–1638.
- [23]. Michalewska Z, Michalewski J, Cisiecki S, et al. Correlation between foveal structure and visual outcome following macular hole surgery: a spectral optical coherence tomography study. *Graefes Arch Clin Exp Ophthalmol* 2008;246:823–30.
- [24]. Kao TY, Yang CM, Yeh PT, et al. The value of combining autofluorescence and optical coherence tomography in predicting the visual prognosis of sealed macular holes. *Am J Ophthalmol* 2013;156:149–56.
- [25]. Oh J, Smiddy WE, Flynn HW Jr. et al. Photoreceptor inner/outer segment defect imaging by spectral domain OCT and visual prognosis after macular hole surgery. *Invest Ophthalmol Vis Sci* 2010;51:1651–8

Dr. Rajesh Kumar Saini. “Study of Outcomes of Idiopathic Macular Holes Surgery with Sf6 Gas and Role of Oct.” *IOSR Journal of Dental and Medical Sciences (IOSR-JDMS)*, vol. 18, no. 10, 2019, pp 16-21.