

Periodontal Assessment of Orthodontic Patient Using CBCT

Naaz Amrin¹, Sanjeev Kumar Verma²

¹(Post-graduate, Department of orthodontics and dentofacial orthopedics. Ziauddin Ahmad Dental College, AMU, Aligarh (U.P)

²(Professor in Department of orthodontics and dentofacial orthopedics. Ziauddin Ahmad Dental College, AMU, Aligarh (U.P)

Corresponding Author: Naaz Amrin

Abstract: CBCT has emerged as a boon in the field of dentistry. Cone beam CT provides detailed images of the bone and is performed to evaluate diseases of the jaw, dentition, bony structures of the face, nasal cavity and sinuses. The X-ray parameters of CBCT is comparable to that of panoramic radiography with a usual operating range of 1-15 mA at 90-120 kVp. The CBCT provides following display modes apart from basic orthogonal views like Oblique slicing, Curved slicing, Cross-sectional (oblique coronal) view, Ray sum, Volume rendering. These all are used in various aspects of dentistry. One of the important of which is the assessment of periodontal condition of teeth before starting orthodontic therapy. CBCT has emerged as a new technology to provide precise evaluation of periodontium which can further help to take necessary steps for managing the periodontal problem as per need.

Date of Submission: 13-11-2019

Date of Acceptance: 27-11-2019

I. Introduction

In the last few decades, diagnostic imaging has been refined more and more using advanced technologies. Various limitation of conventional X-ray methods has been found out of which few are-

- It is impossible to display within the framework of a two dimensional X-ray picture all the information contained in the three-dimensional scene under view.
- Conventional X-rays cannot distinguish between soft tissues. It cannot display variation in soft tissue structures.
- It is not possible to measure in quantitative way the separate densities of individual substance through which X-ray has passed. The radiogram records mean absorption by all the various tissue which the X-ray has penetrated. This is of little use for quantitative measurement.¹
- CBCT is one of the advance technology to meet the demand of three dimensional imaging². In 1972 G.N. Hounsfield, introduced computerized transverse axial scanning which later on lead to development of Computed Tomography. Later on Arai et al in Japan and Mozzo et al in Italy worked independently and introduced Cone Beam Computed Tomography. The CBCT is an imaging acquisition technique that utilizes a volumetric scanning machine.

CBCT uses a cone shaped beam and a reciprocating solid state flat panel detector which rotates 180-360 degrees, covering the desired anatomic field, producing a 3-D image³. First a series of 2D images are constructed. The software then reconstructs the image into three dimensional (3D) data set using a specialized algorithm. CBCT system capture data in a cone-shapes pattern, and scans entire area in single rotation in approximately 8.9 seconds and image is reconstructed in <30 seconds. To the recent data, 43 CBCT systems are commercially available from 20 different companies⁴.

CBCT has a wide range of use in dentistry involving implantology, oral and maxillofacial surgical cases, orthodontic diagnosis and treatment plan and periodontology ,etc².

Orthodontic treatment of adults is always associated with primary and secondary dento-maxillary malocclusions along with various disease of the stomatognathic system. It often requires an interdisciplinary collaboration between various branches of dentistry.

One of the best example of multidisciplinary approach is treatment based on ortho-perio interaction.



Fig.1-CBCT setup

II. Periodontal Consideration In Orthodontic Treatment

It is an assumption that healthy periodontium is a must in patients undergoing orthodontic treatment⁵. It is a fact that sound periodontal health presents a better prognosis for orthodontic treatment. But, this does not imply that we should deny orthodontic treatment in periodontally compromised patient.

So, need for an integrated approach in such patient is important. A proper periodontal health evaluation is necessary to assess periodontal health before starting the orthodontic treatment, so that proper periodontal care steps can be taken before, during and after orthodontic treatment⁶.

Regenerative orthodontics is a new approach in patient who underwent periodontal treatment. It can be considered as a part of periodontal therapy. It involves modeling and regeneration of lost periodontium using guided orthodontic mechanics. It is based on the principle that orthodontically induced movement can modify periodontal morphology⁷. It allows 3D remodeling of defects resulting in reduced severity of periodontal defects.

Periodontal evaluation before starting any orthodontic treatment is necessary in order to prevent any periodontal disease later on during or after orthodontic treatment. Various parameters are checked, some of which can be evaluated using CBCT.

These parameters are-

- Clinical Attachment level
- Periodontal ligament space
- Soft tissue Dentogingival measurement
- Alveolar Bone defect
- Bone density

Various modalities are used to evaluate these parameters. CBCT is one of the recent advances in dentistry which is used to assess some of these parameters.

III. Soft tissue Dentogingival measurement

SOFT TISSUE CBCT (ST CBCT) is used to determine the dimension and relationship of dentogingival unit⁸. Thickness of buccal and palatal mucosa can be evaluated using this. This is then used to evaluate labial and palatal root prominence of teeth.

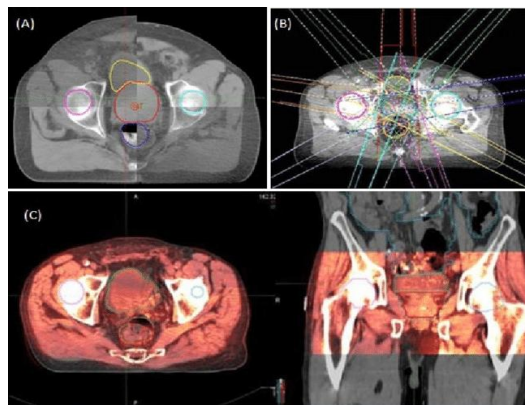


Fig.2 Soft tissue CBCT

IV. Periodontal ligament space

One of the earliest radiographical sign of periodontal disease is break in the continuity of lamina dura and fuzziness around it⁹. CBCT easily recognizes these sign in earliest stage, so that proper care can be taken before initiating orthodontic therapy. CBCT can also clearly show the space around teeth, Which can be then used to evaluate theankylosed teeth.

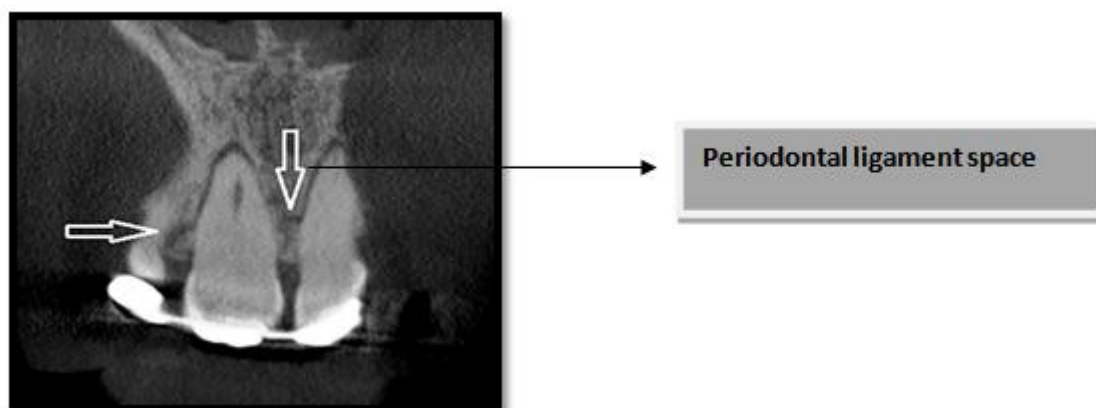


Fig.3. Assessment of periodontal ligament space

V. Alveolar bone defect

Two dimensional radiographs is insufficient for assessing the three dimensional intrabony defect¹⁰. CBCT scan provide a better diagnostic and quantitative analysis of intrabony defect, so that the amount of bone loss can be calculated. Proper pre orthodontic periodontal surgical therapy can then be given, after which orthodontic force delivery will be started.

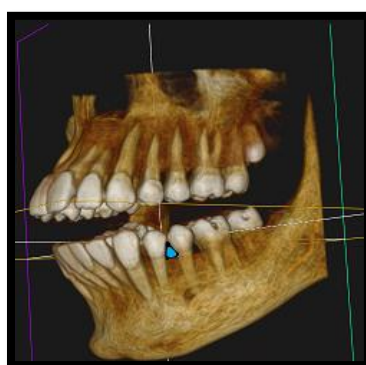


Fig.4-CBCT section showing bone defect.

VI. Assessment of result of periodontal regenerative therapy

It has been found that CBCT provides a accurate measurement of bone level changes after periodontal surgery¹¹. Evaluation of result of periodontal surgery is very precise using CBCT. In patient with intrabony defects, CBCT scan after surgical therapy is useful for assessment of bone level, after which orthodontic therapy can be started.

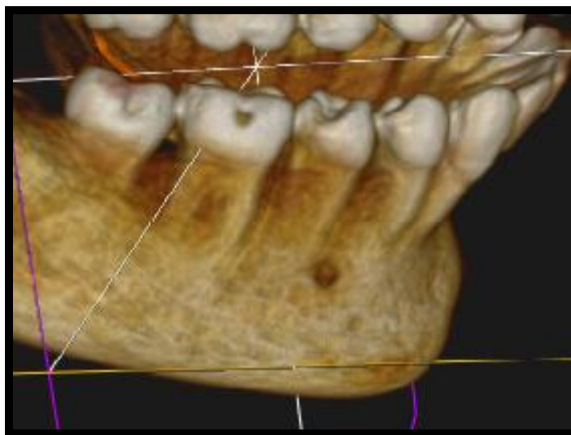


Fig. 5-CBCT section evaluation after surgery.

VII. Assesment Of Result Of Regenerative Orthodontics

Patients treated with intrabony defect using regenerative orthodontic mechanics is evaluated at the starting of treatment. The same patient is evaluated using CBCT towards the end of orthodontic treatment. This is useful for evaluating the efficacy of regenerative orthodontic.

VIII. Limitation Of CBCT

Although CBCT has provided us with a lots of advantage, there are several limitation associated with it, some of which are listed below.

- Quite high radiation dose is always associated with it .So, using CBCT for every problem is not indicated.
- Rapid incorporation of CBCT in general practice is the lack of standardization for both CBCT hardware and software

IX. Conclusion

Periontal assessment before starting a orthodontic case is necessary for getting optimal result after orthodontic treatment. Periodontal assessment is now a days very accurate and precise due to recent advances, which include CBCT. It offers essential information regarding soft tissue, bone level, extent of bone defect, result of periodontal surgery and many other important information.

References

- [1]. Kharbanda, 2nd edition
- [2]. Cone beam computed tomography: basics and applications in dentistry **ElluruVenkatesh and SnehalVenkateshElluru J IstanbUnivFac Dent. 2017; 51(3 Suppl 1): S102–S121. Published online 2017 Dec 2. doi: 10.17096/jiufd.00289Tyndall DA, Rathore S. Cone-beam CT diagnostic applications: Caries, periodontal bone assessment, and endodontic applications. Dent Clin North Am 2008;52:825-41.**
- [3]. THE 3D orthodontist: the modern orthodontist's source for information of 3D technologies. LakeTapps, W A, Aaron Molen, Web master. Available from: <http://www.3DOrthodontist.com/> . Accessed December 16, 2009.
- [4]. Ortho-perio integrated approach in periodontally compromised patients :CS Ramachandra, Pradeep Chandra Shetty, SanyuktaRege, Chitrang Shah:Journal of Indian Society of Periodontology, Vol. 15, No. 4, October-December, 2011
- [5]. CBCT imaging – A boon to orthodontics Genevive L. Machado. Saudi Dent J. 2015 Jan; 27(1): 12–21.
- [6]. "Periodontal Diseases" The Lancet. Cardaropoli D, Gaveglio L. The influence of orthodontic movement on periodontal tissues level. SeminOrthod. 2007;13(4):234–245.
- [7]. Januário AL, Barriviera M, Duarte WR. Soft tissue cone-beam computed tomography: A novel method for the measurement of gingival tissue and the dimensions of the dentogingival unit. J EsthetRestor Dent 2008;20:366-73.
- [8]. CBCT: A guide to a periodontologist : Tarun Kumar, GaganPuri, KonidenaAravinda, SanjeevLaller, Mamta Malik, Tajinder Bansal :SRM journal of research in Dental Sciences : Year : 2015 | Volume : 6 | Issue : 1
- [9]. Mengel R, Candir M, Shiratori K, Flores-de-Jacoby L. Digital volume tomography in the diagnosis of periodontal defects: An in vitro study on native pig and human mandibles. J Periodontol 2005;76:665-73.

- [10]. Application of Cbct in Periodontics 1Melissa L Pereira, 2Nagarathna D. V: IOSR Journal of Dental and Medical Sciences (IOSR-JDMS) e-ISSN: 2279-0853, p-ISSN: 2279-0861. Volume 16, Issue 6 Ver. IX (June. 2017)
- [11]. Farman AG, Scarfe WC. What is Cone-Beam CT and how does it work? *Dent Clin North Am* 2008;52:707-30.
- [12]. Ito K, Yoshinuma N, Goke E, Arai Y, Shinoda K. Clinical application of a new compact computed tomography system for evaluating the outcome of regenerative therapy: A case report. *J Periodontol* 2001;72:696-702.
- [13]. Papapanou PN, Tonetti MS. Diagnosis and epidemiology periodontal osseous lesions. *Periodontol* 2000. 2000;22(1):8–21.
- [14]. Ozmeric N, Kostiuotchenko I, Hägler G, Frentzen M, Jervøe-Storm PM. Cone-beam computed tomography in assessment of periodontal ligament space: In vitro study on artificial tooth model. *Clin Oral Investig* 2008;12:233-9.
- [15]. Maria GiacintaPaolone, Roberto Kaitsas. Guided orthodontic Regeneration :A new approach in ortho-periodontal regenerative treatment .*EJCO* 2016;doi:10.12889/2016-COO258
- [16]. Januário AL, Barriviera M, Duarte WR. Soft tissue cone-beam computed tomography: A novel method for the measurement of gingival tissue and the dimensions of the dentogingival unit. *J EsthetRestor Dent* 2008;20:366-73.
- [17]. “Periodontal Diseases” *The Lancet*. Cardaropoli D, Gaveglio L. The influence of orthodontic movement on periodontal tissues level. *SeminOrthod*. 2007;13(4):234–245.
- [18]. Reichert C, Deschner J, Kasaj A, Jager A. Guided Tissue Regeneration and Orthodontics. A Review of the Literature. *Journal of orofacial orthopedics*. 2009;70:6-19.
- [19]. Ramachandra C.S, Shetty P.C, Rege S, Shah C. Ortho-perio integrated approach in periodontally compromised patients. *Journal Of Indian Society of Periodontology*. 2011 Oct-Dec;15(4):414-417.
- [20]. Kloehn J.S, Pfeifer J.S. The effect of orthodontic treatment on the Periodontium. *Thengle Orthodontist*. April 1974, Vol 44, no 2, 127-134.
- [21]. Detection of periodontal bone loss using digital intraoral and cone beam computed tomography images: an in vitro assessment of bony and/or infrabony defects B Vandenberghe R Jacobs and J Yang *Dentomaxillofacial Radiology* (2008) 37, 252–260
- [22]. Misch KA, Yi ES, Sarment DP. Accuracy of cone beam computed tomography for periodontal defect measurements. *J Periodontol* 2006;77: 1261–6.
- [23]. Melissa L Pereira, 2Nagarathna D. V. Application of Cbct in Periodontics IOSR Journal of Dental and Medical Sciences (IOSR-JDMS) e-ISSN: 2279-0853, p-ISSN: 2279-0861. Volume 16, Issue 6 Ver. IX (June. 2017), PP 27-30.

Naaz Amrin. “Periodontal Assesement of Orthodontic Patient Using CBCT.” *IOSR Journal of Dental and Medical Sciences (IOSR-JDMS)*, vol. 18, no. 11, 2019, pp 54-58.