

Evaluation of Mandibular Condyle Bone Marrow and Temporomandibular Joint Disc Signal Intensity in Anaemia Patients Using Magnetic Resonance Imaging

Dr. Arathy S Lankupalli¹, Dr. Srinivasan H², Dr. Saraswathi Gopal², Dr. B. G. Harsh Vardhan³

¹*Associate Professor, Faculty of Dentistry, Department of Oral Medicine and Radiology Meenakshi Academy of Higher Education and Research, Chennai*

²*Professor & Head, Faculty of Dentistry, Department of Oral & Maxillofacial Surgery, Priyadharshini Dental College, Chennai*

³*Professor & Head, Faculty of Dentistry, Department of Oral Medicine and Radiology, Meenakshi Academy of Higher Education and Research,, Chennai*

⁴*Professor, Faculty of Dentistry, Department of Oral Medicine and Radiology Meenakshi Academy of Higher Education and Research, Chennai*

Corresponding author: Dr. Arathy Lankupalli

Date of Submission: 09-12-2019

Date of Acceptance: 24-12-2019

I. Introduction

Anemia is a major public health concern in India. The prevalence of anemia is 60-90% in different age groups¹. Pregnant women, infants, young children, and adolescents are at a risk of anemia as they have a high demand of iron, folic acid and other nutrients. Anemia refers to a decrease in the total number of circulating red cells, a decrease in the hemoglobin concentration, or a decrease in the hematocrit when compared with a normal group². Such a definition must also take into account the functional ability of the blood to deliver oxygen to deprived tissues. The symptoms of anemia depend on the degree of reduction in the oxygen-carrying capacity of the blood, the change in the total blood volume, the rate at which these changes occur, the degree of severity of the underlying disease contributing to the anemia, and the power of the cardiovascular and hematopoietic systems to recuperate and compensate³. Anemia can be associated with increased morbidity and mortality from a variety of infectious diseases⁴.

Bone marrow is the 5th largest organ of the human body⁵. Its chief function is hematopoietic, providing the optimal supply of circulating platelets, white and red blood cells to meet the body's requirements for coagulation, immunity, and oxygenation. Hematopoietically active bone marrow is referred to as hematopoietic marrow or red marrow. Red marrow contains approximately 40% water, 40% fat, and 20% protein. Hematopoietically inactive marrow is referred to as yellow marrow or fatty marrow. It contains approximately 15% water, 80% fat, and 5% protein⁶.

At birth, red marrow is present throughout the entire skeleton. Normal physiological conversion of red-to-yellow marrow occurs in a predictable and orderly fashion with completion by the age of 25 years when the adult pattern is reached. In adults, reconversion of yellow marrow to red marrow occurs under stressful conditions such as anemia, or infiltrative marrow disorder, when the demand for blood cell production exceeds the existing marrow's ability to manufacture these products. Conversion of hematopoietic to fatty marrow occurs at different rates in different bones; the general view is that marrow in distal bones is converted more rapidly than marrow in proximal bones. Of facial bones, the maxilla and zygoma contain fatty marrow only; whereas the ethmoid bone does not have any marrow tissues at all. The mandible, on the other hand, still contains hematopoietic marrow in adults, conversion occurs first in the mandibular body, followed by the angle, ramus, and finally the condyle⁷.

Magnetic resonance (MR) imaging has become an important noninvasive technique for bone marrow disorders. On spin-echo T1-weighted MR images (T1W1), red marrow is seen as a low to intermediate signal intensity (SI) area, whereas yellow marrow is seen as a high signal intensity area.

To date, MRI is the only modality that enables direct visualization of bone marrow in vivo. Accurate interpretation of MR images of bone marrow requires an understanding of the anatomy, physiology, distribution, and conversion patterns. Osteonecrosis is thought to occur as a result of bone marrow oedema, presence its first manifestation in the femoral head, knee, clavus and vertebrae. Such changes can also present in the condylar head leading to pain and marrow changes. Larheim et al⁸, in their study of core biopsies of the mandibular

condyle, confirmed the existence of mandibular condyle bone marrow oedema and osteonecrosis in the temporomandibular joint (TMJ). Their results suggested that osteonecrosis can affect the mandibular condyle and oedema may be a precursor for osteonecrotic development among temporomandibular disorder (TMD) patients.

The SI changes in the TMJ such as the mandibular condyle bone marrow in chronic anemia patients, which can be a precursor for osteonecrosis, have not been adequately documented. Moreover, there is no sufficient data to study the SI changes of the TMJ disc among anemia patients.

II. Materials And Method

This study is an observational study conducted from the Department Of Oral Medicine And Radiology, Meenakshi Ammal Dental College in Chennai, in co-ordination with inpatients from the Department Of Hematology and Department Of Internal Medicine, the imaging were carried out from the Barnard Institute Of Radiology at Rajiv Gandhi Government General Hospital in Chennai.

Based on the inclusion and exclusion criteria the subjects were selected for this study. Following an informed consent, a brief clinical history, TMJ screening questionnaire and anaemia screening questionnaire were taken. This was followed by clinical and oral examination, following which haematological values were recorded and then they were subjected to MR imaging of the TMJ bilaterally.

T₁-weighted image were imaged using a MR scanner with a magnetic field of 1.5 Tesla using a dual cone surface head coil with a diameter of 6-12 cm. The imaging sequence included both coronal and sagittal plains. T₁-weighted images were acquired with a repetition time (TR) = 400 ms, eco time (TE) = 15 ms, eco train length (ETL) = 10, 192 x 256 matrix, 3 mm slice thickness, number of excitations (NEX) = 2 and a field of view (FOV) = 197 mm.

Inclusion Criteria

1. This study includes the subjects with age above 30 years and bellow 50 years.
2. The study group should have haemoglobin percentage less than 10 mg/dl.
3. This study includes both the genders.

Exclusion Criteria

1. This study excludes the subjects with any TMJ degenerative disorders.
2. This study excludes the subjects with prior surgical interventions in TMJ.
3. This study excludes subjects with an age group less than 30 years and above 50 years.

The imaging of temporomandibular joint to evaluate disc signal intensity and condyle bone marrow were carried out in anaemia patients. It revealed changes in the joint structures like condyle, articular disc, capsule and its contents. Forty joints of twenty known anaemia patients revealed significant changes in the joint. The age range of the study group was between thirty to fifty years (mean age is 39.1 years). The subjects were selected based on a detailed evaluation. Both paediatric and geriatric age group were excluded from the study. The haemoglobin percentage was less than 10mg/dl among the subjects. Efforts were also taken to exclude subjects with any known temporomandibular joint degenerative disorders and past surgical intervention of temporomandibular joint. Of the twenty patients, forty five percent were anaemic secondary to systemic diseases; twenty-five were diagnosed with aplastic anaemia, twenty percent with bleeding disorders and patients with megaloblastic anaemia constitute the remaining ten percentage. The control group consists of twenty joints of ten patients, with a mean age of 37.2 years. They were apparently healthy with haemoglobin levels more than 10 mg/dl.

III. Results:

Magnetic resonance images of various structures within the temporomandibular joint were evaluated with a focus on condyle bone marrow, anterior and posterior band of the disc. The study revealed a mean mandibular condyle bone marrow (MCBM) value as 234.11. The anterior band of the disc pronounced a value of 91.96 and posterior band exhibited 116.67 respectively. The control group showed a mean MCBM value as 330.38. The anterior and posterior bands of the disc were valued at 112.55 and 115.67. The results of this study were subjected to a statistical analysis by employing student's independent T test, to evaluate the various MR changes using SPSS (statistical package for social science) software. The analysis showed statistically significant changes involving the mandibular condyle bone marrow (P value < 0.001), anterior band (P value < 0.036) and less significant in relation to the posterior band (P value < 0.885) (Table 1).

DISC SIGNAL AND CONDYLE BONE MARROW INTENSITY OF TEMPOROMANDIBULAR JOINT AMONG ANAEMIA PATIENTS

S.No	Name	A/S	Haemoglobin Gms/dl	Final Diagnosis	MRI-TMJ SI					
					RT-SIDE			LT-SIDE		
					MCBM	TMJ DISC- AB	TMJ DISC- PB	MCBM	TMJ DISC- AB	TMJ DISC- PB
1	PALANI	45/M	8.80%	GI HEMORRHAGE	182.2	72.6	73.6	179	112.9	74.7
2	MALIYATHRI	32/M	6.50%	FUNDAL CA	178.5	99.7	123.3	256	126.7	168.2
3	KUPPURAJ	32/M	6.40%	RENAL FAILURE	170	101	100	167	93.7	124.6
4	KRISHNAN	40/M	7.60%	ANGINA	260	136	149	270	126	140
5	BALAKRISHNAN	41/M	6.20%	MA	405.9	112.7	131.7	453.9	74.7	130.7
6	ALAGESAN	35/M	4.80%	AA	305.2	91.3	103.4	311.9	101.5	94.3
7	RAMAN	41/M	4.60%	AA	421	134	132	278	141.2	156.3
8	PARIMALA	36/F	6.20%	MENORRHAGIA	207.2	99.5	120.2	229.3	137.2	91.1
9	IRFAN	45/M	6.30%	CHOLELITHIASIS	246.4	77.7	132.5	256.4	107.6	112.8
10	SRINIVASAN	37/M	7.60%	RENAL FAILURE	224.2	66.8	93.5	176.8	69.1	131.8
11	VIGNESAN	33/M	6.50%	ESOPHAGEAL CA	192.3	103.2	128	188.9	105.3	129.2
12	SHANTHI	46/F	4.60%	MENORRHAGIA	215.1	85.3	116.2	258.9	112.9	122.3
13	PRAKESH	38/M	4.60%	GI HEMORRHAGE	294.8	79.1	95.1	246.3	81.2	99
14	BALAJI	37/M	6.40%	LIVER CIRROSIS	260	136.7	149.9	270	126.7	140.9
15	CHANDRAN	46/M	4.80%	TUBERCULOSIS	170	106.6	101.1	167.1	93.7	124.6
16	MUNUSAMY	29/M	8.10%	DIABETIC FOOT	170	106.6	101.2	167.1	93.7	124.6
17	RAJESHWERI	32/M	4.00%	MA	142.8	116.9	123.1	167.8	115.1	133.9
18	SIVA	46/M	9.00%	AA	168.2	77.3	84.4	183.1	76.7	83.2
19	AYYAPPAN	44/M	3.10%	HEMATOCHEZIA	224.2	66.8	93.5	176.8	69.1	131.8
20	JYACHANDRAN	47/M	3.80%	AA	281.2	81.2	105.1	240.9	82.2	95.9

MA – Megaloblastic Anaemia; AA – Aplastic Anaemia; CA- Carcinoma; GI – Gastrointestinal; MCBM – Mandibular Condyle Bone Marrow; AB – Anterior Band; PB – Posterior Band; SI – Signal Intensity.

DISC SIGNAL AND CONDYLE BONE MARROW INTENSITY OF TEMPOROMANDIBULAR JOINT – CONTROL GROUP

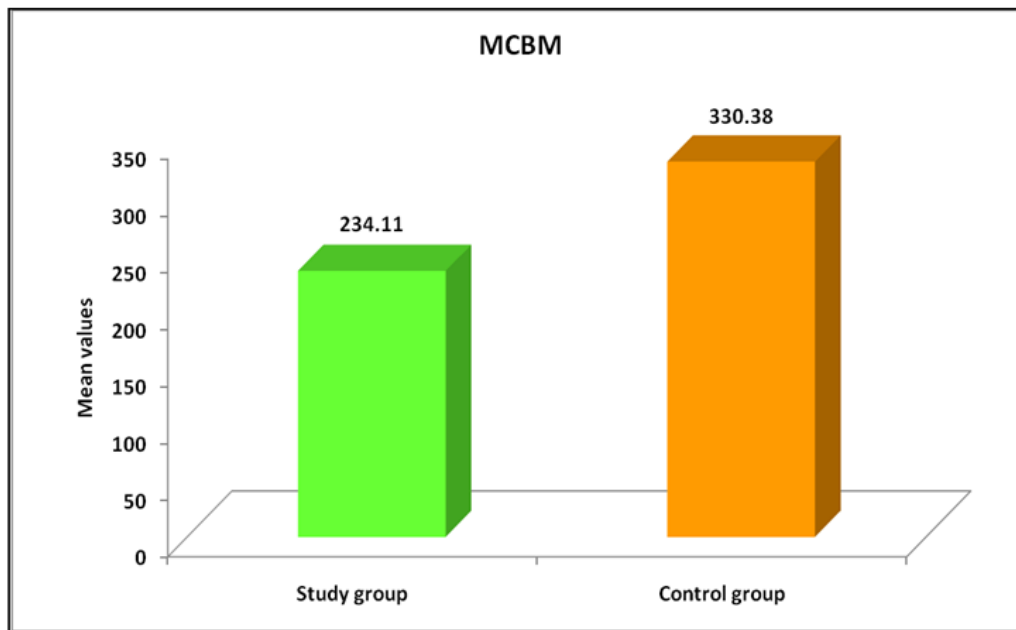
S.No	Name	A/S	Haemoglobin Gms/dl	MRI-TMJ SI					
				RT-SIDE			LT-SIDE		
				MCBM	TMJ Disc - AB	TMJ Disc - PB	MCBM	TMJ Disc - AB	TMJ Disc - PB
1	CHRISTY	32/F	11.50%	378.2	126.3	141.3	419	129	134.1
2	DHANALAKSHMI	36/F	14.20%	352.3	127.8	172.9	290	122.8	160.3
3	VASUKI	32/F	12.60%	318.6	116.6	126.8	279.7	118.2	117.3
4	MUTHURISHNA	48/F	13.40%	307	95.3	81.5	386.1	146.7	94.9
5	SRUTI	30/F	11.30%	239.7	110.3	113.9	383	116.8	111.7
6	MANOHAR	45/M	14.30%	307	95.3	81.5	386.1	146.7	94.9
7	SENTHILVEL	41/M	14.20%	274.3	114.6	85.1	337.5	123.2	160
8	SNMUGAVADIV	30/F	11.20%	270.6	91.9	81.5	370.4	71.5	112
9	GEETHA	32/F	11.20%	222.7	110.8	119.9	406.9	111	147.4
10	GIRIJA	46/F	12.20%	319.5	99.4	71.4	358.9	76.8	104.9

MCBM – Mandibular Condyle Bone Marrow; AB – Anterior Band; PB – Posterior Band; SI – Signal Intensity.

TABLE 1

Variable	Study group Mean ± SD n= 40	Control group Mean ± SD n = 20	t - value	P - Value
MCBM	234.11 ± 72.24	330.38 ± 56.20	5.215	< 0.001
TMJ Disc - AB	99.96 ± 22.13	112.55 ± 19.84	2.148	< 0.036
TMJ Disc - PB	116.67 ± 22.69	115.67 ± 29.73	0.145	< 0.885

GRAPH1



To detect marrow abnormalities on MR images, an understanding of the normal temporal patterns of red and yellow bone marrow is important. The composition of marrow varies with age. At birth and throughout early childhood marrow is predominantly haematopoietic. With ageing, haematopoietic marrow is gradually converted to yellow bone marrow. Conversion of marrow from the red to the yellow form begins in the peripheral skeleton and progresses centrally. In healthy subjects, red marrow is almost completely converted to yellow marrow during the first and second decades of life. Rates of conversion vary within particular regions of axial skeleton. The normal conversion in the mandible follows a well-defined sequence first seen in the mental region early in childhood, then in the body, the ramus and finally the condyle. The rate of conversion from red to yellow in the mandibular condyle is 60% until 15 years of age and 100% at 30 years⁶⁰.

In a recent study, it was found that MR signal conversion from red to yellow marrow was almost complete by 15 years of age. The mean age of our study group was 39.1 years; for the control group, it was 37.2 years. It can be suggested that the age-related bone marrow conversion was completed in both the study and control groups and hence the conversion process does not play a role in altering the signal intensity in this study. In adults, reconversion of yellow to red marrow occurs in pathological states such as anaemia, or infiltrative marrow disorder, when the demand for blood cell production exceeds the existing marrow's ability to manufacture these products. Reconverted bone marrow appears as diffuse or focal areas of diminished SI on T1 weighted images and exhibits a variable appearance on T2 weighted images⁶¹. Numerous studies have investigated the bone marrow reconversions of the vertebrae, femur, pelvis and knee in the settings of haematological malignancy, chronic anaemia and osteomyelitis using the various signal characteristics of the marrow on T1 and T2 weighted sequences, chemical shift imaging and fat suppression techniques. However, no such studies are documented to evaluate the marrow changes of TMJ in systemic diseases. Recent studies on the TMJ have focused on bone marrow alterations (oedema, osteonecrosis) in the mandibular condyle and investigated their relationships with age, joint pain and effusion⁶². Most of these studies stated that bone marrow oedema is closely related to internal derangement, osteoarthritis and effusion. They also reported that oedema may be a precursor for osteonecrosis in the mandibular condyle, and suggested that osteonecrosis might be a separate entity and primarily a bone marrow disease⁶³.

The present study is, to the best of our knowledge, the second that reports the bone marrow signal intensity evaluated in the mandibular condyle and TMJ disc on MR images in a series of chronic anaemia patients. The first study was done by K Orhan et al⁵⁹ (2006) in MRIs of 18 patients with chronic anaemia and was compared with 12 healthy subjects. The SI of MCBM and the TMJ disc were quantitatively evaluated. In accordance with this study, our study also had the mean MCBM SI lower in anaemia patients than in healthy subjects ($P < 0.001$). However, no statistically significant data were found between the groups with respect to the posterior band, whereas the mean SI value of the anterior band in the study group was significantly lower than in healthy subjects ($P < 0.036$).

Fewer studies have been reported to evaluate the MR imaging characteristics of cranial bone marrow among adult patients with underlying systemic disorders and compared with healthy subjects⁶⁴. They graded calvarial and clival bone marrow SI. Their analyses identified CBM as hypointense to white matter and gray

matter. Yildirim et al⁶⁵ also investigated CBM SI and its thickness among anaemia patients. Their results also proved the CBM intensity was much lower among the study group when compare to the controls and proved that there was no co-relation between the age and the signal intensity both in the study and control group. From the previous studies, it was shown that anaemia has an effect of chronic haemolysis on vascular bed function. Haemolysis results in the release of free haemoglobin, which scavenges nitric oxide by oxidizing it to nitrate and in release of red blood cell arginase, hence limiting nitric oxide bioavailability and its action. At the same time, free haemoglobin catalyses the formation of reactive oxygen species that cause direct oxidate damage to the cellular structure⁶⁶.

One possible explanation for high SI in posterior band could be the presence of various blood vessels in the posterior disc attachment, which extend through the posterior band into the intermediate zone of the disc. The effect of anaemia in these vessels might cause the lower SI values in the patient group. Previous studies found that the posterior band of the disc has vascularity, and this vascularity can be affected by internal derangements. In a study, Orhan et al⁶⁷ found that the posterior band SI increased significantly with the progress of internal derangement. The SI of the posterior bands was found to be higher than that of the anterior bands in the internal derangements. The authors explained this finding as the volume density of blood vessels being significantly higher in patients than healthy individuals. Blood vessels and connective tissue at the posterior band of the discs may account for the increased signal intensity of the posterior band. This finding was also supported by the other previous studies, which reported on the histological features of TMJ disc in asymptomatic and symptomatic patients⁶⁸. Kurita et al⁶⁹ reported a proliferative layer of fibrous connective tissue in the inferior–anterior part of the thickened posterior band of the patient’s surgically removed discs.

Kurita et al also reported about blood vessels that were located at the posterior band of the disc and surrounded by a high density of fibroblasts⁷⁰. Paegle et al⁷¹ found blood vessels in the posterior disc attachment, which extended relatively frequently through the posterior band into the intermediate zone of the disc in symptomatic patients. Recently, Chiba et al⁷² concluded that high SI in their study in the posterior disc attachment may be consistent with the increased vascularity. Thus, our study also proved that the increased vascularity of posterior band has given increased SI in both study and control group. Whereas the anterior disc with less vascularity had even more reduced vascularity in anaemia patients and expressed reduced SI than normal subjects.

IV. Conclusion

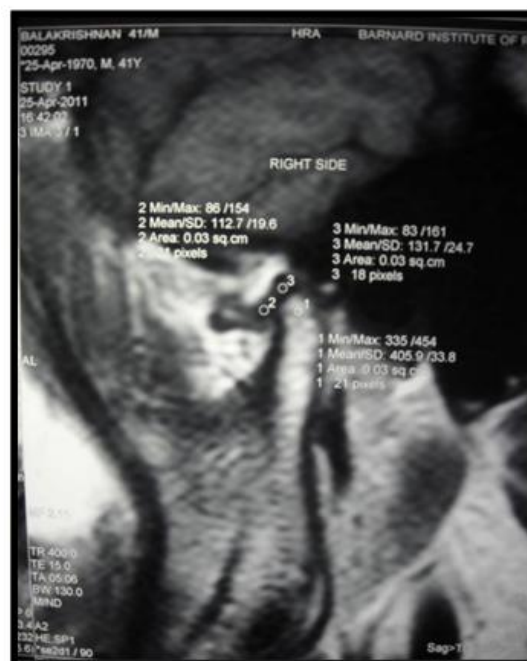Magnetic resonance images of various structures within the temporomandibular joint were evaluated with a focus on condyle bone marrow, anterior and posterior band of the disc. The study results showed statistically significant changes involving the mandibular condyle bone marrow (P value < 0.001), anterior band (P value < 0.036). However, a positive correlation with a significant P value was not evident in respect to the posterior band. Hence, a large population and follow-up studies must be addressed to evaluate this relationship and additional studies need to be conducted about comparisons of the bone marrow SI changes within groups, including TMJ internal derangement and chronic anaemia together, to ascertain how these findings can be useful in terms of clinical application.

References

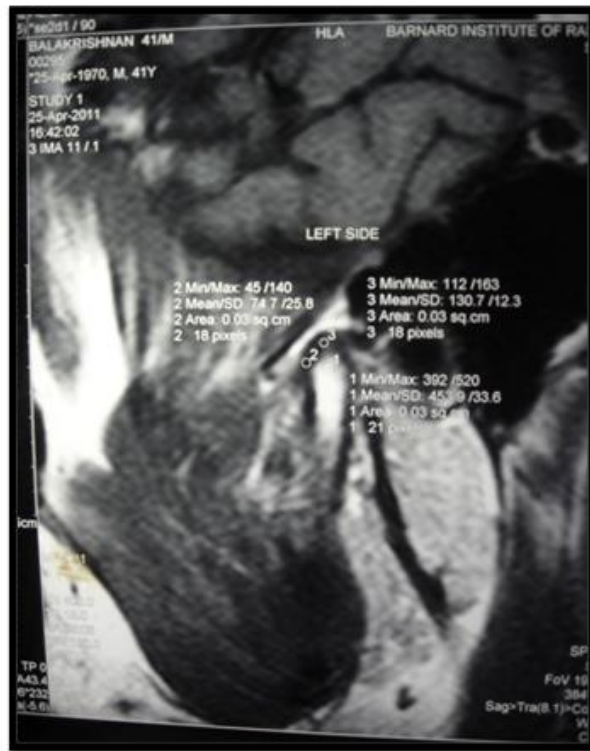- [1]. V. Sethi, G. Goindi, U. Kapil. Prevalence of anaemia amongst primary school age children in national capital territory of delhi. Indian journal of paediatrics, volume 70-june, 2003,519.
- [2]. Robert S. Hillman, Kenneth A. Ault, Henry M. Rinder, Hematology in clinical practice, clinical approach to anaemia, fourth edition, 12-26.
- [3]. De Gruchy’s Clinical Hematology in Medical Practice, The Hematopotic and Lymphoid systems, 340-358.
- [4]. WHO. Iron Deficiency Anemia. Assessment, Prevention, and Control: A guide for program managers. Geneva, World Health Organization Press, 2001; 7-33.
- [5]. John F. Feller, MRI of Bone Marrow, Advance MRI 2002 - From Head to Toe.2-4.
- [6]. Dromain C, Tardivon A, Vanel D. MRI of bone marrow disorders. Eur Radiology 2000; 10: 224-229.
- [7]. Miho Yamada, Tetsuo Matsuzaka, Masataka Uetani. Normal Age – Related Conversion of Bone Marrow in the Mandible: MR imaging findings. AJR 1995; 165: 1223-1228.
- [8]. Larheim TA, Katzberg RW, Westesson PL, Tallents RH, Moss ME. MR evidence of temporomandibular joint fluid and condyle marrow alterations: occurrence in asymptomatic volunteers and symptomatic patients. Int J Oral Maxillofac Surg 2001; 30: 113–117.
- [9]. Georges C. Dooms, M.D. Madeleine R. Bone Marrow imaging: magnetic resonance studies related to age and sex. Radiology 1985;155:429-432.
- [10]. Kricum ME. Red-yellow marrow conversion: its effect on the location of some solitary bone lesions. Skeletal Radiol 1985;14:10-19.
- [11]. Kurt P. Schellhas Clyde H. Wilkes. Temporomandibular joint inflammation : comparison of MR fast scanning with T1-and T2-weighted imaging techniques. AJR 1989;153:93-98.
- [12]. Joan K.Zawin, MD. Diego Jaramillo MD. Conversion of bone marrow in the humerus, sternum, and clavicle: changes with age on MR images. Radiology 1993;188:159-164.
- [13]. Miho Yamada, Tetsuo matsuzaka, Masatakauetani. Normal age-related conversion of bone marrow in the mandible: MR imaging findings. AJR 1995;165:12231228.

- [14]. Bruno C. Vaude Berg, MD, Idiopathic bone marrow edema lesions of the femoral head: predictive value of MR imaging findings. *Radiology* 1999;212:527-535.
- [15]. Layer G, Steudel A, Schuller H, van Kaick G, Grunwald F, Reiser M, Schild HH. Magnetic resonance imaging to detect bone marrow metastases in the initial staging of small cell lung carcinoma and breast carcinoma. *Cancer* 1999; 85:1004-1009.
- [16]. D. Vanel, C. Dromain, A. Tardivon. MRI of Bone marrow disorders. *Eur. Radiol* 2000;10:224-229.
- [17]. Tuskasa Sano, Per-Lennart Westesson, Tore A. Larheim. The association of temporomandibular joint pain with abnormal bone marrow in the mandibular condyle. *J Oral Maxillofac Surg* 2000;58:254-257.
- [18]. Loevner LA, Tobey JD, Yousem DM, Sonners AI, Hsu WC. MR imaging characteristics of cranial bone marrow in adult patients with underlying systemic disorders compared with healthy control subjects. *Am J Neuroradiol* 2002; 23: 248-254.
- [19]. Nobauer I, Uffmann M. Differential diagnosis of focal and diffuse neoplastic diseases of bone marrow in MRI. *Eur J Radiol* 2005; 55: 2-32.
- [20]. Morimoto Y, Konoo T, Tominaga K, Tanaka T, Yamaguchi K, Fukuda J, Ohba T. Relationship between cortical bone formation on mandibular condyles and alternation of the magnetic resonance signals characteristic of growth. *Am J Orthod Dentofacial Orthop*. 2007 Apr;131(4):473-80.
- [21]. Sza'nto D, Boha'tka L, Csokonay L, Schiefner G, Boross G, Ja'ger M, et al. Avascular necrosis of the mandibular condyle in systemic lupus erythematosus. *Orv Hetil* 1986; 127: 3187-3190.
- [22]. Schellhas KP, Wilkes CH, Fritts HM, Omlie MR, Lagrotteria LB. MR of osteochondritis dissecans and avascular necrosis of the mandibular condyle. *AJR Am J Roentgenol* 1989; 152: 551-560.
- [23]. Abubaker O. Avascular necrosis of the mandibular condyle: fact or fantasy. *J Oral Maxillofac Surg* 1989; 47: 1007-1008.
- [24]. el-Sabbagh AM, Kamel M. Avascular necrosis of temporomandibular joint in sickle cell disease. *Clin Rheumatol* 1989; 8: 393-397.
- [25]. White CS, Crowder JW, Dolwick MF. Avascular necrosis of the mandibular condyle: a literature review. *Today's FDA* 1991; 3: 1C, 4C, 5C.
- [26]. Chuong R, Piper MA. Avascular necrosis of the mandibular condyle-pathogenesis and concepts of management. *Oral Surg Oral Med Oral Pathol* 1993; 75: 428-432.
- [27]. Vande Berg BC, Lecouvet FE, Moysan P, Maldague B, Jamart J, Malghem J. MR assessment of red marrow distribution and MRI SI of condyle and disc in anaemia patients composition in the proximal femur: correlation with clinical and laboratory parameters. *Skeletal Radiol* 1997; 26: 589-596.
- [28]. Grinin VM, Maksimovskii M, Nasonova VA. Aseptic necrosis of the temporomandibular joint in systemic lupus erythematosus. *Stomatologiya (Mosk)* 1999; 78: 23-27 (in Russian).
- [29]. Vande Berg BC, Malghem JJ, Lecouvet FE, Jamart J, Maldague BE. Idiopathic bone marrow edema lesions of the femoral head: predictive value of MR imaging findings. *Radiology* 1999; 212: 527-535.
- [30]. Sano T, Westesson PL, Larheim TA, Rubin SJ, Tallents RH. Osteoarthritis and abnormal bone marrow of the mandibular condyle. *Oral Surg Oral Med Oral Pathol Oral Radiol Endod* 1999; 87: 243-252.
- [31]. Larheim TA, Westesson PL, Hicks DG, Eriksson L, Brown DA. Osteonecrosis of the temporomandibular joint: correlation of magnetic resonance imaging and histology. *J Oral Maxillofac Surg* 1999; 57: 888-898.
- [32]. Sano T, Westesson PL, Larheim TA, Takagi R. The association of temporomandibular joint pain with abnormal bone marrow in the mandibular condyle. *J Oral Maxillofac Surg*. 2000; 58: 254-257.
- [33]. Zanetti M, Bruder E, Romero J, Hodler J. Bone marrow edema pattern in osteoarthritic knees: correlation between MR imaging and histologic findings. *Radiology* 2000; 215: 835-840.
- [34]. Loevner LA, Tobey JD, Yousem DM, Sonners AI, Hsu WC. MR imaging characteristics of cranial bone marrow in adult patients with underlying systemic disorders compared with healthy control subjects. *Am J Neuroradiol* 2002; 23: 248-254.
- [35]. Emshoff R, Brandmaier I, Schmid C, Bertram S, Rudisch A. Bone marrow edema of the mandibular condyle related to internal derangement, osteoarthritis, and joint effusion. *J Oral Maxillofac Surg* 2003; 61: 35-40.
- [36]. Bayramoglu A, Aydingo'z U, Hayran M, Oztu'rk H, Cumhur M. Comparison of qualitative and quantitative analyses of age-related changes in clivus bone marrow on MR imaging. *Clin Anat* 2003; 16: 304-308.
- [37]. Nobauer I, Uffmann M. Differential diagnosis of focal and diffuse neoplastic diseases of bone marrow in MRI. *Eur J Radiol* 2005; 55: 2-32.
- [38]. Yildirim T, Agildere AM, Oguzkurt L, Barutcu O, Kizilkilic O, Kocak R, et al. MRI evaluation of cranial bone marrow signal intensity and thickness in chronic anemia. *Eur J Radiol* 2005; 53: 125-130.
- [39]. Patterson RJ, Bickel WH, Dahlin DC: Idiopathic avascular necrosis of the head of the femur: a study of 52 cases. *J Bone Joint Surg Br* 46:267, 1964.
- [40]. Reiskin AB. Aseptic necrosis of the mandibular condyle: a common problem? *Quintessence Int*. 1979;2:85-89.
- [41]. Ekerot L, Eiken O: Idiopathic avascular necrosis of the scaphoid: case report. *Scand J Plast Reconstr Surg* 15:69, 1981.
- [42]. Hungerford DS. Pathogenetic considerations in ischemic necrosis of bone. *Can J Surg*. 1981 Nov;24(6):583-7, 590.
- [43]. Dzioba RB, Quinlan WJ. Avascular necrosis of the glenoid. *J Trauma*. 1984 May;24(5):448-51.
- [44]. Ficat RP. Idiopathic bone necrosis of the femoral head. Early diagnosis and treatment. *J Bone Joint Surg Br*. 1985 Jan;67(1):3-9.
- [45]. Schellhas KP, Wilkes CH, Omlie MR, Peterson CM, Johnson SD, Keck RJ, Block JC, Fritts HM, Heithoff KB. The diagnosis of temporomandibular joint disease: two-compartment arthrography and MR. *AJR Am J Roentgenol*. 1988 Aug;151(2):341-50.
- [46]. Schellhas KP. Internal derangement of the temporomandibular joint: radiologic staging with clinical, surgical, and pathologic correlation. *Magn Reson Imaging*. 1989 Sep-Oct;7(5):495-515.
- [47]. Schellhas KP, Piper MA, Omlie MR. Facial skeleton remodeling due to temporomandibular joint degeneration: an imaging study of 100 patients. *AJR Am J Roentgenol*. 1990 Aug;155(2):373-83.
- [48]. Hiehle JF Jr, Kneeland JB, Dalinka MK. Magnetic resonance imaging of the hip with emphasis on avascular necrosis. *Rheum Dis Clin North Am*. 1991 Aug;17(3):669-92.
- [49]. Piper MA. Avascular necrosis of the mandibular condyle-pathogenesis and concepts of management. *Oral Surg Oral Med Oral Pathol*. 1993 Apr;75(4):428-32.
- [50]. Hayes CW, Conway WF, Daniel WW. MR imaging of bone marrow edema pattern: transient osteoporosis, transient bone marrow edema syndrome, or osteonecrosis. *Radiographics*. 1993 Sep;13(5):1001-11; discussion 1012.
- [51]. Rodert Chuong, Mark A. Piper, Thomas J. Boland, St Petersburg. Osteonecrosis of the mandibular condyle. *Oral Surg Oral Med Oral Pathol*. 1995 79:539-45.
- [52]. James M. Lieberman, Catherine L. Gardner, Antonino O. Motta, Robert D. Schwartz. Prevalence of bone marrow signal abnormalities observed in the temporomandibular joint using magnetic resonance imaging. *J Oral Maxillofac Surg*. 54 :434-439, 1996.

- [53]. Glueck CJ, McMahon RE, Bouquet J, Stroop D, Tracy T, Wang P, Rabinovich B. Thrombophilia, hypofibrinolysis, and alveolar osteonecrosis of the jaws. *Oral Surg Oral Med Oral Pathol Oral Radiol Endod*. 1996 May; 81(5):557-66.
- [54]. Plenk H Jr, Hofmann S, Eschberger J, Gstettner M, Kramer J, Schneider W, Engel A. Histomorphology and bone morphometry of the bone marrow edema syndrome of the hip. *Clin Orthop Relat Res*. 1997 Jan; (334):73-84.
- [55]. Larheim TA, Tanaka H. Posterior disc displacement in the temporomandibular joint. *J Oral Maxillofac Surg*. 1998 Nov; 56(11):1266-73; discussion 1273-4.
- [56]. Sano T, Westesson PL, Larheim TA, Rubin SJ, Tallents RH. Osteoarthritis and abnormal bone marrow of the mandibular condyle. *Oral Surg Oral Med Oral Pathol Oral Radiol Endod*. 1999 Feb; 87(2): 243-52.
- [57]. Larheim TA. Role of magnetic resonance imaging in the clinical diagnosis of the temporomandibular joint. *Cells Tissues Organs*. 1999; 180(1):6-21.
- [58]. Sano T, Westesson PL, Larheim TA, Takagi R. The association of temporomandibular joint pain with abnormal bone marrow in the mandibular condyle. *J Oral Maxillofac Surg*. 2000 Mar; 58(3):254-7; discussion 258-9.
- [59]. K Orhan, C Delilbasi, CS Paksoy. Magnetic resonance imaging evaluation of mandibular condyle bone marrow and temporomandibular joint disc signal intensity in anaemia patients. *Dentomaxillofacial Radiology* (2009) 38, 247–254.
- [60]. Kaneda T, Minami M, Ozawa K, Akimoto Y, Okada H, Yamamoto H, et al. Magnetic resonance appearance of bone marrow in the mandible at different ages. *Oral Surg Oral Med Oral Pathol Oral Radiol Endod* 1996; 82: 229–233.
- [61]. Nobauer I, Uffmann M. Differential diagnosis of focal and diffuse neoplastic diseases of bone marrow in MRI. *Eur J Radiol* 2005; 55: 2–32.
- [62]. Tanaka T, Morimoto Y, Masumi S, Tominaga K, Ohba T. Utility of frequency-selective fat saturation T2-weighted MR images for the detection of joint effusion in the temporomandibular joint. *Dentomaxillofac Radiol* 2002; 31: 305–312.
- [63]. Larheim TA, Westesson PL, Hicks DG, Eriksson L, Brown DA. Osteonecrosis of the temporomandibular joint: correlation of magnetic resonance imaging and histology. *J Oral Maxillofac Surg* 1999; 57: 888–898.
- [64]. Weishaupt D, Schweitzer ME. MR imaging of the foot and ankle: patterns of bone marrow signal abnormalities. *Eur Radiol* 2002; 12: 416–426.
- [65]. Yildirim T, Agildere AM, Oguzkurt L, Barutcu O, Kizilkilic O, Kocak R, et al. MRI evaluation of cranial bone marrow signal intensity and thickness in chronic anemia. *Eur J Radiol* 2005; 53: 125–130.
- [66]. Reiter CD, Wang X, Tanus-Santos JE, Hogg N, Cannon RO 3rd, Schechter AN, et al. Cell-free hemoglobin limits nitric oxide bioavailability in sickle-cell disease. *Nat Med* 2002; 8: 1383–1389.
- [67]. Orhan K, Nishiyama H, Tadashi S, Murakami S, Furukawa S. Comparison of altered signal intensity, position, and morphology of the TMJ disc in MR images corrected for variations in surface coil sensitivity. *Oral Surg Oral Med Oral Pathol Oral Radiol Endod* 2006; 101: 515–22.
- [68]. Holmlund AB, Gynther GW, Reinholt FP. Disc derangement and inflammatory changes in the posterior disc attachment of the temporomandibular joint: a histologic study. *Oral Surg Oral Med Oral Pathol* 1992; 73: 9–12.
- [69]. Kurita K, Westesson P-L, Sternby NH, Eriksson L, Carlsson LE, Lundh H, et al. Histologic features of the temporomandibular joint disc and posterior disc attachment: comparison of symptom-free persons with normally positioned discs and patients with internal derangement. *Oral Surg Oral Med Oral Pathol* 1989; 67: 635–643.
- [70]. Katzberg RW, Westesson PL, Tallents RH, Anderson R, Kurita K, Manzione JV, et al. Temporomandibular joint: MR assessment of rotational and sideways disc displacements. *Radiology* 1988; 169: 741–748.
- [71]. Paegle DI, Holmlund AB, Reinholt FP. Characterization of tissue components in the temporomandibular joint disc and posterior disc attachment region: internal derangement and control autopsy specimens compared by morphometry. *J Oral Maxillofac Surg* 2002; 60: 1032–1037.
- [72]. Chiba M, Kumagai M, Echigo S. Association between high signal intensity in the posterior disc attachment seen on T2 weighted fatsuppressed images and temporomandibular joint pain. *Dentomaxillofac Radiol* 2007; 36: 187–191.



MRI OF RIGHT TMJ SHOWING SIGNAL INTENSITY OF MCBM, TMJ DISK, AB & PB



MRI OF LEFT TMJ SHOWING SIGNAL INTENSITY OF MCBM, TMJ DISK, AB & PB