

Study of Histomorphological Patterns of Abnormal Uterine Bleeding On Endometrial Biopsies in a Tertiary Care Center

Dr. Germin Prabha¹, Dr. Mohan Murugesan²

¹(Associate Professor, Department of Pathology, Kanyakumari Government Medical College, Tamil Nadu)

²(Assistant Professor, Department of Pathology, Kanyakumari Government Medical College, Tamil Nadu)

Corresponding Author: Dr. Mohan Murugesan

Abstract:

Background: Normal menstrual bleeding occurs from secretory endometrium after ovulation, for a period less than 5 days. Any bleeding not complying with this is considered as abnormal uterine bleeding.

Materials and methods: This is an observational study done at a Tertiary Care Center in South Tamil Nadu, in the Department of Pathology from August 2017 to January 2019, over a period of 18months. A total of 134 specimen of endometrial biopsies received, were included in the study.

Aims and objectives: This study was conducted to learn the different histomorphological pattern of endometrial biopsies in patients with abnormal uterine bleeding and to find the incidence of carcinoma endometrium in our Government Tertiary Care Center. Later to evaluate the role of histopathological examination in predicting the cause on comparison with ultrasound examination.

Results and conclusion: In our study, most common patterns were proliferative phase(31%) followed by secretory phase(22%) and mixed pattern(18%). The incidence of carcinoma endometrium was 3.7% in our Government Tertiary Care Center. Ultrasound diagnosis of thickened endometrium, varied from less than 10mm in functional causes to 15-30millimeters in organic causes but it could not differentiate the definitive cause. On comparison histomorphological analysis were more accurate in diagnosis of functional causes and also differentiates organic causes like carcinoma endometrium from endometrial hyperplasia. Hence endometrial biopsies can be included in the initial evaluation of women with AUB along with ultrasound examination than using it as last modality for diagnostic and therapeutic purpose irrespective of age group.

Keywords: abnormal uterine bleeding, proliferative endometrium, mixed pattern, ultrasound, thickened endometrium, endometrial carcinoma

Date of Submission: 11-02-2019

Date of acceptance:28-02-2019

I. Introduction

Normal menstrual bleeding occurs from secretory endometrium after ovulation, for a period less than 5 days. Any bleeding not complying with this is considered as abnormal uterine bleeding(AUB)¹. Endometrial biopsy is done when the cause of bleeding is unknown as a last modality after various investigations like complete blood count, coagulation profile, hormonal assays like thyroid profile, follicle stimulating hormone level, leutinising hormone level, prolactin levels and ultrasound (USG)examination. In this study an attempt was made, to evaluate the role of endometrial biopsies in predicting the cause in AUB cases and to find the incidence of carcinoma endometrium in our Government Tertiary Care Center. Then compared with clinical profile and ultrasound findings in determining the cause.

II. Materials And Methods

This prospective study was done at a Tertiary Care Center in South Tamil Nadu, in the Department of Pathology from August 2017 to January 2019, over a period of 18months. A total of 134 specimen of endometrial biopsies received, were included in the study. Complete clinical details with ultrasound findings were collected. Curettings with indication of infertility work up and pregnancy related complications were excluded from study. Pattern of bleeding was noted. Patients were classified into reproductive age group(18- 40 yrs), perimenopausal(41yrs-50yrs) and postmenopausal (≥ 51 years)². The age distribution, relationship with parity and distribution of endometrial thickness were recorded. Formalin was used as fixative for endometrial biopsies. Specimen were processed routinely and sections were cut and stained. Haematoxylin and eosin(H&E) stain was used for the study. In order to reduce observer bias, stained sections were examined by two Pathologists, individually.

The histomorphological findings were categorized as functional and organic causes. Functional causes includes atrophic endometrium, proliferative endometrium, secretory endometrium, mixed pattern and

disordered proliferative endometrium . Organic causes includes endometrial hyperplasia and carcinomas. Histomorphological pattern of different age groups were studied and the incidence of endometrial carcinoma in our Tertiary Care Center was calculated. Later the distribution of histomorphological pattern with respect to endometrial thickness (ET) on USG were evaluated to compare with endometrial biopsies in determining the cause.

III. Results

Most common bleeding disturbance was menorrhagia (58%) as seen in table 1.

Table 1. Pattern of bleeding in AUB

Pattern	Number	Percentage
Menorrhagia	78	58
Polymenorrhagia	22	17
Metrorrhagia	15	11
Menometrorrhagia	4	3
polymenorrhoea	15	11
Total	134	100

Age distribution ranged from 25 to75 years and most were seen in perimenopausal age group (48%) as seen in Table 2.

Table 2: Age distribution of patients

Age groups (Years)	Total	Percentage
25-40	30	22
41-50	64	48
≥51	40	30
Total	134	100

AUB was most commonly seen in multiparous women(64%). Relationship of AUB with parity is shown in table 3.

Table 3. Relationship of parity with AUB

Parity	Number	Percentage
Nulliparous	04	3
Primiparous	34	25
Multiparous	86	64
Grand multiparous (>4)	10	8
Total	134	100

Most of them with bleed had endometrial thickness 0-5 mm (67%) as seen in Table 4.

Table 4. Distribution of endometrial thickness in AUB

ET(mm)	Number	Percentage
0-5	90	67
5.1-10	25	19
10.1-15	0	0
15.1-20	14	10
20.1-30	5	4
Total	134	100

Maximum cases presented with functional causes (86%) followed by organic causes (14%) (Table 5). Specifically diagnosed causes are categorized and enlisted in table 6 and table 7 respectively. In our study, most common patterns were proliferative phase(31%) followed by secretory phase(22%) and mixed proliferative and secretory phase(18%)as seen in table 6.

Table 5. Causes of AUB

Causes of AUB	Number	Percentage
Functional	115	86
Organic	19	14
Total	134	100

Table 6. Functional causes of AUB

Causes	Number	Percentage
Proliferative endometrium	41	31
Secretory endometrium	30	22
Atrophic endometrium	6	4
Mixed pattern	24	18
Disordered proliferative endometrium	5	4
Pseudodecidualised endometrium	9	7
Total	115	86

Table 7. Organic causes of AUB

Causes	Number	Percentage
Simple hyperplasia	12	9
Atypical hyperplasia	2	1
Endometrial carcinoma	5	4
Total	19	14

Proliferative pattern (70%) was common in reproductive age group as seen in table 8. In perimenopausal age group mixed pattern (37%) was common and in postmenopausal age simple hyperplasia (30%) was common and the incidence of carcinoma was higher (12.5%). The overall incidence of endometrial malignancy was 3.7% in our Tertiary Care Center.

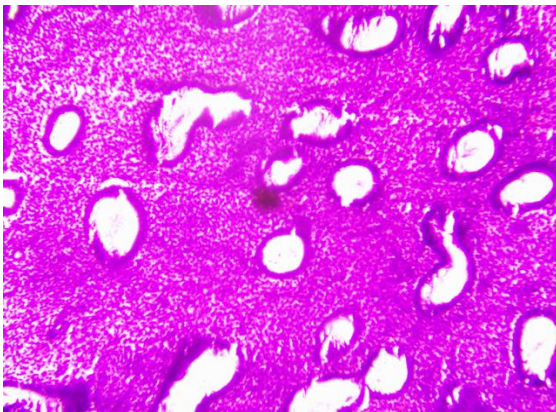


Figure1: H&E stain- Proliferative phase with uniform round to oval glands surrounded by dense stroma

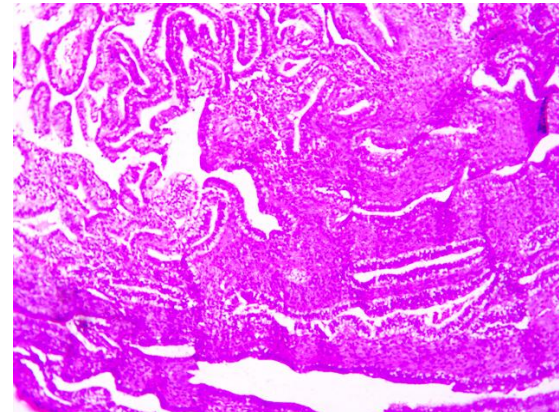


Figure2: H&E stain-Secretory phase with elongated saw toothed glands surrounded by loose edematous stroma

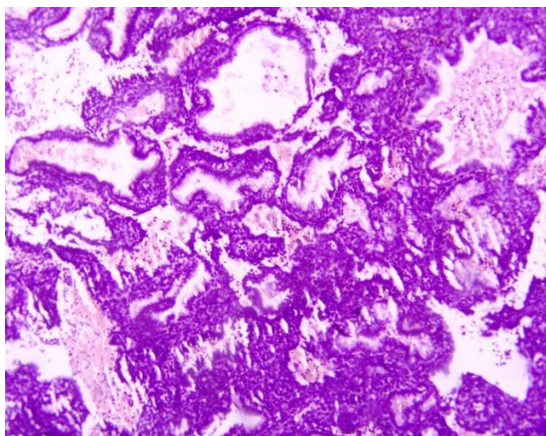


Figure3: H&E stain-Simple hyperplasia with variably sized cystically dilated glands surrounded by thin intervening stroma

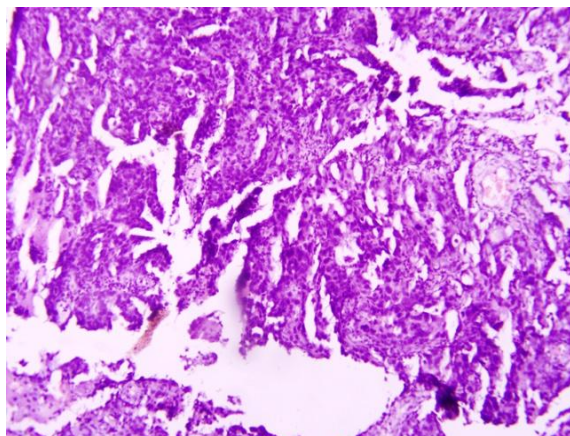


Figure4: H&E stain-Endometrial adenocarcinoma showing irregular, confluent, complex glands with prominent nuclear atypia invading into stroma

Table 8. Histomorphological pattern of different age groups

Pattern	25-40years	41-50years	≥51years	Total	Percentage
Proliferative endometrium	21	17	3	41	31
Secretory endometrium	8	18	4	30	22
Atrophic endometrium	-	-	6	6	4
Mixed pattern	-	24	-	24	18
Disordered proliferative endometrium	-	1	4	5	4
Pseudodecidualised endometrium	1	4	4	9	7
Simple hyperplasia	-	-	12	12	9
Atypical hyperplasia	-	-	2	2	1
Carcinoma	-	-	5	5	4
Total	30	64	40	134	100

In the present study, 19 cases had ET between 15-30 mm, 5 cases were diagnosed as endometrial carcinoma on histomorphological study as seen in table 9. Remaining 12 cases had simple hyperplasia and 2 cases had atypical hyperplasia.

Table 9. Distribution of endometrial diseases with respect to endometrial thickness (mm) on USG.

Pattern	0-5mm	5.1-10mm	10.1-15mm	15.1-20mm	20.1-30mm	Total
Proliferative endometrium	41	-	-	-	-	41
Secretory endometrium	30	-	-	-	-	30
Atrophic endometrium	6	-	-	-	-	6
Mixed pattern	13	11	-	-	-	24
Disordered proliferative endometrium	-	5	-	-	-	5
Pseudodecidualised endometrium	-	9	-	-	-	9
Simple hyperplasia	-	-	-	12	-	12
Atypical hyperplasia	-	-	-	2	-	2
Carcinoma	-	-	-	-	5	5
Total	90	25	0	14	5	134

IV. Discussion

Menstrual irregularities are common problem in women due to low levels of oestrogen which is not effective for normal endometrial growth. Decreased sensitivity to gonadotrophic hormones and reduced ovarian follicles are considered as causative factors.³ Debdas AK et al, Mahmood MF et al, Sarawat A et al, Arti R et al⁴⁻⁷ found menorrhagia as the most common bleeding pattern in their studies which is in concordance with our findings (58%). Most of our cases (48%) were classified in perimenopausal age group (41-50 years). Khare et al found 62% and Saera et al found 64.8% of their cases from reproductive age group.^{8,9} This difference in age distribution may be attributed to geographic factors. In our study most of the cases were multiparous women (64%) which states that AUB increases with increase in number of pregnancies which was also reported by Mehrotra VG et al, Pilli GS et al, Zarawar et al, Archana B et al.¹⁰⁻¹³ in their studies.

Ultrasound examination of uterine abnormalities is very important, yet biopsy is still preferred for confirmative diagnosis.¹⁴ A thickened endometrium on ultrasound examination is the reliable predictor of endometrial diseases,¹⁵ but is not specific. The thickened endometrium during menopause is the most significant ultrasonographical criterion implicating its pathology.¹⁶ TVS is clinically established as the preferred technique for the evaluation of endometrial disorders, especially abnormal uterine bleeding.¹⁷ In the present study, it was found that none of the patients of AUB, diagnosed with polyp, fibroid uterus and adenomyosis were admitted for endometrial biopsy due to specificity of ultrasound examination in diagnosing these diseases. Most of the cases (86%) had endometrial thickness ≤10mm.

On histomorphological examination most common were functional causes of AUB (86%) predominantly proliferative endometrium (31%) which is in concordance with that reported by Khare et al(26.8%) and Saera et al(34.6%)^{8,9} in their studies. Proliferative pattern (70%) was also common in reproductive age and bleeding during this phase can be attributed to anovulatory cycles. Ovulatory dysfunctional uterine bleeding can be the cause for bleeding in secretory phase. Mixed pattern (37%) was common in perimenopausal age group and decreased time interval of menstrual cycle and anovulation can be considered as cause for bleeding at this age. Simple hyperplasia(30%) was common in postmenopausal age group and bleeding at this age can be associated with expanding cystic glands which compresses the vessels making it prone to injury. The incidence of carcinoma was higher(12.5%) in this age group and the overall incidence of endometrial carcinoma was 3.7% in our Tertiary Care Center. 5 cases were diagnosed with endometrial carcinoma of which 3 cases were nulliparous and the other 2 cases were multiparous. This is similar to the observation made in other studies,¹⁸⁻²⁰ that nulliparity and low parity are risk factors for endometrial cancer. The

increased incidence may also be attributed to recent sedentary life style habits, obesity and diabetes which elevates the occurrence of endometrial hyperplasia that may progress into endometrial carcinoma.

On correlating the histomorphological pattern with range of endometrial thickness in ultrasound examination, it was possible to delineate functional causes from organic causes even though confirmative diagnosis is not possible. All functional causes had ≤ 10 mm thickness. 19 cases had ET between 15-30 mm, among them 5 cases were diagnosed as endometrial carcinoma with thickness 20-30mm and 14 cases were diagnosed with endometrial hyperplasia of which 2 cases showed atypical hyperplasia and all had endometrial thickness 15-20mm.

V. Conclusion

Study of histomorphological pattern of endometrial biopsies can be included in the initial evaluation of women with AUB when the cause of bleeding is not known along with ultrasound examination than using it as the last modality for diagnostic and therapeutic purpose irrespective of age group. Correlation with range of endometrial thickness on ultrasound helps us to delineate functional causes from organic causes but specific diagnosis is only possible with endometrial biopsy which remains as the gold standard.

References

- [1]. Ian S. Fraser, M.D., Hilary O.D. Critchley, M.D., Michael Broder, M.D. and Malcolm G. Munro, M.D. The FIGO recommendations on Terminologies and Definitions for Abnormal uterine bleeding, seminars in reproductive medicine 2011; vol 29(5): pg 383-390.
- [2]. James AH, Kouides PA, Abdul-Kadir R, Dietrich JE, Edlund M, Federici AB, et al. Evaluation and management of acute menorrhagia in women with and without underlying bleeding disorders: consensus from an international expert panel. Eur J Obstet Gynecol Reprod Biol. 2011;158(2):124-34.
- [3]. Davey DA. Dysfunctional uterine bleeding. In Whitfield CR editor; Dewhursts Textbook of Obstetrics and Gynaecology for postgraduates. Glasgow, Blackwell Science. 1997:590-608.
- [4]. Debdas AK, Bahol A. Histological profile of diagnostic endometrial curettage and its significance. J of the Indian Med Assoc. 1984;82:309-12.
- [5]. Mahmood MF. Irregular uterine bleeding over the age of 40 years. Ind J Obstet Gynecol. 1988;2(1):2-6.
- [6]. Sarawat A, Roohi M. Histological diagnosis by conventional dilatation and curettage. Professional Med J. 2011;18(4):587-91.
- [7]. Arti R, Nayan A. Abnormal uterine bleeding-a clinicopathological study of 160 cases. Asian J Med Res. 2013;2(1):15-8.
- [8]. Khare A, Bansal R, Sharma S, Elhence P, Makkar N, Tyagi Y. Morphological spectrum of Endometrium in patients presenting with dysfunctional uterine bleeding. People's Journal of Scientific Research .2012;5(2):13-16.
- [9]. Saera Afghan, Ara Yasmeen. Abnormal Uterine Bleeding A clinicopathological study of 150 cases. Ann. Pak.Inst.Med. Sci. 2013;9(4):201-204.
- [10]. Mehrotra VG, Mukherjee K, Pandey M, Samanth V. Abnormal uterine bleeding (a review of 150 cases). J of Obstet Gynecol India. 1972;22:684-9.
- [11]. Pilli GS, Seth SB. Dysfunctional uterine bleeding-a study of 100 cases. J Obstet Gynecol of India. 2002;52(3):87-9.
- [12]. Zarawar MP, Bolde S. Histopathological study of endometrium in dysfunctional uterine bleeding. Solapur Med J. 2005;1(4).
- [13]. Archana B, Michelle F. Evaluation and histopathological correlation of abnormal uterine bleeding in perimenopausal women. J Bombay Hosp. 2010;52:69-72.
- [14]. Medverd JR, Dubinsky TJ. Cost analysis model to compare US versus endometrial biopsy in the evaluation of peri- and postmenopausal abnormal vaginal bleeding. Radiology. 2002;222:619-27.
- [15]. Smith-Bindman R, Kerlikowske K, Feldstein VA, Subak L, Scheidler J, Segal M, et al. Endovaginal ultrasound to exclude endometrial cancer and other endometrial abnormalities. JAMA. 1998;280:1510-7.
- [16]. Schoenfeld A, Levavi H, Hirsch M, Pardo J, Ovadia J. Transvaginal sonography in postmenopausal women. J Clin Ultrasound. 1990;18:350-8.
- [17]. Saksouk FA. Endometrium, carcinoma. e-Medicine 2002: 1-29. Available at: <http://emedicine.medscape.com/article/403578overview>. Accessed 12 July 2013.
- [18]. Kaur M, Singh R, Sharma M. Endovaginal sonographic evaluation of postmenopausal uterine bleeding. J Clin Diagn Res. 2010;(4):2175-82.
- [19]. Brinton LA, Berman MC, Mortel R, Twiggs LB, Baret R, Wilbanks GD, et al. Reproductive, menstrual and medical risk factors for endometrial carcinoma: results from case control study. Am J Obstet Gynaecol. 1993;81:265-71.
- [20]. Saksouk FA. Endometrium, carcinoma. e-Medicine 2002: 1-29. Available at: <http://emedicine.medscape.com/article/403578overview>. Accessed 12 July 2013. 15

Dr. Germin Prabha. "Study of Histomorphological Patterns of Abnormal Uterine Bleeding On Endometrial Biopsies in a Tertiary Care Center." IOSR Journal of Dental and Medical Sciences (IOSR-JDMS), Vol. 18, no. 02, 2019, pp. 20-24.