

Study of Prevalence of HPV Genome and Detection of Cervical Abnormalities Using Liquid Based Cytology in HIV Positive Women

Dr. NavneetKaur, Dr. SurinderKaur, Dr.R.KKundal, Dr. ManjeetKaur,
Dr. MedhaviDhir, Dr.RamanpreetKaur
Corresponding Author: DrSurinderKaur

Abstract: Background: Cervical cancer is the second most common cancer among women worldwide. Infection with the Human Immunodeficiency Virus (HIV) and its related immunosuppression are associated with an increased risk of prevalence, incidence and persistent squamous intraepithelial lesions(SILs) of the cervix.

Objectives : (1)To study the changes in cervical cytology with relation to HPV DNA type detected by using RT-PCR in HIV positive females. (2) To find out the prevalence of cervical abnormalities in the study group comprising of 100 HIV positive women and 100 HIV negative women as a control.

Material and MethodsThe present study was conducted in the department of Pathology, GMC, Patiala on 100 cervical brushings prepared from HIV positive patients attending ART Centre at GMC and hospital, Patiala and 100 cervical brushings prepared from HIV negative women as a control which were prepared in the department of Obstetrics and Gynaecology, Rajindra Hospital, Patiala. The cervical brushings were analysed in the Department of Pathology, Government Medical College Patiala. Liquid based cytology and HPV detection was done on samples of cervical brushings.

Keywords: HPV, HIV,LBC, NILM, ASCUS, LSIL, HSIL

Date of Submission: 28-02-2019

Date of acceptance:18-03-2019

I. Introduction

Cervical cancer is the second most common cancer among women worldwide. Infection with the Human Immunodeficiency Syndrome Virus (HIV) and its related immunosuppression are associated with an increased risk of prevalence, incidence and persistent squamous intraepithelial lesions (SILs) of the cervix.^[1] India has the third highest burden of HIV and highest number of Cervical cancer patients in the world.^[2] Early detection and treatment of precancerous lesions can prevent progression to cervical cancer. Identification of precancerous lesions has been primarily by cytologic screening of cervical cells. Sensitive and specific molecular techniques that detect HPV DNA and distinguish high-risk HPV types from low-risk HPV types have been introduced as an adjunct to cytology. Earlier detection of high-risk HPV types may improve triage, treatment, and follow-up in infected patients.^[3] Human papillomavirus (HPV), a common sexually transmitted virus, is a necessary cause of invasive cervical cancer (ICC). While the vast majority of cervical HPV infections clear or become undetectable, these infections persist in a subset of women. HIV-infected women are significantly more likely than HIV-uninfected women to have incident and persistent HPV cervical infections, and to develop incident pre-cancers such as squamous intraepithelial lesions (SIL), including high-grade SIL (HSIL).^[4]

II. Material And Methods

The present study was conducted in the department of Pathology, GMC, Patiala on 100 cervical brushings prepared from HIV positive patients attending ART Centre at GMC and hospital, Patiala and 100 cervical brushings prepared from HIV negative women as a control which were prepared in the department of Obstetrics and Gynaecology, Rajindra Hospital, Patiala.

Liquid Based Cytology (By SurePaths Method)

Sample Collection for liquid based cytology^[5]

1. Cervex-brush was inserted into endocervical canal and rotated 5 times in clockwise direction.
2. The detachable head of device was dropped into BD SurePath vial.
3. The vial was capped and tightened.

LBC machine was run on cervical brushing to prepare and stain the slides. Prepared slides were examined microscopically.

HPV DNA Detection^[6]

Cervical brushings of the patients were received in the dept. of pathology. In our department the BD Onclarity HPV Assay which is an amplified DNA test for the qualitative detection of high risk types of human papillomavirus (HPV) was used. The assay detected all high risk HPV types (16, 18, 31, 33, 35, 39, 45, 51, 52, 56, 58, 59, 66, and 68) and provided the capability for genotyping of six high risk types (HPV 16, 18, 31, 45, 51 and 52) and other high-risk genotypes reported by genotype group (P1: 33/58; P2: 56/59/66; P3: 35/39/68). Cervical specimens that were tested with the BD Onclarity HPV Assay included the BD Onclarity HPV Cervical Brush Collection Kit, BD SurePath™ Preservative Fluid. The BD Onclarity HPV Assay is performed with the BD Viper™ LT System.

III. Results

In the present study, cervical brushings were taken from 100 HIV positive cases on ART attending Art centre and 100 HIV negative who presented to Department of obstetrics and Gynaecology, Rajindra Hospital, Patiala. The cervical brushings were analysed in Department of Pathology, Government Medical College Patiala.

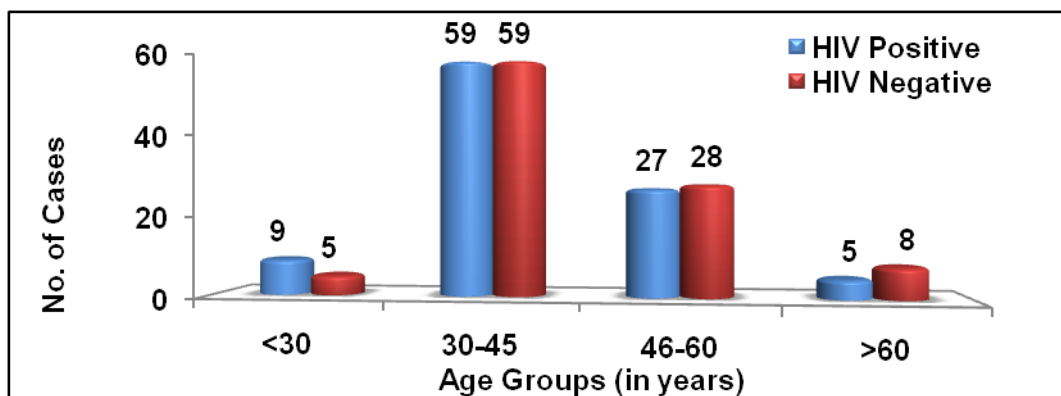


Figure 1 : HIV Status According To Age

**Table-1
Comparison of Cytology Diagnosis According To HIV Status**

Cytology Diagnosis	HIV Positive		HIV Negative		Total	
	No.	Percentage	No.	Percentage	No.	Percentage
NILM	29	29%	74	74%	103	51.5%
ASCUS	30	30%	16	16%	46	23%
LSIL	39	39%	9	9%	48	24%
HSIL	2	2%	1	1%	3	1.5%
Total	100	100%	100	100%	200	100%

Statistical Analysis

	Value	df	p value
Pearson Chi-Square	43.004	3	0.0000

Out of 100 HIV positive cases, 29 (29%) cases were diagnosed as NILM, 30 (30%) cases were ASCUS, 39 (39%) cases were LSIL, and 2 (2%) cases were HSIL. Out of 100 HIV negative cases, 74 (74%) cases were NILM, 16 (16%) cases were ASCUS, 9 (9%) cases were LSIL and only 1 (1%) case was HSIL. The cervical abnormalities were much more common in HIV positive i.e. 71 (71%) cases as compared to 26% in HIV negative cases which was statistically significant (p value of <0.001).

Table-2: Comparison Of Prevalence Of HPV According To HIV Status

HPV Status	HIV Positive		HIV Negative		Total	
	No.	Percentage	No.	Percentage	No.	Percentage
Positive	51	51%	23	23%	74	37%
Negative	49	49%	77	77%	126	63%
Total	100	100%	100	100%	200	100%

Statistical Analysis

	Value	df	p value
Pearson Chi-Square	16.817	1	0.0000

Prevalence of HPV in HIV positive cases was found to be 51% whereas in HIV negative cases it was 23%. HPV prevalence was higher in HIV positive cases than HIV negative cases and the difference was statistically significant with p value < 0.000.

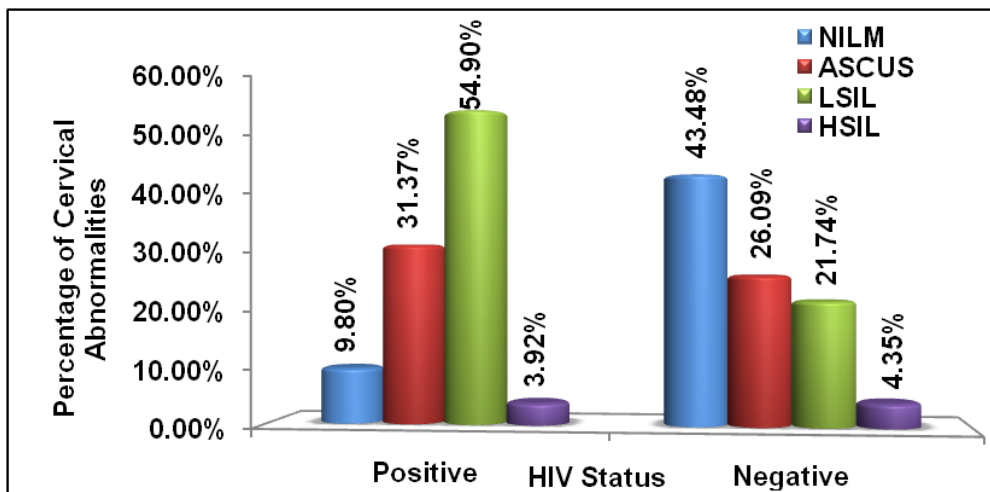


Figure 2 : Prevalence Of Cervical Abnormalities In HPV Positive Cases According To HIV Status

In HIV negative cases, majority of the cases (43.48%) were reported to be NILM whereas in HIV positive cases NILM was observed in only 9.8% cases. In HIV positive cases, 28 (54.90%), 16 (31.37%) and 2 (3.92%) cases were reported to be LSIL, ASCUS and HSIL respectively while in HIV negative cases LSIL, ASCUS and HSIL were reported in 5 (21.74%), 6 (26.09%) and 1 (4.35%) cases respectively. It was seen that cervical abnormalities were more common in HIV positive cases than HIV negative cases and the difference was statistically significant with p value < 0.00.

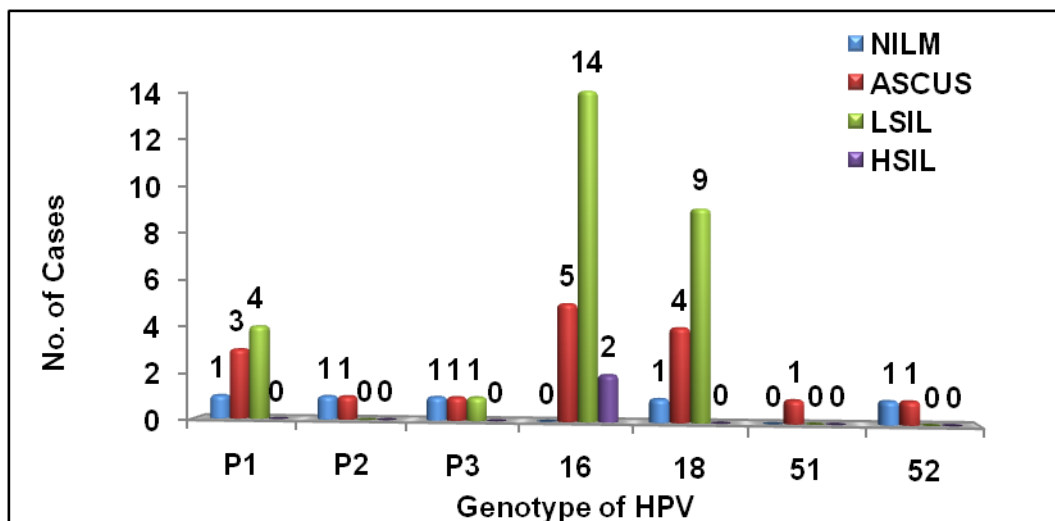


Figure 3 : HPV Genotype And Cervical Cytology In HIV Positive Cases

In 100 HIV positive cases, 51 (51%) cases were HPV positive. Out of all the types of HPV, HPV 16 and 18 were the most common type i.e in 21 (41.17%) cases and 14 (27.4%) cases respectively. Out of 21 HPV 16 positive cases, 14 (66.6%), 5 (23.8%) and 2 (9.52%) cases were LSIL, ASCUS and HSIL respectively. Out of 14 HPV 18 positive cases, 9 (64.3%), 4 (28.6%) and 1 (7.1%) cases were LSIL, ASCUS and NILM respectively. Out of 8 HPV P1 positive cases, 4 (50%), 3 (37.5%) and 1 (12.5%) cases were LSIL, ASCUS and NILM respectively. Out of 3 HPV P3 positive cases, there was 1 (33.3%) case each of LSIL,ASCUS and NILM. out of 2 cases each of HPV P2 and HPV 52 there was 1 (50%) case each of NILM and ASCUS. Only 1 (100%) case of HPV 51 was ASCUS.

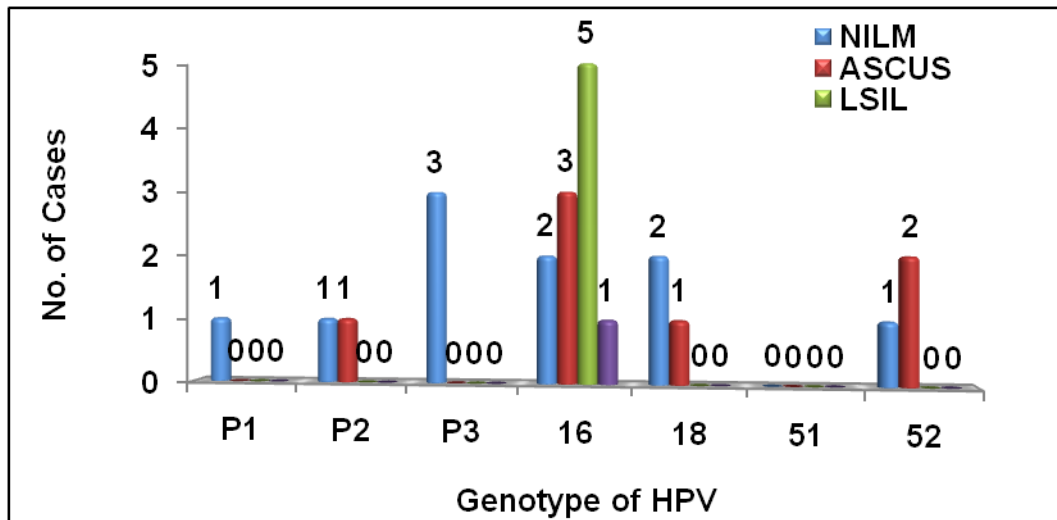


Figure 4 : HPV Genotype And Cervical Cytology In HIV Negative Cases

In the HIV negative cases, HPV positivity was observed in 23 cases and most of the cervical lesions show HPV 16 and 18 positivity i.e. 11 and 3 cases respectively. Most common cervical abnormality associated with type 16 was LSIL. Out of 11 HPV 16 positive cases, 5 (45.5%), 3 (27.3%), 2 (18.18%) and 1 (9.09%) cases were LSIL, ASCUS, NILM and HSIL respectively. Out of 3 HPV 18 positive cases, 2 (66.6%), 1 (33.4%) cases were NILM and ASCUS respectively. Out of 3 HPV52 positive cases, 2 (66.6%) and 1 (33.4%) cases were ASCUS and NILM respectively. All 3 (100%) HPV P3 positive cases were NILM. Out of 2 HPV P2 positive cases there was 1 (50%) case each of NILM and ASCUS. The only case of HPV P1 positive was NILM and of 2 cases of HPV 52 there was 1 (50%) case each of NILM and ASCUS. The only 1 (100%) case of HPV 51 which was ASCUS.

IV. Discussion

The present study was conducted in the Department of Pathology and Department of Obstetrics and Gynaecology and a total of 200 patients were included. Out of 200 patients, 100 were HIV positive on ART from ART centre and other 100 HIV negative cases were those who presented in Gynaecology outdoor. The study was undertaken to diagnose different kinds of cervical lesions in relation to HPV status. The cervical lesions were classified according to Bethesda system 2014. In the present study, samples of cervical brushings were taken from 100 HIV positive cases on ART attending ART centre and 100 HIV negative who presented to the Department of obstetrics and Gynaecology, RajindraHospital,Patiala. The cervical brushings were analysed in the Department of Pathology, Government Medical College Patiala. Liquid based cytology and HPV detection was done on samples of cervical brushings.

Prevalence of HPV in HIV Positive And Negative Cases

It had been established in previous studies that prevalence of HPV infection was higher in HIV positive as compared to HIV negative patients. In the present study prevalence of HPV in HIV positive females was found to be 51% which is similar to the results of the studies conducted by Sun et al^[7] (1995) showing HPV positivity in 60% and Motti et al^[8] (1996) showing HPV positivity in 60% cases. Blossom et al^[9] (2007) and Dartel et al^[10] (2012) observed similar results showing prevalence of HPV in HIV positive cases as 46.2% and 47.8% respectively. Miranda et al^[11] (2017) and Teixeira et al^[12] (2018) observed prevalence of HPV in HIV positive cases as 28.4% and 31.1% respectively. This discrepancy would be explained because of variation in sample size, age group distribution, socio-economic status, education level and geographic distribution.

In the present study prevalence of HPV in HIV negative cases was 23%. In the study conducted by **Motti et al**^[8] (1996) and **Branca et al**^[13] (2003) HPV positivity in HIV negative cases was 23% and 22.8% respectively. The results of the present study correlate with the above mentioned studies.

HPV Positivity in Cervical Lesions

HPV prevalence in NILM cases in HIV status

In the present study, out of 100 HIV positive cases 29 cases of NILM were detected out of which 5 (17.24%) cases showed HPV positivity. In the HIV negative cases (100 cases) a total of 74 cases were diagnosed as NILM which showed HPV positivity in 10 (13.51%) cases. In the study conducted on HIV positive patients by **Dartel et al**^[10] (2012) and by **Dols et al**^[14] (2012) the diagnosed cases of NILM showed 35.9% and 42% HPV positivity respectively. The difference in the results of the present study with above mentioned studies is probably due to variation in sample size and geographical distribution.

The results of HIV negative cases were in close accordance with the study conducted by **Dartel et al**^[10] (2012) and **Sanjose et al**^[15] (2007) where HPV positivity was seen in 12.8% and 10.4% of NILM cases .

HPV prevalence in ASCUS cases in HIV status

In the present study 30 cases were diagnosed as ASCUS in HIV positive cases out of which 16 (53.33%) cases were HPV positive .Another 16 cases were diagnosed as ASCUS in HIV negative cases out of which 7 (43.75%) cases were HPV positive. The result is similar to that observed in the study conducted by **Dartel et al**^[10] (2012) in which 66.7% cases were reported HPV positive in HIV positive patients and 37.1% cases were reported HPV positive in HIV negative patients in diagnosed cases of ASCUS. The results of present study is also similar to that observed in the study conducted by **Dols et al**^[14] (2012) in which 49.8% cases of ASCUS were HPV positive in HIV positive patients. **Teixeira et al**^[12](2018) in their study observed HPV positivity in 37.5% cases of ASCUS in HIV positive cases. This discrepancy would be explained because of variation in sample size, age group distribution and geographic distribution.

In the study by **Jung et al**^[16] (2003), 33.2% of ASCUS cases were reported HPV positive in HIV negative patients which is in accordance with the result of the present study.

HPV prevalence in LSIL cases in HIV positive status

In the present study, in HIV positive cases 39 showed LSIL out of which 28 cases (71.7%) were HPV positive whereas in 9 cases of HIV negative with LSIL, 5 (55.55%) were HPV positive. **Dartel et al**^[10] (2012), observed 100% cases of HPV positive in cases of HIV positive women with LSIL and 67.5% cases were reported HPV positive in HIV negative patients in diagnosed cases of LSIL. In the study conducted by **Dols et al**^[14] (2012) and **Teixeira et al**^[12](2018), HPV positivity was found to be 90% and 87.5% respectively in HIV positive patients with LSIL. The results are almost similar showing majority of the LSIL cases in all the studies as HPV positive. Although in the study by **Jung et al**^[16] (2003), 92.7% cases of LSIL were reported HPV positive in HIV negative patients, which is higher than that observed by others.

HPV prevalence in HSIL cases in HIV positive status

In the present study, two (3.92%) cases of HSIL were reported in HIV positive patients. Both the cases (100%) were HPV positive and one (4.35%) case was reported HSIL in HIV negative cases and which was also HPV positive (100%).

Dartel et al^[10] (2012) in their study observed that 100% cases of HSIL in HIV positive cases showed HPV positivity and 92.7% cases of HSIL in HIV negative cases showed HPV positivity which is in accordance with the present study. **De Vuyst et al**^[17] (2003) in their study observed HPV positivity in 99% cases of HSIL in HIV negative cases which is in accordance with the present study. In the study conducted by **Dols et al**^[14] (2012), 94% cases of HSIL were HPV positive and the result is very close to the present study. **Teixeira et al**^[12](2018) observed that 100% cases of HSIL in HIV positive cases showed HPV positivity which is in accordance with the present study. **Jung et al**^[16] (2003) in their study observed 98.1% cases of HSIL were HPV positive in HIV negative cases which is very close to the result of the present study.

Correlation of HPV Genotype With Cervical Cytology

Out of 100 HIV positive cases, 51 cases were reported as HPV positive and among these 28 cases were reported as LSIL on cervical cytology out of which 14 cases (50%) were HPV 16 positive. The result is similar to the study conducted by **Motti et al**^[8] (1996) in which more than 50% cases of LSIL were HPV 16 positive. **Teixeira et al**^[12](2018) observed that 23.8% cases of LSIL were HPV 16 which is in accordance with the present study.

Out of 51 cases which were HPV positive in HIV positive women, 2 cases were reported as HSIL. Both the cases were HPV 16 positive. The result is in accordance with the study conducted by **Dols et al**^[14]

(2012) in which HPV 16 was the most common genotype associated with HSIL. The study conducted by **Dartel et al^[10] (2012)** also reported HPV 16 to be the most common genotype positive in HSIL cases.

In the study conducted by **Kitchener et al^[18] (2006)** HPV either 16 or 18 were the most common HPV genotypes associated with cervical abnormalities seen in 64% cases. The result is similar to the present study in which 66% cases of HPV positive patients were either HPV 16 or 18 positive.

Sun et al^[7] (1995) in their study observed that HPV 16 and HPV 18 were more common types all in cervical abnormalities in HIV positive cases, which is in accordance to the present study.

Moodley et al^[19] (2000) in their study observed that in all the abnormal cytology smears the most prevalent HPV types were HPV 16, 58 and 51 in HIV positive cases whereas in the present study HPV 16,18,P1 are the most common types.

Bibliography

- [1]. Memiah P, Makokha V, Mbutia W, Kiiru GW, Agbor S, Odhiambo F, et al. Epidemiology of Cervical Squamous Intraepithelial Lesions in HIV Infected Women in Kenya: a cross-Sectional Study, *Afr J Reprod Health* 2015;19(1):133-9.
- [2]. Chakravarty J, Chourasia A, Thakur M, Singh AK, Sundar S, Agrawal NR. Prevalence of human papillomavirus infection & cervical abnormalities in HIV-positive women in eastern India. *The Indian journal of medical research*. 2016;143(1):79.
- [3]. Walboomers JM, Jacobs MV, Manos MM, Bosch FX, Kummer JA, Shah KV et al. Human papillomavirus is a necessary cause of invasive cervical cancer worldwide. *The Journal of pathology*. 1999;189(1):12-9.
- [4]. Abraham AG, Strickler HD, Jing Y, Gange SJ, Sterling TR, Silverberg M et al. Invasive cervical cancer risk among HIV-infected women: a North American multi-cohort collaboration prospective study. *Journal of acquired immune deficiency syndromes* (1999). 2013;62(4):405-13.
- [5]. Sample collection procedure using rovers cervix brush. Sure Path collection procedure – Doc No. 779-1001-02 Rev C. Available from :[www.bmpath.com/documents/surepath visual sheet.pdf](http://www.bmpath.com/documents/surepath_visual_sheet.pdf)
- [6]. BD Viper LT System User's Manual. Available from : [http://legacy.bd.com/ds/technicalCenter/inserts/500005363\(02\).pdf](http://legacy.bd.com/ds/technicalCenter/inserts/500005363(02).pdf)
- [7]. Sun XW, Ellerbrock TV, Lungu O, Chiasson MA. Human papillomavirus infection in human immunodeficiency virus-seropositive women. *Obstet Gynecol*. 1995;85(5 Pt 1):680-6.
- [8]. Motti PG, Dallabetta GA, Daniel RW, Canner JK. Cervical abnormalities, human papillomavirus, and human immunodeficiency virus infections in women in Malawi. *J Infect Dis*. 1996;173(3):714-7.
- [9]. Blossom DB, Beigi RH, Farrell JJ, Mackay W, Qadadri B, Brown DR et al. Human papillomavirus genotypes associated with cervical cytologic abnormalities and HIV infection in Ugandan women. *Journal of medical virology*. 2007;79(6):758-65.
- [10]. Dartell M, Rasch V, Kahesa C, Mwaiselage J, Ngoma T, Junge J et al. Human papillomavirus prevalence and type distribution in 3603 HIV-positive and HIV-negative women in the general population of Tanzania: the PROTECT study. *Sexually transmitted diseases*. 2012;39(3):201-8.
- [11]. Miranda AE, Silveira MF, Travassos AG, Tenório T, Val IC, Lannoy L, Mattos Junior HS, Carvalho NS. High-risk papillomavirus infection among women living with human Immunodeficiency virus: Brazilian multicentric study. *Journal of medical virology*. 2017;89(12):2217-23.
- [12]. Teixeira MF, Sabidó M, Leturiondo AL, de Oliveira Ferreira C, Torres KL, Benzaken AS. High risk human papillomavirus prevalence and genotype distribution among women infected with HIV in Manaus, Amazonas. *Virology journal*. 2018;15(1):36.
- [13]. Branca M, Garbuglia AR, Benedetto A, Cappiello T, Leoncini L, Migliore G et al. Factors predicting the persistence of genital human papillomavirus infections and PAP smear abnormality in HIV-positive and HIV-negative women during prospective follow-up. *International journal of STD & AIDS*. 2003;14(6):417-25.
- [14]. Dols JA, Reid G, Brown JM, Tempelman H, Bontekoe TR, Quint WG, et al. HPV type distribution and cervical cytology among HIV-positive Tanzanian and South African women. *ISRN obstetrics and gynecology*. 2012;1-5.
- [15]. Sanjose S, Diaz M, Castellsague X, Clifford G, Bruni L, Munoz N et al. Worldwide prevalence of genotype and distribution of cervical human papilloma virus DNA in women with normal cytology: a meta analysis. *The Lancet Infect Dis*. 2007;7(7):453-9.
- [16]. Jung A, Cho NA, Lee SY, Kim IH, Lee C, Kim SJ et al. Correlation of cervical carcinoma and precancerous lesions with human papilloma virus (HPV) genotypes detected with HPV DNA chip microarray method. *Cancer*. 2003;97(7):1672-80.
- [17]. De Vuyst H, Steyaert S, Van Renterghem L, Claeys P, Muchiri L, Sitati S et al. Distribution of human papillomavirus in a family planning population in Nairobi, Kenya. *Sexually transmitted diseases*. 2003;30(2):137-42.
- [18]. Kitchener HC, Almonte M, Wheeler P, Desai M, Gilham C, Bailey A et al. HPV testing in routine cervical screening: cross sectional data from the artistic trial. *British J of Cancer*. 2006;95(1):56-61.
- [19]. Moodley JR, Constant D, Hoffman M, Salimo A, Allan B, Rybicki E et al. Human papillomavirus prevalence, viral load and precancerous lesions of the cervix in women initiating highly active antiretroviral therapy in South Africa: a cross-sectional study. *BMC cancer*. 2009;9(1):275.

Dr .NavneetKaur. "Study of Prevalence of HPV Genome and Detection of Cervical Abnormalities Using Liquid Based Cytology in HIV Positive Women." *OSR Journal of Dental and Medical Sciences (IOSR-JDMS)*, vol. 18, no. 3, 2019, pp 08-13.