

## **Role of Percutaneous Sclerotherapy in Venous Malformations**

<sup>1</sup>Dr. Anshul Kumar;<sup>2</sup>Dr Mini Sinha;

Assistant Professor, Cardiothoracic Surgery, Rims, Ranchi; S. R., Cardiothoracic Surgery, Rims, Ranchi  
Corresponding Author:- Dr Mini Sinha

---

**Abstract:** Venous malformations are one of the commonest anomalies of the vascular tree and their management has always remained a major challenge. Surgery and other treatment modalities are not always satisfactory and have a higher morbidity, recurrence and complication rate. The author retrospectively analyzed 40 patients of venous malformations who underwent sclerotherapy with sodium tetradecyl sulfate solely or as an adjunct to surgery. The purpose of the study was to evaluate the efficacy and safety of sodium tetradecyl sulfate sclerotherapy in the treatment of venous malformations.

**Key Words:** Sclerotherapy, sodium tetradecyl sulfate, venous malformations

---

Date of Submission: 10-05-2019

Date of acceptance: 27-05-2019

---

### **I. Introduction**

Venous malformations are part of the spectrum of vascular malformations in which dominant structures are histologically mature venous channels. Venous malformations are difficult to treat. Various treatment modalities ranging from irradiation, electrocoagulation, intravascular needles and a long list of sclerosants have been described for their management. Surgical excision is difficult and often complete removal is not possible. Sclerotherapy is currently an established modality for the management of venous malformation. Sclerotherapy is direct injection of a sclerosing solution into the epicenter of the venous malformation during occlusion of the arterial inflow and venous outflow. The resultant endovascular obliteration of low flow venous anomalies results in satisfactory outcome.

### **II. Materials and Methods**

Percutaneous sclerotherapy was performed with sodium tetradecyl sulfate in 40 patients of venous malformations who were aged between 5-45 years. Only significantly sized cutaneous and mucosal focal venous malformations (minimum diameter > 4 cm) were included in the study. Extensive venous malformations and those necessitating anesthesia were excluded from the study. Magnetic resonance imaging (MRI) was done for evaluation only in selected cases. Appropriate informed consent was obtained. Sclerotherapy with sodium tetradecyl sulfate was a sole therapy in 35 patients and was used in combination with surgical excision in five patients. With a single exception, all venous malformations were preset at birth. The male to female ratio was 1:2. Three patients had a first degree and two had second degree relatives with venous malformations. The head and neck was involved in 17 patients, trunk in three, upper limbs in 13 and lower limbs in seven patients. The lip was found to be involved in nine out of 17 cases of head and neck presentation. Mean follow-up was two years. Each patient underwent one to six sclerotherapy sessions, followed by surgery in five cases.

### **III. Technique of injection**

After cleansing of the area, areas to be injected were marked 1 cm apart. 0.1 ml of sodium tetradecyl sulphate injection (3%) was given intralesionally with tuberculin syringe, directly into skin/mucosa, at multiple sites and contained within the lesion using manual compression for 15 to 20 minutes. The total dose was not exceeded by more than 2.0 ml and care was taken to prevent extravasation of sclerosant. Blood loss was minimal. Post sclerotherapy, antibiotics, analgesics and anti-trypsin preparations were given along with ice-pack applications. The injections were repeated after an interval of three weeks depending upon the merit of individual case, up to the maximum of six sessions.

### **IV. Results**

Sclerotherapy provided significant improvement or resolution of symptoms in good number of the patients. Out of the 40 patients, 28 patients showed moderate to fair improvement, with a very significant degree of satisfaction. In five patients, it facilitated subsequent surgery, which was rendered by it, a relatively easier procedure. Seven patients were dissatisfied for having no change or only slight improvement.

## **V. Complications and Sequelae**

All patients experienced pain and swelling to a variable degree which lasted typically for one to two weeks. A mild degree of inflammatory reaction of the overlying skin / mucosa occurred in majority of the cases. In none of the patients was any toxic-response noted at the time of injection. After injection, bleeding was noted in all the patients, which was easily controlled with pressure for five to seven minutes. In three patients, skin ulceration was noted which healed with local wound care.

## **VI. Discussion**

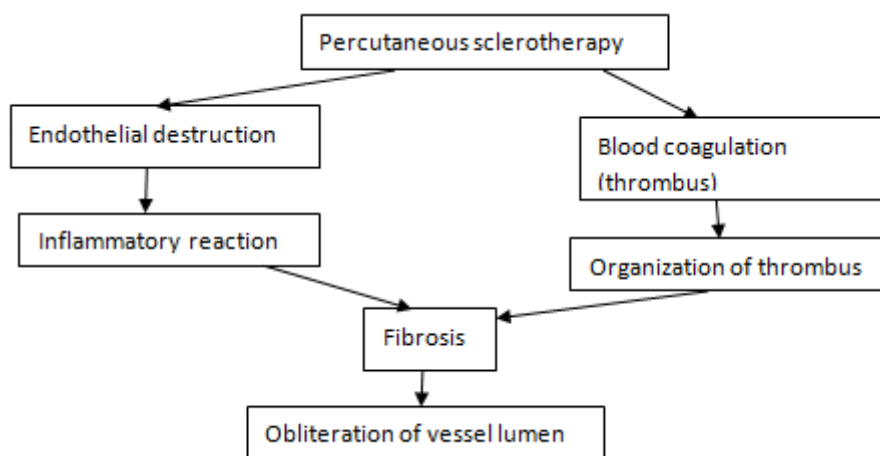
Vascular malformations are true in-born errors in the embryologic development of the vascular tree and by definition are all present at birth though not all clinically apparent. The venous malformations are the commonest of all the vascular anomalies and have a propensity for the head and neck. They can cause pain, bleeding, restriction of movement, pressure on adjacent structures, consumptive coagulopathy and aesthetic concern. They may be discrete or extensive. The overall incidence of venous malformations is reported to be 1-4% of the population and there is no predilection for either sex. They are usually singular, isolated presentations but may occur in multiple areas. They may manifest clinically in infancy, childhood, adulthood or they may remain asymptomatic throughout life. They grow commensurately with the developing child and unlike hemangiomas do not regress. Venous malformations may occur in pure form or they may be combined capillary-venous or lymphaticovenous malformations. The microscopic examination reveals dilated proliferation in vascular channels lined by normal flattened endothelial with normal mast cells count. These endothelial cells characteristically have normal rate of turn-over. MRI is the most informative investigation for venous malformations and gives off a decreased signal intensity on the T1-weighted image as compared with fat and a hyperintense signal intensity on the T2-weighted image. MRI can distinguish low-flow venous malformations from high-flow arteriovenous malformations and fistulas along with delineation of the neurovascular structures, adjacent or involved with the malformations.

Management of venous malformations has always remained a major challenge because treatment carries a significant risk of morbidity and the recurrence. Surgical resection, though definitive treatment, is often not feasible except for smaller lesions because of deeper involvement of neurovascular structures particularly in the head and neck and extremity malformations. Incompletely excised lesions have a strong tendency to recur. Laser treatment of venous malformations have also been attempted with varying success rate. Laser photocoagulation with argon, Nd-Yag or combination lasers have been found to be somehow effective for tiny superficial venous or capillary-venous lesions but not for significantly sized lesions. Recurrence is common and often repeated treatments are necessary. Hence they may be useful in select group of patients. Sclerotherapy alone or in combination with surgical excision is now the accepted treatment modality in symptomatic venous malformations. Localized areas can be treated without an incision and diffuse, extensive lesions may be symptomatically palliated. Conservative management with numerous sclerosing agents (boiling water, alcohol, sodium morrhuate, quinine, urethan, silver nitrate, iron, zinc chloride, liquid vegetable protein) have been used since the 18th century for the treatment of a wide variety of vascular anomalies. Sclerosing agents basically are irritants that injure the endothelial surfaces, ultimately resulting in obliteration of the space between these surface. Sclerosing agents have been classified into three groups based on the mechanism of action causing the injury to the endothelium.

- A) Detergents: Polidocanol, sodium tetradecyl sulfate, sodium morrhuate and ethanolamine oleate. The detergents cause injury by altering the surface tension surrounding endothelial cells.
- B) Osmotic agents: Hypertonic saline, hypertonic saline / dextrose. They act through endothelial damage through dehydration.
- C) Chemical irritants: Chromated glycerin, polyiodinated iodide.

The chemical irritants include the corrosives, which act by a cauterizing action and those which injure cells by a heavy metal effect. Direct injection sclerotherapy is a valuable treatment modality for venous malformations with promising results. Percutaneous ethanol has been found to be effective in various studies. However ethanol embolization is a significant risk. Absolute alcohol is the most effective sclerosant but should not be used near important structures like vessels and nerves, where 3% sodium tetradecylsulfate is preferred. Ethibloc has also been utilized for sclerotherapy but the drawback of lack of commercial availability and necessity for GA precludes its use. The sodium tetradecyl sulfate has been used extensively for sclerotherapy of varicose veins since it was first described by Reiner in 1946. Many of the previous studies have noted good results achieved in vascular malformations with the use of this substance. However Sclerotherapy of major venous malformations is dangerous. There are no randomized studies that have compared the various sclerosing agents. We have chosen sodium tetradecyl sulfate as it is an easily available effective sclerosant, which is well-tolerated and is without systemic side-effects. Sodium tetradecyl sulfate is a synthetic surface-

acting substance. It is a long chain fatty acid set of an alkali metal with the property of a soap. It is a clear, nonviscous liquid with low surface tension. It is composed of sodium-1 isobutyl-4 ethyl octyl sulfate plus benzoyl alcohol 2% and phosphate buffered to a pH of 7.6. The action of this sclerosing agent has been summarized into flow-chart (Fig. 1).



**Fig. 1:** Flow-chart

## VII. Conclusion

The management of venous malformations becomes increasingly complex as they often involve adjacent neurovascular structures. Surgery and other treatment modalities are often not feasible or not attempted alone because of the associated morbidity. Conservative management in form of sclerotherapy with sodium tetradecyl sulfate has been found to be an inexpensive, readily available outpatient procedure. It is quite safe and especially useful in areas where surgery is hazardous. Though it does not resolve larger venous malformations it does decrease the size and vascularity to facilitate future surgery or act as a palliative treatment. To summarize, percutaneous sodium tetradecyl sulfate when used either alone or as adjunct to surgery is a safe, effective and inexpensive agent in the treatment of venous malformations. However proper case selection, evaluation and careful planning is necessary to reduce unwarranted risks and complications.

## References

- [1]. Berenguer B, Burrows PE, Zurakowski D, Mulliken JB. Sclerotherapy of craniofacial venous malformations complications and results. *Plast Reconstr Surg* 1999;104:1-15.
- [2]. Figi FA. Treatment of hemangiomas of the hand and neck. *Plast Reconstr Surg* 1948;3:1.
- [3]. Goldwyn RM, Rosoff CB. Cryosurgery for large hemangiomas in adults. *Plast Reconstr Surg* 1969;43:605-11.
- [4]. Wilflingseder P, Martin R, Papp CH. Magnesium seeds in the treatment of lymph and haemangiomas. *Chir Plast* 1981;6:105.
- [5]. Cole PP, Hunt AH. The treatment of cavernous haemangiomas and cirroid aneurysms by the injection of boiling water. *Br J Surg* 1949;36:346.
- [6]. Mulliken JB, Glowacki J. Hemangiomas and vascular malformations in infants and children: A classification based on endothelial characteristics. *Plast Reconstr Surg* 1982;69:412-20.
- [7]. Rak KM, Yakes WF, Ray RL, Dreisbach JN, Parker SM, Luethke JM, et al. MR imaging of symptomatic peripheral vascular malformations. *AJR Am J Roentgenol* 1992;159:107-12.
- [8]. Sarig O, Kimel S, Orenstein A. Laser treatment of venous malformations. *Ann Plast Surg* 2006;57:20-4.
- [9]. Ulrich H, Baumler W, Hohenleutner U, Landthaler M. Neodymium-YAG Laser for hemangiomas and vascular malformations—long term results. *J Dtsch Dermatol Ges* 2005;3:436-40.
- [10]. Derby LD, Low DW. Laser treatment of facial venous vascular malformations. *Ann Plast Surg* 1997;38:371-8.
- [11]. Morgan JF, Schow CE Jr. Use of sodium morrhuate in the management of hemangiomas. *Oral Surg* 1974;32:363-6.
- [12]. Riche MC, Hadjean E, Tran-Ba-Huy P, Merland JJ. The treatment of capillary- venous malformations using a new fibrosing agent. *Plast Reconstr Surg* 1983;71:607-14.
- [13]. Ochsner A, Garside E. The intravenous injection of sclerosing substances; Experimental comparative studies of changes in the vessels. *Ann Surg* 1932;96:691-718.
- [14]. Rotter SM, Weiss RA. Human saphenous vein in vitro model for studying the action of sclerosing solutions. *J Dermatol Surg Oncol* 1993;19:59-62.
- [15]. Lee CH, Chen SG. Direct percutaneous ethanol instillation for treatment of venous malformation in the face and neck. *Br J Plast Surg* 2005;58:1073-8.
- [16]. Pappas DC Jr, Persky MS, Berenstein A. Evaluation and treatment of head and neck venous vascular malformations. *Ear Nose Throat J* 1998;77:914-6,918-22.
- [17]. Minkow B, Laufer D, Gutman D. Treatment of oral hemangiomas with local sclerosing agents. *Int J Oral Surg* 1979;8:18-21.
- [18]. Dubois JM, Sebag GH, De Prost Y, Teillac D, Chretien B, Brunelle FO. Soft-tissue venous malformations in children: Percutaneous sclerotherapy with Ethibloc. *Radiology* 1991;180:195-8.
- [19]. Reiner L. The activity of anionic surface active compounds in producing vascular obliteration. *Proc Soc Exp Biol Med* 1946;62:49-54.

- [20]. Siniluoto M, Svendsen PA, Wikhojn GM, Fogdestam I, Edstrom S. Percutaneous sclerotherapy of venous malformations of the head and neck using sodium tetradecyl sulphate (sotradecol). *Scand J Plast Reconstr Surg Hand Surg* 1997;31:145-50.
- [21]. O'Donovan JC, Donaldson JS, Morello FP, Pensler JM, Vogelzang RL, Bauer B. Symptomatic hemangiomas and venous malformations in infants, children, and young adults: Treatment with percutaneous injection of sodium tetradecyl sulfate. *AJR Am J Roentgenol* 1997;169:723-9.

Dr Mini Sinha. "Role of Percutaneous Sclerotherapy in Venous Malformations." *IOSR Journal of Dental and Medical Sciences (IOSR-JDMS)*, vol. 18, no. 5, 2019, pp 10-13.