

## **Arteriovenous Malformation of Parotid Gland: Rare Case Report**

H.Habibi, A.Lahlou, JB.Agai,N.Bouardi,C.Beiba,M.Haloua, B.Alami,  
Y.AlaouiLamrani, M. Maaroufi, M. Boubbou  
*Corresponding author: H.Habibi*

Date of Submission: 06-05-2019

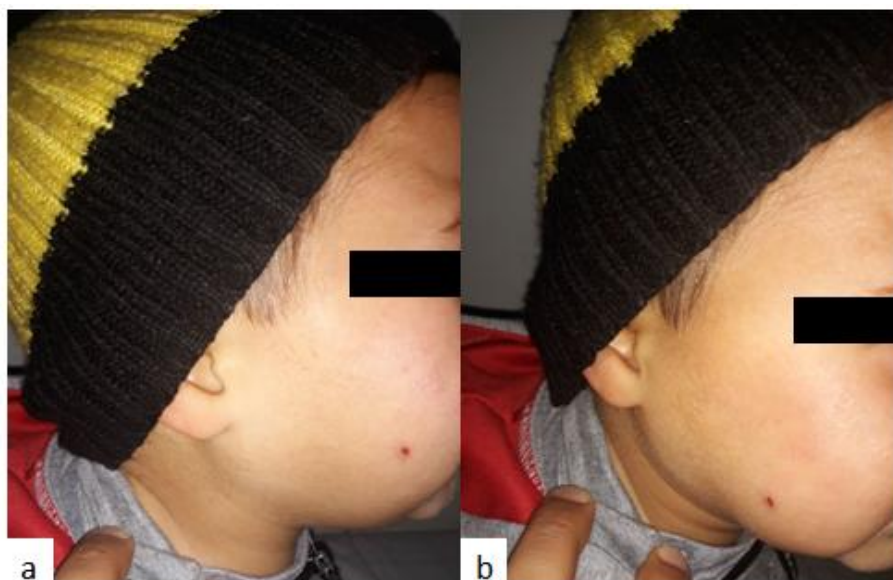
Date of acceptance: 20-05-2019

### **I. Introduction**

The parotid gland remains the most common location of salivary gland tumors, pleomorphic adenoma ranks first. However, vascular anomaly in parotid gland is relatively rare. The vascular anomalies were divided into two categories: hemangiomas and vascular malformations. Hemangiomas are benign tumors that occur in the lining of the blood vessels with endothelial proliferation. Vascular malformations are malformation with a normal rate of endothelial turnover categorized into low-flow lesions (capillary, lymphatic and venous malformations) and high-flow lesions (arteriovenous malformations and arteriovenous fistula). In order to avoid dramatic complications, it is important to know the symptoms and to make an early diagnosis of a possible vascular malformation of the parotid gland.

### **Case Report:**

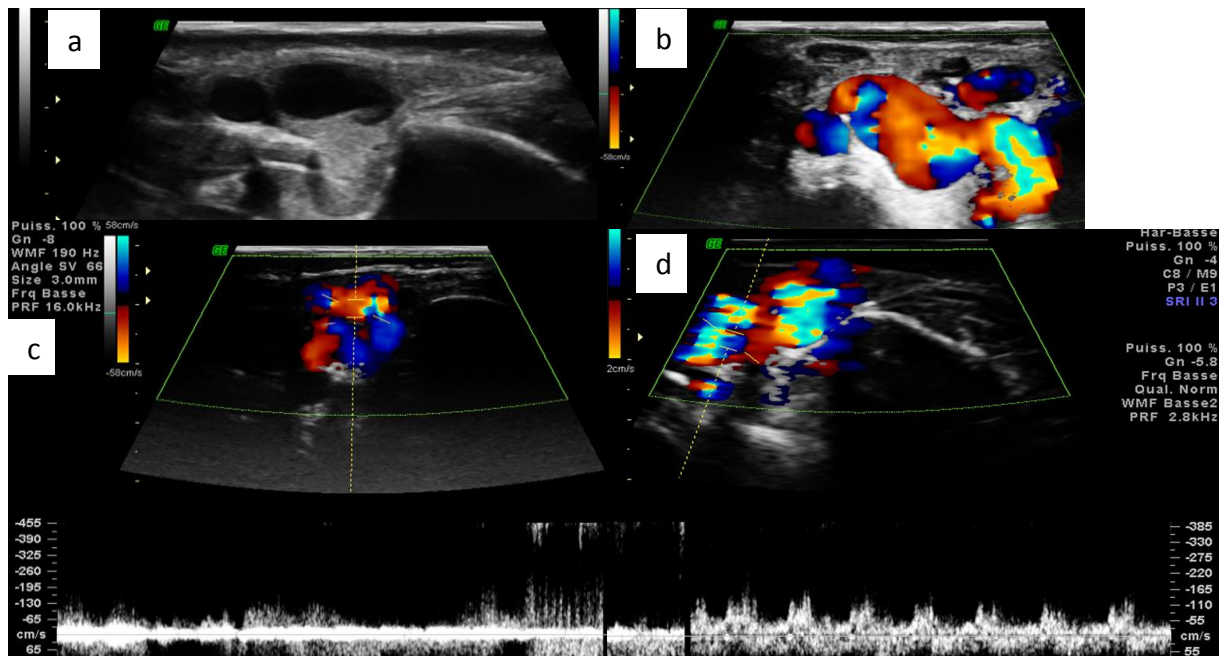
A 2-years-old male was admitted to a pediatric consultation for beating right cervical swelling. History revealed that a right retro-auricular mass was noticed by the patient's mother one year previously and had gradually increased in size. The physical examination found a soft, non-tender, painless and well defined right parotid mass with no inflammatory sign around measuring 1.5x2 cm. This mass increased in size with teeth-clenching ("Turkey Wattle Sign" (Figure 1)). The rest of the examination did not show any associated cervical adenopathy.



**Figure 1 :**

**a :** Patient presenting with swelling in front and below the right ear;  
**b:** Swelling increasing in size while crying (Turkey-Wattle sign).

The ultrasonography found multiple serpiginous intra-parotid structures which take both arterial and venous signals within the same Doppler sample volume (Figure 2). Following this, a CT-scan of the cervical region was done which showed serpiginous structures with an early enhancement involving the whole right parotid gland suggestive of an arteriovenous malformation (Figure3). The patient did not receive any interventional or surgical treatment and was then lost to follow-up.

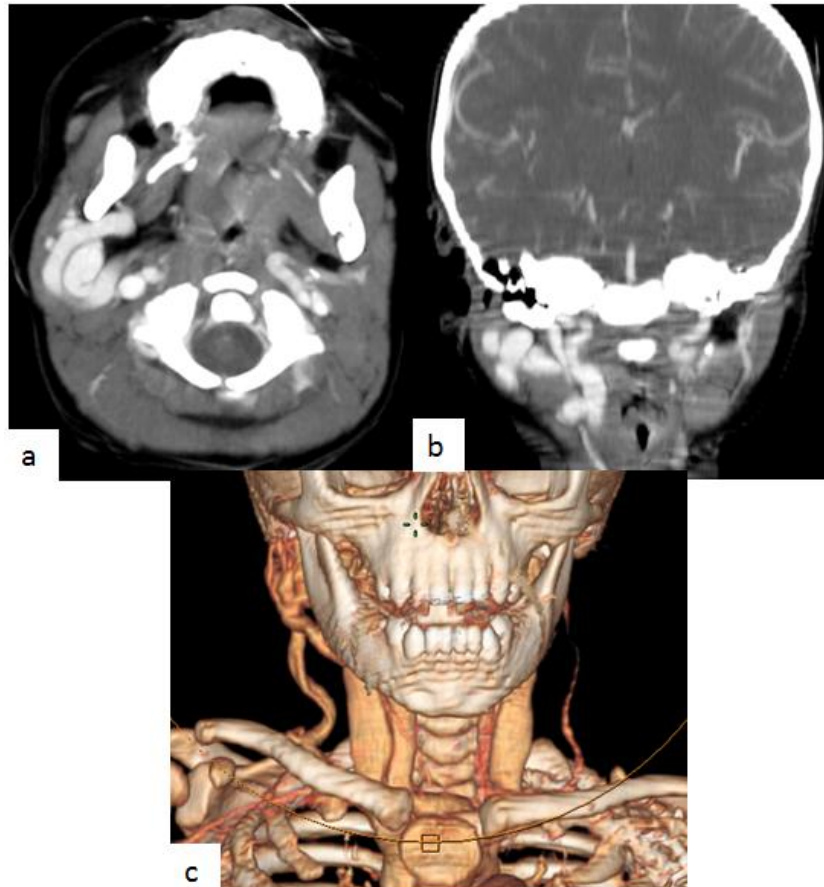


**Figure 2:**  
**a,b** :anechoic structures with serpiginous vascular flow on colormapping  
**c,d** : doppler ultrasounddemonstratesarteriel flow for some structures and veinous flow for others.

## II. Discussion

For many years the vascular lesions were a topic of debate, they used to be considered as hemangiomas, until 1982 when Mullikin and Glowacki separated them into vascular malformation and hemangiomas [1]. In the time following, diagnosis of hemangioma and vascular malformation were given randomly. Therefore the International Society for Study of Vascular Anomalies has established a classification that differentiates two entities: vascular tumors (lesion with cell proliferation) and vascular malformation (morphological vascular anomaly).

Very few cases of vascular malformation of the parotid gland have been reported in the literature (50 cases) [1.2] because of their scarcity. Bears et al published 760 cases of parotid tumors, a frequency of 0.5% comparing to 0.6% for Byars et al who published 460 parotid tumors [3.4]. In a latter-day study done by Achache M et al, only 1.6% of the whole parotid swellings, compiled over 10 years from 1998 to 2008, were vascular malformations. A clear predominance of women was observed. The superficial lobe of parotid gland was the most common location[6].Vascular malformations are presented as a painless hypertrophy of the soft tissues progressively evolving without any associated symptoms. No nervous, ganglionic or cutaneous involvement is usually found. The physical examination may find an enlargement of the mass while teeth-clenching under the name of « Turkey wattle sign »,referring to the red vascular structure existing on the male turkey neck, which is pathognomonic of a vascular malformation or hemangioma[5].



**Figure 3:**

**a,b :** CT axial and coronal view showing enlarged ipsilateral external carotid artery branches and external jugular vein  
**c :** CT 3D reconstruction

Ultrasonography is not very contributive. The CT scan can be used to make the diagnosis but the magnetic resonance imaging remains the examination of choice. It allows to show a high T2-weighted signal of serpiginous structures which are enhanced after injection of gadolinium [2]. The angiography can be performed in case of difficulty on the MRI.

There are several treatment modalities such as corticosteroids, laser, cryotherapy and embolization for hemostatic, functional and cosmetic purposes. However, surgery remains the treatment of choice. Anathomopathologic examination shows ectasic and dilated veins that may be partially thrombosed or containing calcifications. The stroma may consist of adipose tissue, lymphocyte and muscle cells.

### III. Conclusion

Vascular malformations of the parotid gland are very rare.They are evoked in front of a progressively increasing painless cervical swelling, with a “turkey wattle sign”.Imaging, especially the MRI,poses the diagnostic to enable effective treatment dominated by surgery.

**Bibliography**

- [1]. Yakes WF. Diagnosis and management of low-flow veno-lymphatic vascular malformations. *CeskaRadiol.* 2008;62:131–45.
- [2]. Kadota Y, Utsumi T, Kawamura T, Inoue M, Sawabata N, Minami M, et al. Lymphatic and venous malformation or “lymphangiohemangioma” of the anterior mediastinum: Case report and literature review. *GenThoracCardiovascSurg.* 2011;59:575–8.
- [3]. Beahrs OH, Woolner LB, Carveth SW, et al. Surgical management of parotid lesions. Review of seven hundred sixty cases. *Arch Surg.* 1960;80:890904.
- [4]. Byars LT, Ackerman LV, Peacock E. Tumors of salivary gland origin in children: a clinical pathologic appraisal of 24 cases. *Ann Surg.* 1957;146(1):40-51.
- [5]. Saeed WR, Kolhe PS, Smith FW, et al. The ‘turkey wattle’ sign revisited: diagnosing parotid vascular malformations in the adult. *Br J Plast Surg.* 1997;50:43–6.
- [6]. Achache M, Fakhry N, Varoquaux A, Coulibaly B, Michel J, Lagier A, et al. Management of vascular malformations of the parotid area. *Eur Ann Otorhinolaryngol Head Neck Dis.* 2013;130:55–60.