

Original Article: Elastasonographic Assessment of Breast Lumps

Rajesh Narayan

Associate Professor, Department of Surgery, Vardhaman Institute of Medical Sciences, Pawapuri, Bihar Sharif
Aryabhatta Knowledge University, Patna, Bihar, India
Corresponding Author : Dr. Rajesh Narayan

Abstract: **Aim:-** The aim of the study is to use shear modulus and sound touch elastasonography for retrospective study of 43 consecutive women with breast lumps to differentiate between malignant and benign lesions. **Methods :-** Elastasonography provides a noninvasive evaluation of the stiffness of a lesion. Strain and shear wave elastasonography improves the possibility of differentiating benign from malignant lesions there by limiting recourse to biopsy. **Result :-** The parameters of sound touch elastasonography provide valuable data for the evaluation of Breast lesions. The histopathological result obtained from operative excisions was used as the reference standard. Malignant lesions were 11.63%, benign 81.40% chronic inflammation 4.65% lobular hyperplasia 2.32%. Analysis of elastasonography showed better accuracy and valuable tool for early diagnosis of small breast lesions. Elastasonography show high specificity, accuracy and confidence limit for differentiation of benign and malignant breast lesions. The size of the lesions ranged from 10mm to 70mm with a mean size of 22+-1mm. All malignant lesions had normalized shear strain area greater than 1.3. The elastasonography diagnostic sensitivity specificity and accuracy were 90%, 85% and 89% respectively.

Conclusion :- Elastasonography show high sensitivity, high specificity and accuracy for differentiation of benign and malignant breast lesions. Elastasonography is important for the diagnosis of small breast lesions. The present findings revealed that a higher elasticity proportion were more likely to be benign diseases.

Keywords :- Elastasonography, Sound touch elastasonography shear modulus, Breast Cancer.

Date of Submission: 28-06-2019

Date of acceptance: 15-07-2019

I. Introduction:

Breast cancer is the most common invasive cancer worldwide. Mammography and ultrasonography are two sensitive diagnostic methods routinely used in clinical setting to evaluate breast lumps. Elastasonography is a non-invasive technique in which stiffness or strain images are used to detect and classify anatomical areas with different elasticity patterns [1]. Elastasonography is regarded as a fundamental adjunct to diagnostic tool for ultrasound imaging [2][3]. A difference in the rise of tumor between B- mode and elastasonography imaging and the differential color patterns showing different grayscale distribution in the elastasonography images appear to be the new characteristics that allow distinguish benign from malignant lesion [4]. Shear wave elastasonography provides stiffness measurement by displaying the shear wave propagation speed of the tissue, shear modulus and Young's modulus[5][6]. A high Young's modulus is used to quantify the stiffness. For a linear, elastic isotropic medium Young's modulus E can be estimated by

$$E=3G=3\rho CS^2$$

Where G is the shear modulus that quantifies the medium shape changes, ρ is the density and CS is the speed of shear wave [7][8][9]. Sound Touch Quantification directly performs quantitative measurement tissue stiffness to assess elasticity values [10]

II. Material & Methods:

This retrospective study was approved by our institutional review board. All the patients were examined by same radiologist in Millennium Scan Pvt. Ltd Patna using Sound Touch Elastasonography and Axial Shear strain imaging on Siemens Ultrasound system. The breast was scanned with the patient in the Supine position with her ipsi lateral hand behind her head. Freehand compression of up to 10% was utilized for acquiring data loops. The axial strain and the axial component of the shear strain tensor were approximated to obtain images and corresponding correlation coefficient maps the strain ratio was measured by determining the average strain measured in a lesion and comparing it to the average strain of a similar area of fatty tissue in the adjacent breast tissue in the adjacent breast tissue. Between July 2010 and April 2019 data analyzed from 43 patients demonstrate good differentiation between benign fibro adenoma and malignant masses utilizing the axial shear component images. Pathological analysis of the breast lump samples were obtained via biopsy or surgery. The statistical analysis was done by SPSS 17.0 and scatter gram plotted.

III. Result:

The Clinical analysis of consented patients means age of 33 years (Range 20-70 years) with 13.95% bilateralism. The size of the lesions ranged from 10mm to 70mm with a mean size of 22+-1mm. Table 1 shows pathological diagnosis of breast lesions with Malignancy in 11.63%, Benign Lesions 81.40% and Lobular Hyperplasia in 2.32%. Fig 1 presents a scatter plot of the normalized area of the normalized axial – shear strain values. Most fibro adenoma exhibits a feature value smaller than and all 5 cancers exhibit features values greaten than 1. We set the discriminate value to be 1.3. The overall elastosonography diagnostic sensitivity 90%, specificity 85% and accuracy was 89%. Elastosonography provides more evidence in diagnosis of small breast lesion and BIRADS Type IV.

Table 1 Pathological Diagnosis of 43 Breast Lesions

Pathological Diagnosis	No of items	%
Malignant lesions	5	11.63
Benign Lesions	35	81.40
Chronic inflammation	2	4.65
Lobular Hyperplasia	1	2.32
Total	43	100.00

Young’s modulus had been used to assess the stiffness of lesions. Ophiretal raised the concept of elastosography in 1991

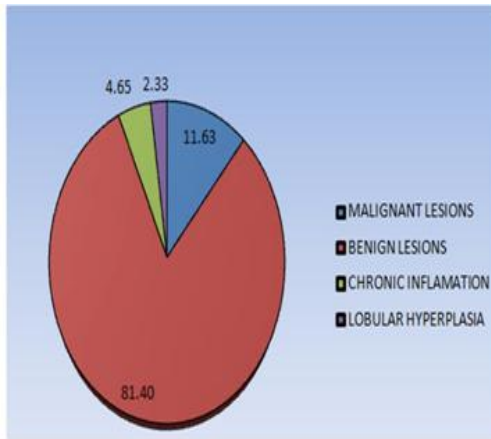


Fig I: PATHOLOGICAL DIAGNOSIS OF BREAST LESIONS

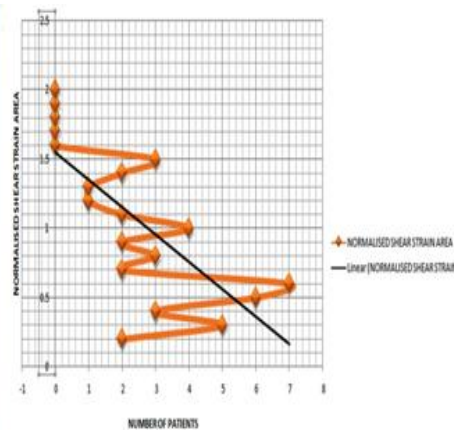


Fig II: SCATTERGRAM SHOWING AXIAL SHEAR STRAIN PARAMETER

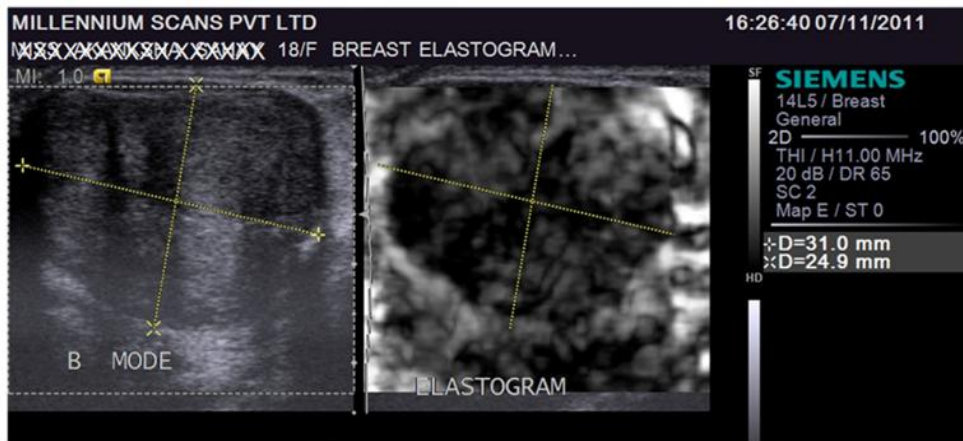

Fig III: ELASTOSONOGRAPHY OF BENIGN BREAST LESION

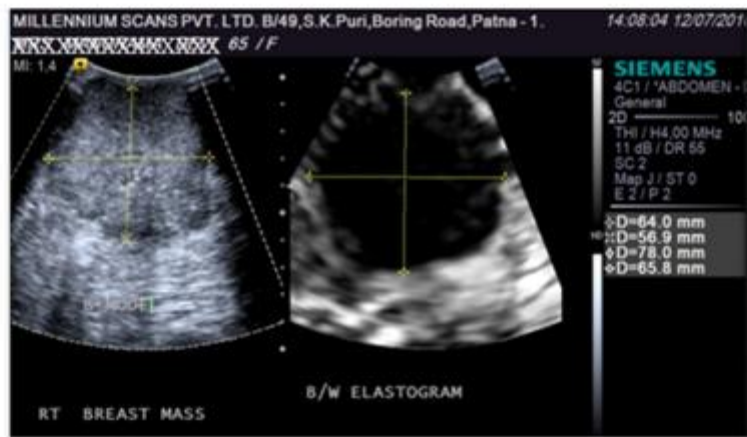

Fig IV : ELASTOSONOGRAPHY OF MALIGNANT BREAST LESION

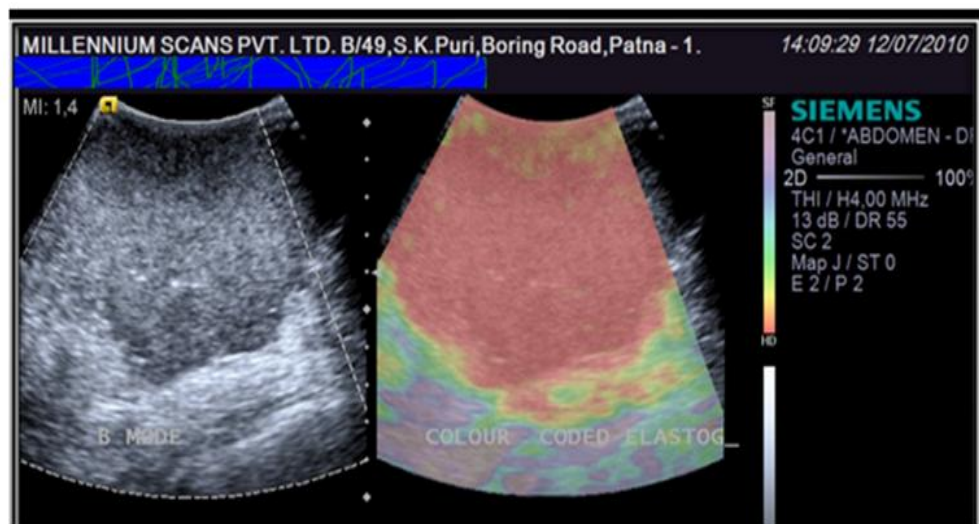

Fig V : ELASTOSONOGRAPHY OF MALIGNANT BREAST WITH COLOUR CHANGES

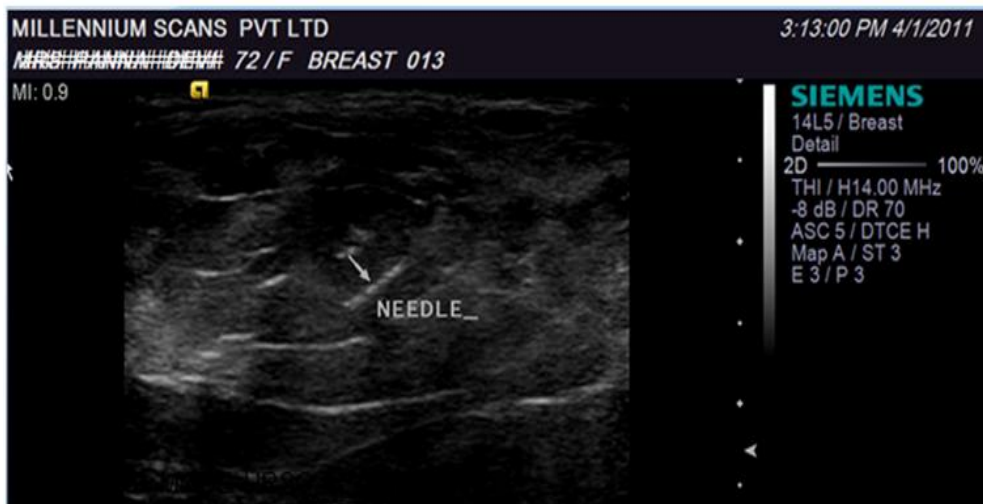


Fig VI : ELASTOSONOGRAPHY GUIDED FNAC/FNAB FROM BREAST LESION

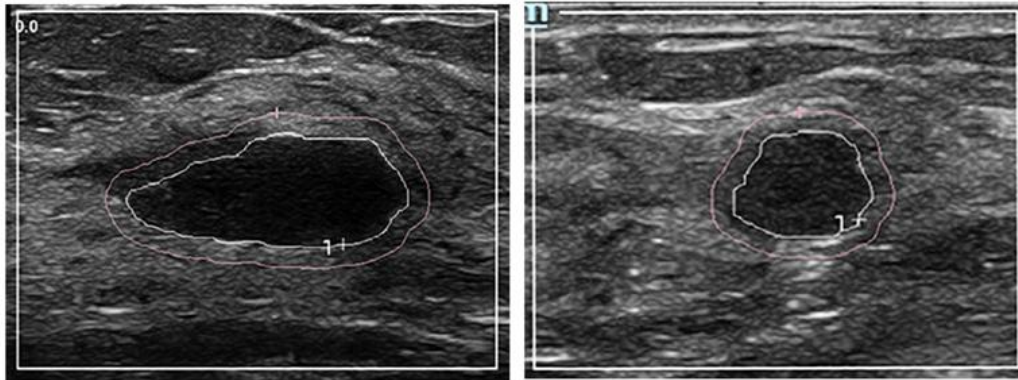


Fig VII : ELASTOSONOGRAPHY DEPECTING "STIFF RIM" SIGN IN PERITUMORAL REGION

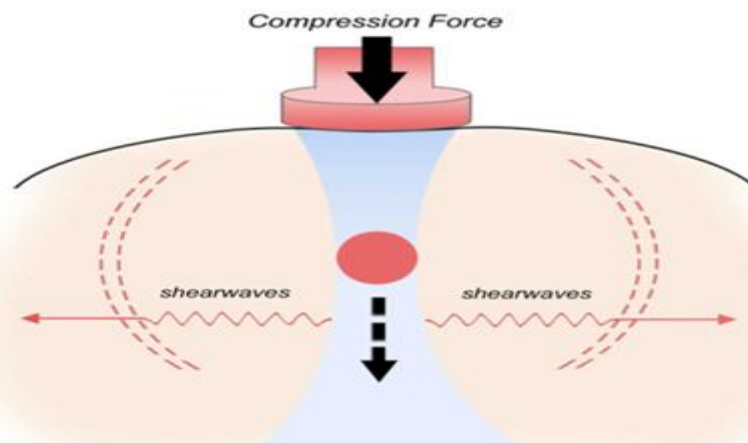


Fig VIII : BASIC PRINCIPLE OF ELASTOSONOGRAPHY

IV. Discussion and Conclusion

The elasticity pattern reflects the histology of a tumor. Most malignant breast lesions are characterized by dense interstitial fibrosis [11]. Benign lesions such as fibro adenoma show hyperplasia of the glandular epithelium cells and the stoma cells rich in mucopolysaccharides, therefore imparting a relatively loose texture [12][13]. My results are in agreement with the observations made by Krouskop et al (1998), which showed that the levels of elastic stiffness varied with different breast issue. Elastosonography involves the use of the elastic properties of malignant of benign lesions in relation to the normal glands [14]. The present findings revealed that a higher elasticity proportion was more lively to be found the benign lesions [15][16]. Elasticity score and strain ratio were the two types of elastosonography interpretation parameters analyzed in my study and strain ratio diagnostic performances was better in quantifying tissue stiffen. Elastosonography provides more evidence to diagnose small breast [17][18]. The axial strain image provides information on the dimension of the tumor with sound strain contrast which is utilized to normalize the axial shear strain features [19]. The axial-shear strain images provide information to improve the performance of breast tumor classification [20].The clinical value of elastosonography depends on its ability to minimize false negative results (Farrokh et al 2013). Based on the categories described by BI-RADS, the breast lesions unclean investigation were clarified as : Type 3 Benign ; Type 4 suspicions abnormality and category 5, highly suggestive of malignancy, elastosonography provides more evidence to diagnosing small levees lesions as shown by the higher specificity and accuracy values [21][22]. Siemens STE/STQ for shear wave elastosonography offers a new method for obtaining quantitative tissue elastic information based on the ultra-wide beam tracking impeding platform to facilitate clinical diagnosis. The usefulness of breast elastosonography has been confirmed particularly in small nodules complex cyst or cysts with a corpuscular content. Elastosonography has a significant vole in the management of modules 5mm which are visible on the us images but not on mammography [23][24].

My study had several short comings first, the study had less sample size, secondly, meticulous quantification of tissue stiffener tumor vascularity by using spectral analysis was not performed finally, performance of the elastosonography was not straight forward because multi factorial factors such as breast size, density, depth and proximity of a lesson to the nipple areola complex is difficult to assess. Elastosonography is a new technique which provide both G & S data of a lesion, the G data evaluate the lesion's

stiffness, whereas, the S data assess the outer 1 mm of the lesions. S data can help to identify the "stiff rim" sign in elastasonography.

In conclusion elastasonography is a valuable tool for early diagnosis of small breast lesions and BIRADS Type IV lesions. Elastasonography combined with conventional ultrasound may potentially increase confidence limit readily final element of breast lesions and help avoid recommendation for lesions [25].

Acknowledgment

The author acknowledges the immense help received from the scholars whose articles are cited and included in reference of this manuscript. The author is thankful to Dr. Praveen Kumar, Millennium Ultrasound and Imaging Centre Patna for his guidance and encouragement. The author is indebted to Mr. Amolak Narayan Delhi University for preparing the manuscript.

Conflict of Interest: None

Source of Funding: None

Ethical issue: None

References

- [1]. Ban K A, Godellas CV . Epidemiology of breast cancer. Surg Oncol Clin North Am 2014;23:409-422.
- [2]. Chang JM , Moon WK Cho, N Yi A Koo HR, Han W Noh DY. Moon HG, Kim SJ. Clinical Application of shear wave elastasonography (SWE) in the diagnosis of benign and malignant breast diseases. Breast Cancer Res Treat 2011;129:89-97
- [3]. Cho N, Moon WK, park JS, Cha JH, Jang M. Scong MH. Nonpalpable breast masses: Evaluation by US elastography. Korean J Radiol 2008;9:111-118.
- [4]. Cho N, Jang M, Lyoo CY , park JS, Choi HY, Moon WK> Distinguishing benign from malignant masses at breast US: Combined US elastasonography and colour Doppler US – Influence on radiologist accuracy. Radiology 2012;262:80-90.
- [5]. Cosgrave DO, Berg WA, Dore CJ, Skyba DM, Henry JP Gay J, Cohen- Bacric C. BET Study Group. Shear Wave Elastasonography for breast masses is highly reproducible. Eur Radiol 2012;22:1023-1032.
- [6]. De faria Castro Fleury E, Fleury JC, Piatto S Roveda D, Jr New elastographic classification of breast lesions during and after compression. Diagn Interv Radiol 2009;15:96-103
- [7]. De Mascarel I, Bonichon F, Durand M, Maurica L, MacGrogan G, Soubeyran I , Picot V, Avril A, Coindre JM, Trojani M. Obvious peritumoral emboli: An elusive Prognostic Factor Reappraised Multivariate analysis of 1320 node-negative breast cancers. Eur J Cancer 1998;34:58-65
- [8]. Feldmann A, Langlois C, Dewailly M, Martinez EF, Boulanger L, Kerdraon O, Faye N shear wave elastasonography (SWE): An analysis of Boulanger L, Kerdraon O, Faye N. Shear wave elastasonography: Literature review J Ultrasound Med 2012;15:192-198
- [9]. Goddi A, Bonardi M, Alessi S. Breast elastasonography: Literature review. J Ultrasound Med 2012;15:192-198.
- [10]. LLtoh A Ueno E, Tohno E, Kamma H, Takahashi H, Shiina T, Yamakawa M, Matsumura T. Breast Disease: Clinical application of US Elastasonography for diagnosis. Radiology 2006;239:341-350
- [11]. Key TJ, Verkasalo PK, Banks E. Epidemiology of Breast cancer. Lancet Oncol 2001;2:133-140.
- [12]. Leong LC< Sim LS, Lee YS, Ng FC, Wan CM, Fook-Chong SM, Jaralazaro AR. Tan PH. A Prospective study to compare the diagnostic performance of breast elastasonography versus conventional breast ultrasound Clin Radiol 2010;65:887-894.
- [13]. Mendelson EB, Bohm-Velez M, Berg W A, Whitman GJ, Feldman ML, Madjar H. ACR BI- RADS ultrasound In: ACR BI- RADS Atlas. Breast Imaging Reporting and Data System. Reston VA: American College of Radiology;2013.
- [14]. Moses LE, Shapiro D, Lirtenberg B. Combining Independent Studies Of a Diagnostic test into a summary ROC Curve: Data – Analytic Approaches and some additional consideration. Stat Med 1993;12:1293-1316.
- [15]. Saaremaa I, Salminen T, Geiger U, Heikkinen P, Hyvarinen S, Isola J, Kataja V, Kokko ML, Kokko R, Kumpulainen E, Karkkainen A, Pakkanen J, Peltonen A, Salo A, Talviala ML, Haka M. The effect of age and density of the breast on the sensitivity of breast cancer diagnostic by mammography and ultrasonography. Breast cancer Res Treat 2001;67:117-123.
- [16]. Man Houwelingen HC, Arends LR Stijnen T. Advanced Methods in meta- analysis: Multivariate approach and meta-regression. Stat Med 2002;21:589-624.
- [17]. Yi A, Cho N, Chang JM, Koo HR, La yun B, Moon WK. Sonoelastasonography For 1786 non – Palpable breast masses; Diagnostic value in the decision to biopsy. Eur Radiol 2012;22:1033-1040.
- [18]. Zhou J, Zhan W, Chang C, Zhang X, Jia Y, Dong Y, Zhou C, Sun J, Grant EG. Breast Lesion : Evaluation with shear wave elastasonography, with special emphasis on the "stiff rim" sign. Radiology 2014;272:63-72.
- [19]. Fu LN, Wang Y, et al (2011). Value of ultrasound elastasonography in detecting small breast tumors. Chin Med J, **124**, 2384-6.
- [20]. Itoh A, Ueno E, Tohno E, et al (2006). Breast disease: clinical application of US elastasonography for diagnosis. Radiology, 239, 341-50.
- [21]. Jackson VP (1995). The current role of ultrasonography in breast imaging. Radiol Clin North Am, **33**, 1161-70.
- [22]. Adamietz BR, Meier-Meitinger M, Fasching P, et al (2011). New diagnostic criteria in real-time elastasonography for the assessment of breast lesions. Ultraschall Med, **32**, 67-73.
- [23]. Cho N, Moon WK, Park JS, et al (2008). Nonpalpable breast masses: evaluation by US elastasonography. Korean J Radiol, **9**, 111-8.
- [24]. Meier-Meitinger M, Haberle L, Fasching PA, et al (2011). Assessment of breast cancer tumor size using six different methods. Eur Radiol, **21**, 1180-7.
- [25]. Zhang L, Liu YJ, Jiang SQ, et al (2014). Ultrasound utility for predicting biological behavior of invasive ductal breast cancers. Asian Pac J Cancer Prev, **15**, 8057-62.

Rajesh Narayan" Original Article: Elastasonographic Assessment of Breast Lumps" IOSR
Journal of Dental and Medical Sciences (IOSR-JDMS), vol. 18, no. 7, 2019, pp 33-37.