

Sachin's technique for axillary vein puncture/access

Dr M Bijoy, Dr Supriya Jamatia, DrTh Sachin Deba Singh, DrDilliram Sharma,
DrNyamnyeiKonyak, DrThiyamBrojendro Singh

Assistant Professor Dept of Medicine RIMS IMPHAL, Post graduate trainee Dept of Medicine RIMS IMPHAL,
Professor Dept of Cardiology RIMS IMPHAL, Post graduate trainee Dept of Medicine RIMS IMPHAL, Post
graduate trainee Dept of Medicine RIMS, Associate Professor RIMS Imphal

Abstract: Context: Axillary vein puncture is an alternative method for pacemaker leads implantation, intracardiac defibrillator, central line insertion. However, the safety and effectiveness of axillary vein puncture become an issue for debate now. Aims: The aim of this study was to investigate the safety, feasibility, and efficacy of a modified axillary vein technique for pacemaker implantation, intracardiac defibrillator, central line insertion. Settings and Design: This axillary vein technique refers to a axillary vein puncture method using fluoroscopy for landmarking axillary vein. Subjects and Methods: This technique was applied to 50 patients in whom cephalic vein cut down was failed referred for pacemaker implantation, intracardiac defibrillator implantation, between 2009, and 2018, at cardiology department RIMS IMPHAL. Statistical Analysis Used: None. Results: Success rate of pacemaker implantation was 96% (48/50). Two patients were switched to an alternate approach for leads implantation. There were no procedure-related complications such as pneumothorax, hemothorax, major bleeding, and significant pocket hematoma. Conclusion: This axillary vein puncture technique under fluoroscopy guidance is safe and feasible for pacemaker implantation, intracardiac defibrillator implantation, central line insertion.

Keywords: Axillary vein, fluoroscopy, pacemaker implantation, intracardiac defibrillator implantation, central line insertion

Date of Submission: 26-07-2019

Date of Acceptance: 12-08-2019

I. Introduction

Subclavian vein is a common clinical practice for the venous access in pacemaker implantation, intracardiac defibrillator, central line insertion. However, this technique is associated with potentially severe complications including pneumothorax, hemothorax, brachial plexus injury, and subclavian crush syndrome, which will lead to bad clinical consequences. The cephalic vein is another common access for pacemaker implantation, but this vein is too small and not suitable for multiple leads insertion and implantable cardioverter-defibrillator implantation. The femoral vein was also adopted in recent trials for leadless pacemaker. Axillary venous access is an ideal alternative strategy for pacemaker implantation. In 1999, Belott proposed a blind axillary vein puncture technique with a high success rate using anatomic landmarks. Nonetheless, in the initial Belott's method, the needle tip was aimed downward, toward the lung, which would potentially increase the risk of pneumothorax. In the year of 2006, Belott introduced a modified method of axillary vein access relying on superficial anatomy and fluoroscopy of the first rib.

II. Subjects And Methods

Patient in whom cephalic vein cut down technique was unsuccessful in that patient venous access done by Axillary puncture technique. In this technique first Terumo guide wire inserted through basilic vein. The puncture site was set at about 1–2 cm away from coracoid process (CP) on the assumed line. Under aseptic precaution local anesthesia given with lidocaine. Under fluoroscopy guidance axillary vein puncture by Seldinger 18G needle almost vertically & parallel to wire, with specific caution not to cross the rib margin medially. After puncturing Axillary vein a flexible J tip guide wire is advanced through the lumen of the needle and the needle is withdrawn. A sheath can now be passed over the guidewire in the vessel then guidewire is withdrawn. By withdrawn and suction method we will see blood is coming or not. By seeing color of blood and pulsation we can differentiate sheath is inside artery or vein. When basilic vein is not available we can use femoral vein to localize Axillary vein. Now we can introduce wire inside the sheath. When the wire was advanced into the inferior vena cava under the guidance of anterior–posterior fluoroscopy, an incision (about 4 cm) was made horizontally from the puncture site toward the sternum pacemaker after repeated local anesthesia to create the pocket for pacemaker.

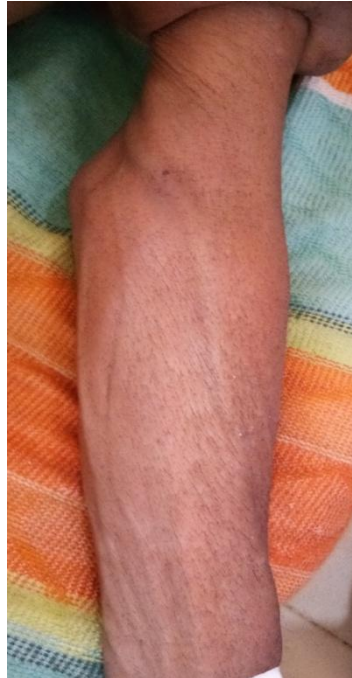

Figure: showing basilic vein

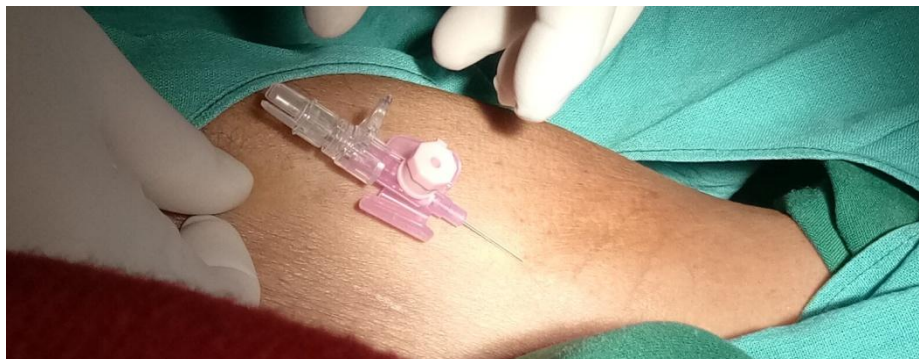


Figure: showing basilic vein puncture

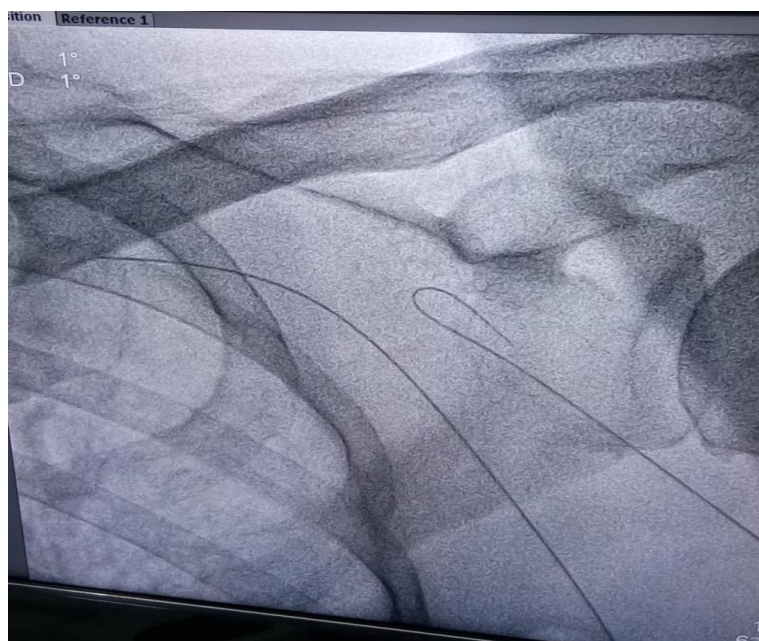

Figure : showing terumo wire in axillary vein near to rib margin and cephalic vein near to corocoid process

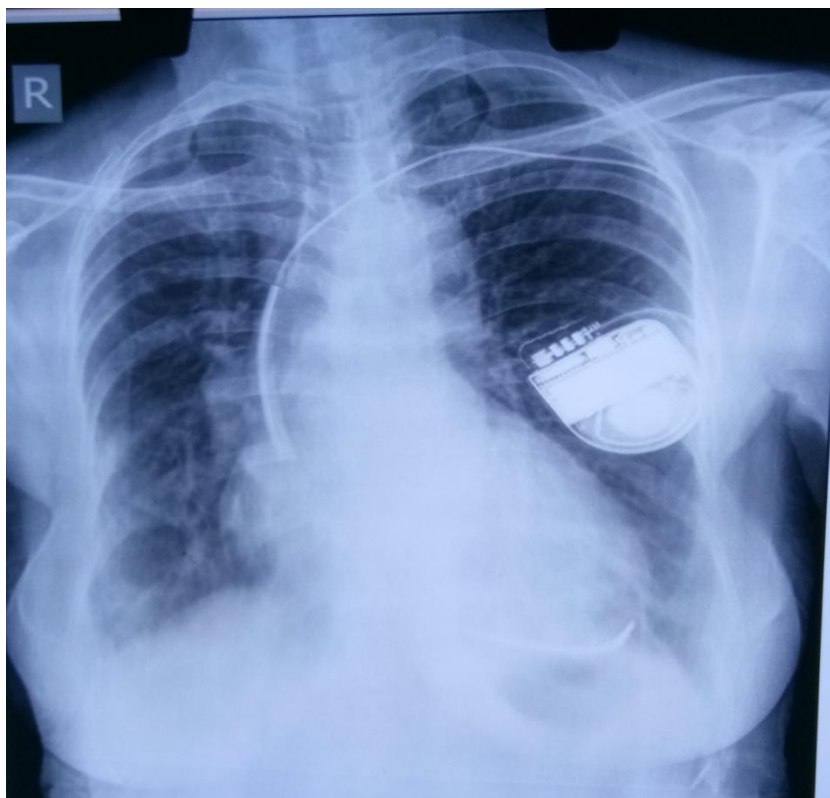


Figure : showing pacemaker lead in left axillary vein connected with pacemaker battery

III. Result

On 50 patient in whom conventional way of cephalic vein cutdown technique failed sachin's technique of axillary vein access performed. Among 50 patient 2 failed one failed as terumo wire could not be inserted as punctured failed and another one terumo wire was inside axillary vein but could not access because of anatomic thoracic kyphosis. Once the venous access was obtained, pacemaker lead or defibrillator leads were successfully placed via axillary vein. The patient were watched for immediate complication clinically and radiographically and none of the patient had pneumothorax or hemothorax as immediate complication.

IV. Discussion

Others operator have published different techniques to mark axillary vein but we are using fluoroscopy along with terumo wire to demarcate axillary vein. This method prevent excessive bleeding at the puncture site, less chance of injury to rib cage as it is under direct visualisation also less chance of pneumothorax. It can also use as central line catheterisation.

Venous access is one of the most important steps in device implementation. Subclavian vein access is associated with short and long term complication like pneumothorax or hemothorax and subclavian crush syndrome leading to lead fracture.

Our study shows limited immediate complication with 96% success rate after excluding failures due to anatomical abnormalities

Limitation of this study is retrospective observational study, and no direct comparison with other traditional methods.

Technical consideration:

Technical limitations This is our primary attempt for the axillary vein puncture using this new technique. The average time spent in the puncture is slightly longer than a conventionally used method such as subclavical vein approach. Since X-ray is incorporated in this procedure, the fluoroscopic time is slightly longer in this newly introduced strategy. We hope, in the future, when we are more skillful in this method, these disadvantages could be reduced to a minimum.

V. Conclusion

Our study results indicate that Sachin's method is a simple and effective method and less cumbersome newer technique to the other many techniques described for axillary vein puncture in literature. It can be used in implementation of pacemaker or defibrillator device with single or multiple leads, and for central line. Patients names and initials will not be published and due efforts will be made to conceal their identity, but anonymity cannot be guaranteed.

Acknowledgments: Dr Sachin Deba Singh

Financial support and sponsorship: Nil

Conflicts of interest: There are no conflicts of interest

References

- [1]. Migliore F, Curnis A, Bertaglia E. Axillary vein technique for pacemaker and implantable defibrillator leads implantation: a safe and alternative approach? *J Cardiovasc Med (Hagerstown)*. 17(4)2016:309-13.
- [2]. Migliore F, Siciliano M, De Lazzari M, et al. Axillary vein puncture using fluoroscopic landmarks: a safe and effective approach for implantable cardioverter defibrillator leads. *J Interv Card Electrophysiol*. 43(3)2015:263-7.
- [3]. Fabien S, Julien T, Didier S, et al. Self-taught Axillary vein access without venography for pacemaker implantation: prospective randomized comparison with cephalic vein access. *European society of cardiology*. 17:2017:2001-2006
- [4]. Hui Y, Hejun J, Qiming L, et al. Safety and efficacy of a Modified Axillary Vein Technique for Pacemaker implantation. *Cardiol Plus* 2028;3:104-7.
- [5]. Ashis K Khanna. Axillary vein cannulation for central access: A newer look below the clavicle! *J Anaesthesiol Clin Pharmacol*. 2017; 33(3): 289-290.
- [6]. Hettiarachchi E, Arsene C, Fares S, et al. Fluoroscopy-Guided Axillary Vein Puncture, a reliable Method to prevent acute complications associated with pacemaker, defibrillator, and cardiac resynchronization therapy lead insertion. *J Cardiovasc Dis Diagn*. 2023;2:136.
- [7]. Felix Y, Guy K. A new trick to a routine procedure: taking the fear out of the Axillary vein stick using the 35 degree caudal view. *European society of cardiology*. 2015(17), 1157-1160.
- [8]. Furman S, Schwedel JB. An intrathoracic pacemaker for Stokes-Adams seizure. *N Engl J Med* 1959;261:943-8.
- [9]. Belott PH. Blind Axillary venous access. *Pacing Clin Electrophysiol* 1999;22:1085.
- [10]. Sharma G, Senguttuvan NB, Thachil A, et al. A comparison of lead placement through the subclavian vein technique with fluoroscopy-guided axillary vein technique for permanent pacemaker insertion. *Can J Cardiol* 2012;28:542-6.
- [11]. A. Bodenham, M. Lamerti, Ultrasound guided infraclavicular Axillary vein cannulation, coming of age, *BJA: British Journal of Anaesthesia*, Volume 116, Issue 3, March 2016, Pages 325-327.

Dr Supriya Jamatia. "Sachin's technique for axillary vein puncture/access." *IOSR Journal of Dental and Medical Sciences (IOSR-JDMS)*, vol. 18, no. 8, 2019, pp 09-12.