

“Nifedipine Induced Gingival Hyperplasia”

Dr. Verdine Virginia Antony¹, Dr. Rahamathulla Khan²

Dr. Nureldeen Elhammali³

(Department of Periodontics & Implantology, Dental faculty, Sirte University, Libya.)¹

(Department of Orthodontics & Dentofacial Orthopedics, Dental Faculty, Sirte University, Libya.)²

(Department of Oral & Maxillofacial Surgery, Dental Faculty, Sirte University, Libya.)³

Abstract: *Gingival hyperplasia modified by medications are commonly seen in dental practice. The increased use of drugs systemically induce several alterations in micro and macroscopic tissues and may create speech, mastication, periodontal, and aesthetic problems. Many systemic diseases have limited therapeutic options and such drugs have an adverse influence on different systems, and one of these is that they initiate the overgrowth of gingival tissue. In the presence of bacterial inflammation in the gingiva, many of these drugs enhance the production of collagen by fibroblast cells, and simultaneously retard the destruction of collagen and hence increase the bulk of gingival tissue. The exuberant growth of gingival tissue is of great aesthetic concern, which may require mechanical removal of bacterial plaque, calculus, and surgical intervention, and/or substitution of the drug with analogs. Physicians and dentists need to make a coordinated treatment approach that will be beneficial for the patients. Here, we present a case of nifedipine-induced gingival hyperplasia and draw the attention of clinicians.*

Keywords: *Hyperplasia, drug, collagen, fibroblast, Nifedipine.*

Date of Submission: 26-07-2019

Date of Acceptance: 12-08-2019

I. Introduction

Gingival enlargement is a clinical representation of gingival or periodontal diseases. Gingival hyperplasia is a common finding in a routine dental practice. An increasing number of patients are being treated with multiple medications; some of these medications have an adverse reaction on the mouth and periodontal tissues. One of the unwanted side effects of these drugs is gingival hyperplasia [1]. Immunosuppressant drugs, antiepileptics, corticosteroids, non-steroidal anti-inflammatory drugs and calcium channel blockers can cause gingival hyperplasia [2]. It is a histomorphological alteration due to the side effects of a medication on the extracellular matrix [3]

Nifedipine is one of the most common antihypertensive drugs (calcium channel blockers) used to treat hypertension and some forms of angina [4]. Among calcium antagonists, it is the drug most commonly related to drug-induced gingival hyperplasia. Nifedipine induced gingival hyperplasia was first reported in 1984; trials showed that prevalence varied between 14% and 83% [5].

I.1 PHARMACOPATHOGENESIS

The possible hypothesis to explain this overgrowth is that the fibroblasts contain strongly sulphated mucopolysaccharides that are precursors of ground substance. After an interaction between nifedipine and gingival fibroblasts, overproduction of collagen and extracellular ground substance occurs and leads to an increase in the size of the gingiva. The drug interferes with the calcium metabolism of fibroblast cells and hence reduces the production of the degrading enzyme collagenase. It has been suggested that there may be subpopulations of fibroblasts which are sensitive to nifedipine and cause an increase in the production of collagen. [6]

Various factors are attributed for the overgrowth of gingiva in nifedipine-induced hyperplasia, which include high plaque index (poor oral hygiene), high dose of the drug, genetic factors, individual susceptibility, and interaction between drugs and metabolites with the fibroblasts of gingiva. [7]

I.2 MANAGEMENT

Gingival overgrowth caused by nifedipine decreases following the withdrawal of the drug. Exacerbation occurs when the drug is reintroduced and decreases the second time [8] with the withdrawal of the drug. The dosage of nifedipine has no correlation with gingival enlargement. Control of bacterial plaque may lead to the resolution of inflammation, but the enlargement does not completely regress. Excision of gingival overgrowth becomes mandatory to overcome aesthetic concerns.

Here, we present a case with gingival hyperplasia in two quadrants where few teeth are present, while the other quadrants which were edentulous showed no changes, an overlooked adverse effect of nifedipine.

II. Case Report

A 60-year-old female patient reported to the Department of Periodontology, with a complaint of swollen gums. On intraoral examination, generalized gingival enlargement was noticed in the upper arch in relation to 21, 22 and 23, whereas an isolated nodular growth was observed in the right side of lower arch in relation to 43. The enlarged gingiva was firm, pale pink, and resilient with a minutely lobulated surface and displayed no tendency to bleed (Figure 1- a, b). Assessment of plaque accumulation was done using Silness and Loe plaque index (1964) which gave in a score of 3 (marking abundance of soft matter within the gingival pocket and/or on the tooth and gingival margin). Assessment of gingival inflammation was made using gingival index of Silness and Loe (1963), which gave a score of 1 (which includes mild inflammation, slight change in colour, slight edema, and no bleeding on palpation). The gingival hyperplasia was graded by using Angelopoulos and Goaz (1972) criteria, which was graded as grade I (which presents with hyperplastic gingiva extending to the cervical third or less of the anatomic crown). The medical history of the patient revealed that she was hypertensive and was taking Tab. Nifedipine 30 mg BID and Tab. Atorvastatin 20 mg once in a day; for the past three years, as prescribed by her physician. History of the presenting illness revealed that the patient noticed the swelling which started 2 years ago and progressed to the present stage. Based on the clinical presentation of the gingival enlargement and the history of nifedipine intake, the case was diagnosed as Nifedipine induced gingival overgrowth.

Periodontal management consisted of performing thorough oral prophylaxis followed by careful instructions on oral hygiene procedures and surgical intervention if needed. The case was reviewed for any signs of improvement after a period of 2 weeks. Since there were no changes noticed, a referral was made to the patient's physician to consider drug substitution with respect to nifedipine. Nifedipine was substituted with Tab. Captopril 50 mg BID by the physician and the patient was re-evaluated after 2 months. The bulk of the gingival enlargement had subsided in the upper arch and the isolated nodular growth in the lower arch had also reduced in size.

The patient received periodontal therapy and oral hygiene instruction sessions. After two months, the patient underwent surgical therapy consisting of gingivectomy in relation to 21, 22 and 23. After anesthetizing the area, sounding of the underlying alveolar bone was performed with a periodontal probe to determine the thickness of the gingival biotype and amount of tissue to be removed. An excisional biopsy of the gingiva was performed with a #15 surgical blade, the specimen including gingival epithelium and connective tissue was excised and stored immediately in formalin solution for further histopathological examination. Subsequently, the periodontal pockets on each surface were explored with a periodontal probe and marked with a pocket marker. Kirkland periodontal knives were used for incisions on the facial and lingual surfaces. Orban periodontal knives were used for interdental incisions. The external bevel incisions were started apical to the points marking the course of the pockets and were directed coronally to a point between the base of the pocket and the tooth without exposing the alveolar bone. The underlying surface was thoroughly curetted up to deepest possible tissue. Periodontal dressing was placed. The patient was discharged with a prescription of antibiotics, analgesics and chlorhexidine mouth wash and was recalled after one week for a follow up. The one week follow up was uneventful with the surgical site showing signs of healing. The tissue was sent for histopathologic analysis. The histopathology showed hyperplastic epithelium with dense collagen fibres and chronic inflammatory cells in the connective tissue. (Figure 2). A six month postsurgical follow-up of the patient showed no evidence of recurrence.

III. Discussion

The pathogenesis of drug-induced gingival overgrowths is still not completely understood. It has been demonstrated that gingival enlargement has a multifactorial nature and is affected by factors such as age, demographic variables, genetic predisposition, oral hygiene status, pharmacokinetic variables, and molecular and cellular changes in gingival tissues

Gingival enlargement due to drugs like nifedipine has various untenable causes. There are various theories postulated in the pathogenesis of gingival enlargement due to nifedipine. Among the antihypertensives, nifedipine showed higher prevalence of gingival enlargement. [7] It starts as an enlargement of interdental papilla and later turns into a lobulated mass or nodules. It may also extend over the crown and reach occlusal heights, thereby interfering with mastication. These growths may aggravate the plaque accumulation and an increase in pocket depth formation, which adds to the problem.

Numerous factors have attributed for the overgrowth of gingiva in nifedipine-induced hyperplasia, which include high plaque index (poor oral hygiene), high dose of the drug, genetic factors, individual susceptibility, and interaction between drugs and metabolites with the fibroblasts of gingiva [4]. Other factors

like increased production of heparin sulfate glycosaminoglycan (HSPG), basic fibroblast growth factor (bFGF), and transforming growth factor-beta (TGF-β) were found to be increased in nifedipine- and phenytoin-induced gingival hyperplasia.[5]

Calcium antagonists like nifedipine block the influx of calcium ions, thereby affecting homeostasis of collagen. The synthesis and degradation of the collagen being altered lead to the abnormal growth.[7] With these factors, an ambiguity exists among different researchers in the pathogenesis and progression of gingival enlargement in nifedipine.

Nifedipine and atorvastatin are metabolized by the same enzyme, Cytochrome P4503A4 [9]. In our case, concomitant use of nifedipine and atorvastatin may have decreased the metabolism of nifedipine and lead to elevated serum nifedipine levels, which may have increase the risk of developing gingival hyperplasia.

Drug induced gingival hyperplasia usually regresses after nifedipine is stopped. Regression may take a few months. Rigorous oral hygiene including scaling, gingival massage, and antiseptic washings to control plaque are thought to be an essential part of the management to prevent recurrence. Gingivectomy is sometimes required [8].

Our case showed gingival enlargement where teeth were present. Obviously, the teeth with high plaque index were a key factor in the pathogenesis and progression of the disease in our case. In correlation with this, the edentulous areas did not show any enlargement, which proves that plaque is an essential factor in gingival enlargement due to nifedipine[10].The histopathology of our patient showed increased plasma cells and the other chronic inflammatory cells, proving plaque to have an inflammatory effect on gingiva resulting in gingival enlargement [11].

The dose of the drug also has an impact on gingival overgrowth. It is reported that nifedipine was found 15–316 times more in the gingival crevicular fluid compared to plasma [12]. The higher concentration of nifedipine in the gingival crevicular fluid could increase the severity of gingival enlargement. [12] Consideration should be given to the possibility of discontinuing the drug or of changing the medication. These possibilities should be consulted with the patient’s physician. Simple discontinuation of the offending agent is usually not a practical option but replacing it with another medication should be done as was done in our case Nifedipine was substituted with Captopril. Reduction in the size of the gingival overgrowth has been reported within a week of drug withdrawal and may lead to full resolution [9]. If any drug substitution is attempted, it is important to allow for 6–12 months to elapse between discontinuation of the offending drug and the possible resolution of gingival enlargement before a decision to implement surgical treatment is made [11].

It was obvious from our case that poor oral hygiene along with drug dose can increase the gingival growth. Patients with nifedipine therapy need prophylaxis at least once in 3 months and also should have meticulous plaque control measures [13] it was also proved that increased drug dosage showed increased gingival enlargement, so the physician can consider altering the dose of nifedipine or combine it with other antihypertensive [14].

IV. Conclusion

There is a need for physicians and dentists to make a coordinated treatment plan for the patients indicated for these drug therapies.

References

- [1]. Miranda J, Brunet L, Roset P, Berini L, Farre M, Mendieta C, Prevalence and risk of gingival enlargement in patients treated with nifedipine J Periodontol 2001 72(5):605-11. [Google Scholar]
- [2]. Lucas RM, Howell LP, Wall BA. Nifedipine-induced gingival hyperplasia a histochemical and ultrastructural study. J Periodontol 1985;56:211-5.
- [3]. Kataoka M, Kido J, Shinohara Y, Nagata T. Drug-induced gingival overgrowth: A review. Biol Pharm Bull 2005;28:1817-21.
- [4]. Hallmon WW, Rossmann JA. The role of drugs in the pathogenesis of gingival overgrowth. A collective review of current concepts Periodontol 2000 1999 21:176-96. [Google Scholar]
- [5]. Y. Ramon, S. Behar, Y. Kishon, and I. S. Engelberg, “Gingival hyperplasia caused by nifedipine—a preliminary report,” International Journal of Cardiology, vol. 5, no. 2, pp. 195–206, 1984. View at Publisher · View at Google Scholar · View at Scopus
- [6]. Brown RS, Beaver WT, Bottomley WY. On the mechanism of drug-induced gingival hyperplasia. J Oral Pathol Med 1991;20:201-9.
- [7]. M. Mavrogiannis, J. S. Ellis, J. M. Thomason, and R. A. Seymour, “The management of drug-induced gingival overgrowth,” Journal of Clinical Periodontology, vol. 33, no. 6, pp. 434–439, 2006. View at Publisher · View at Google Scholar · View at Scopus
- [8]. Haytac CM, Ustun Y, Essen E, Ozelik O, Combined treatment approach of gingivectomy and CO2 laser for cyclosporine-induced gingival overgrowth Quintessence Int 2007 38(1):e54-59. [Google Scholar]
- [9]. P. G. Raman, V. N. Mishra, and D. Singh, “Nifedipine induced gingival hyperplasia,” The Journal of the Association of Physicians of India, vol. 36, no. 3, pp. 231–233, 1988. View at Google Scholar · View at Scopus
- [10]. Hancock RH, Swan PH. Nifedipine- induced gingival over growth - Report of a case treated by controlling plaque. J ClinPeriodontol. 1992;19:12–4.[PubMed]
- [11]. Ilgenli T, Atilla G, Baylas H, Effectiveness of periodontal therapy in patients with drug-induced gingival overgrowth. Long-term results J Periodontol 1999 70(9):967-72. [Google Scholar]
- [12]. Ellis JS, Monkman SC, Seymour RA, Idle JR. Determination of Nifedipine in gingival crevicular fluid: A capillary gas chromatographic method for Nifedipine in microlitre volumes of biological fluid. J Chromatogr. 1993;621:95–101.[PubMed]

- [13]. P. M. Sunil, J. S. Nalluswami, S. J. Sanghar, and I. Joseph, “Nifedipine-induced gingival enlargement: correlation with dose and oral hygiene,” *Journal of Pharmacy and Bioallied Sciences*, vol. 4, no. 6, pp. 191–193, 2012. View at Publisher · View at Google Scholar · View at Scopus
- [14]. Eslami M, Baghahi F, JalayerNadery N. An Investigation on gingival hyperplasia induced by nifedipine. *J Dent (Tehran)* 2004;1:33–7.

LEGENDS FOR FIGURES

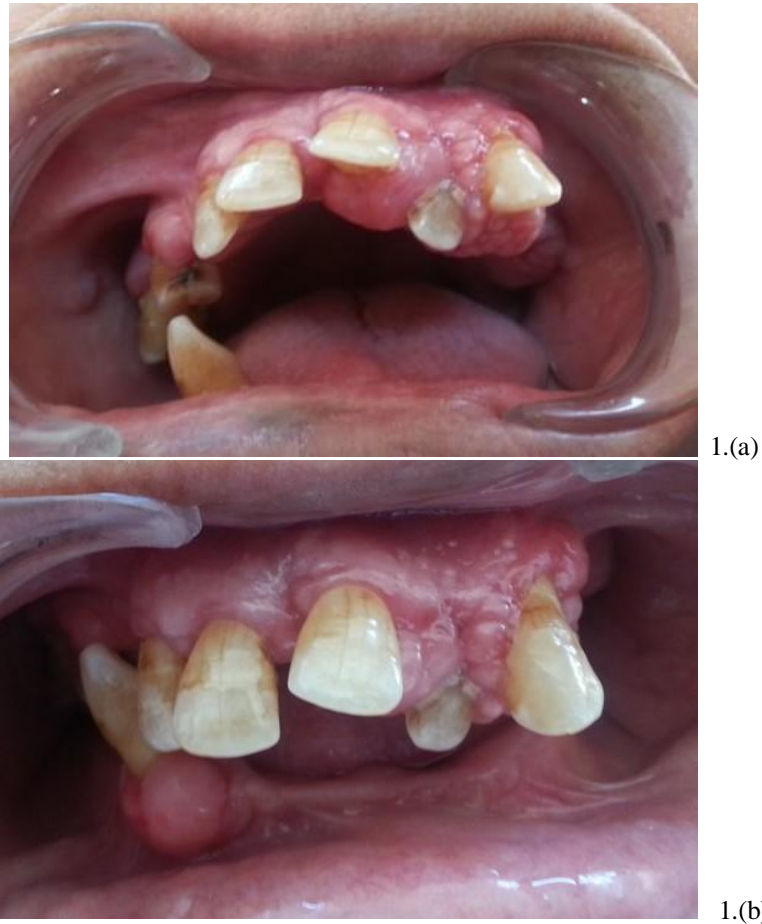

Figure 1:Clinical image Pre-operative

- a. Gingival enlargement in relation to 21,22 and 23 with surface being lobulated.
- b. Isolated nodular enlargement in relation to 43

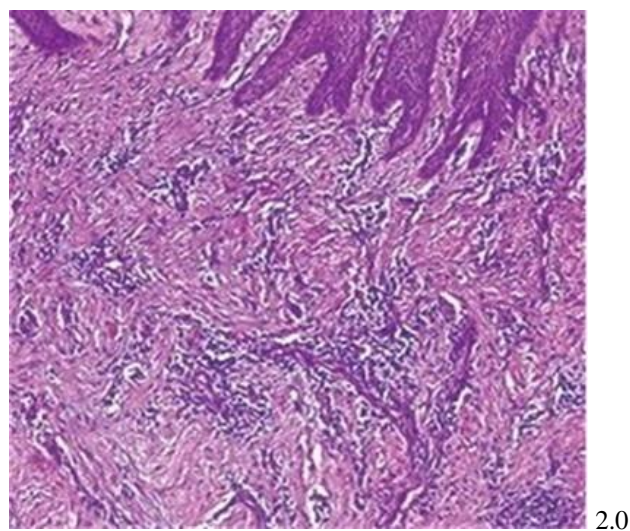


Figure 2:Histopathology showing hyperplastic epithelium with dense collagen fibres and chronic inflammatory cells in the connective tissue.