

## Analysis of Red Cell Histograms.

Dr. Prasanthi Cherukuri<sup>1</sup>, Dr. Vasundara Gardas<sup>2</sup>, Dr. Sanjana Nutakki<sup>3</sup>,  
Dr. K. V. Murali Mohan<sup>4</sup>

<sup>1</sup>Associate Professor, Department of pathology, Gitam institute of medical sciences and research,  
Visakhapatnam, India.

<sup>2</sup>Assistant professor Department of pathology, Gitam institute of medical sciences and research,  
Visakhapatnam, India.

<sup>3</sup>Assistant professor Department of pathology, Gitam institute of medical sciences and research,

<sup>4</sup>Professor, Head of the department, Department of pathology, Gitam institute of medical sciences and  
research.

Corresponding Author: Dr. Vasundara Gardas

---

Date of Submission: 23-08-2019

Date of Acceptance: 07-09-2019

---

### I. Introduction

Red blood cell histogram is an integral part of automated analysis which in association with red blood cell indices, hematocrit and red blood cell distribution width provides major clues in the diagnosis and management of red cell disorders<sup>4</sup>. Histograms are graphic representation of cell frequencies verses size<sup>5</sup>.

Owing to the fact that manual microscopic examination of the blood smear is subjective, time consuming and quite misleading impressions can be drawn from inadequately prepared smears, during the past three decades, a number of automated hematology analyzers have been developed; most of which directly measure two RBCs parameters, RBCs count and mean corpuscular volume (MCV)<sup>9</sup>. Complete blood count parameters like red cell distribution width (RDW) and mean corpuscular volume (MCV) are useful along with histogram for interpretation of abnormal red blood cell morphology.<sup>1</sup>

The red blood cell histogram is a symmetrical bell shaped curve. The area of the peak is used to calculate the mean corpuscular volume and red cell distribution width. This area represents 60fl to 125fl. The narrow red cell distribution curve indicates homogenous population of cells and wider red cell distribution curve indicates a heterogenous population of red cells. If the red blood cells are larger than normal (macrocytic), the curve will shift towards right. If the red blood cells are smaller than normal (microcytic), the curve will shift towards left. After treatment of underlying cause in anemia, the curve should shift toward the normal range. If the histogram is bimodal, then there are two populations of red blood cells as might be seen when a patient received a blood transfusion, hemolytic anemia with presence of schistocytes, or anemias with different size cell populations. Interpretation of RBC histogram along with the numerical values of RBC count, hemoglobin, hematocrit, mean corpuscular hemoglobin, mean corpuscular hemoglobin concentration, and red cell distribution width can significantly assist in the diagnosis of various RBC disorders avoiding many expensive an invasive investigations.

### Aims and objectives

Analysis of RBC histograms in various cases of anemia.

### II. Materials and Methods

The data of 159 samples has been taken in the month of April 2019, central laboratory, Gitam institute of medical sciences and research, Visakhapatnam, Andhrapradesh, India. Blood sample was collected from 159 anemia patients in ethylene diamine tetra acetic acid (EDTA) tubes for peripheral smear examination and run in Cell- Dyn (Abott ) automated hematology analyzer for obtaining histogram, complete blood count includes hemoglobin, total leucocyte count, Platelet count, red blood cell indices and red cell distribution width. In this retrospective study, The red blood cell histograms of all anemic patients visiting the central diagnostic laboratory of GIMSR were analyzed. The red blood cell histogram correlated with peripheral smear interpretation. The spectrum of variations in Red blood cell histograms tabulated with types of anemias based on peripheral smear interpretation.

Inclusion Criteria: All cases of anemia with low haemoglobin. For men anemia is defined as haemoglobin level less than 13.5 gm/100ml and in women as haemoglobin of less than 12.0 gm/100ml.

Exclusion Criteria: Patient having leukocytosis, parasites, leukemoid reaction, leukaemia, and platelet disorders.

**III. Results**

In our study of histograms of various types of anemia, out of the 159 cases studied females were 104(65.4%) and males were 55(34.5%). Maximum number of anemia cases were noted in the age group 30 to 60 yrs. All the cases who had hemoglobin less than 12gm were taken and categorized into normocytic, microcytic, macrocytic, dimorphic and pancytopenia. In our study microcytic anemia was seen in 95 (59.7%), normocytic anemia in 60 (37.7%), dimorphic anemia in 18( 11.3%), macrocytic anemia in 1(0.6%), pancytopenia in 2 cases(1.25%).(Table-1)

For these 159 samples histograms showed a left shift for 79 cases (49.6%), short peak in 74 cases (46.5%), bimodal peak in 11 cases (6.9%), broad base and normal curve in 5 cases (3.1%), right shift is seen in 2 cases (1.25%).(Table-2)

Out of 95 (59.7%) cases of microcytic hypochromic anemia, 68 (71.5%) cases showed left shift, 22 (23.1%) cases showed short peak 3 (3.1%) cases showed broad peak, one case showed normal curve and another showed bimodal peak. Out of 60 (37.7%)cases of normocytic normochromic anemia, 44 (73.3%) cases showed short peak, 9 (15%) cases showed left shift, 4 (6.6%) cases showed normal curve, rest three cases showed right shift, broad base and bimodal curve. Out of 18 (11.3%) cases dimorphic anemia, 8 (44.5%) cases showed bimodal peak, 7 (38.8%) cases showed short peak, 2 cases showed left peak and one case showed broad base. Pancytopenia is seen in two cases, one with short peak and the other with bimodal peak. Macrocytic anemia is seen in one case with right shift. (Table-3)

**Table 1:** Distribution of cases per types of anemia

Types of anemia	No of cases (Percentage)
Microcytic hypochromic	95 (59.7)
Normocytic normochromic	60 (37.7)
Dimorphic	18(11.3)
Macrocytic	1(0.6)
Pancytopenia	2(1.25)

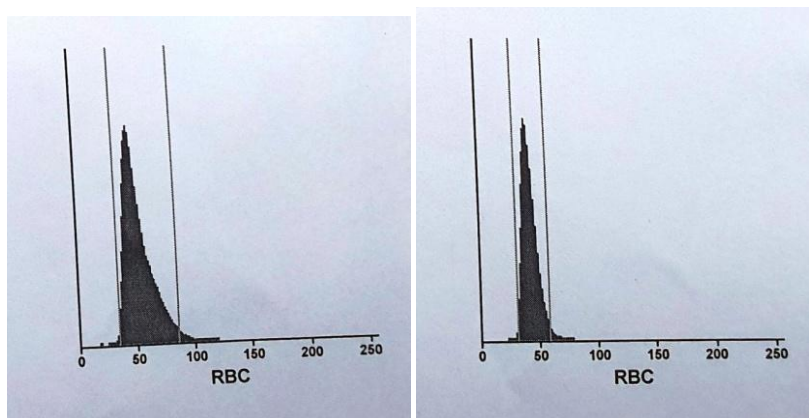
**Table 2 :** Types of histogram abnormality in the study

Type of histogram	No of cases (Percentage)
Normal curve	5( 3.1% )
Left shift	79(49.6%)
Right shift	2(1.25%)
Broad base	5 (3.1%)
Short peak	74(46.5)
Bimodal peak	11(6.9%)

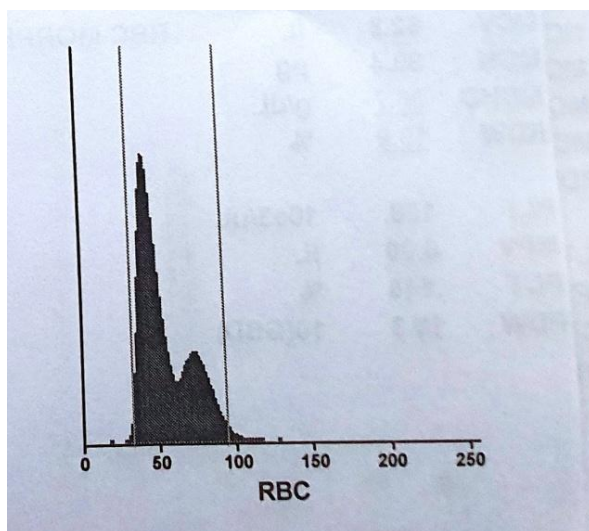
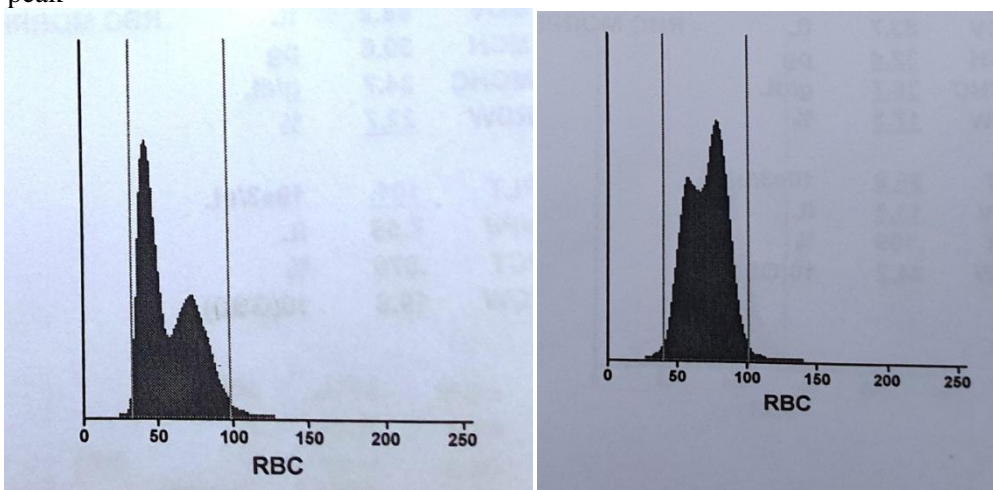
**Table 3:** Red blood cell histogram variations in different types of anemia

	Normal curve	Left shift	Right shift	Broad base	Short peak	Bimodal
Normocytic	4(6.6)	9(15)	1(1.6)	1(1.6)	44(73.3)	1(1.6)
Microcytic	1(1.05)	68(71.5)		3(3.1)	22(23.1)	1(1.05)
Macrocytic			1 (100)			
Dimorphic		2(11.1)		1(5.5)	7(38.8)	8(44.4)
Pancytopenia					1(50)	1 (50)
	5	79	2	5	74	11

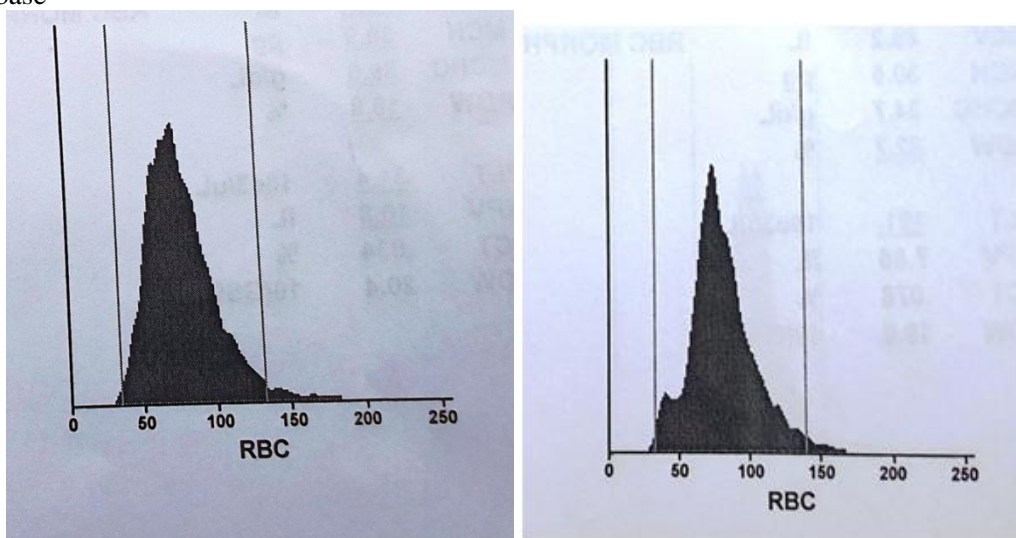
Left shift



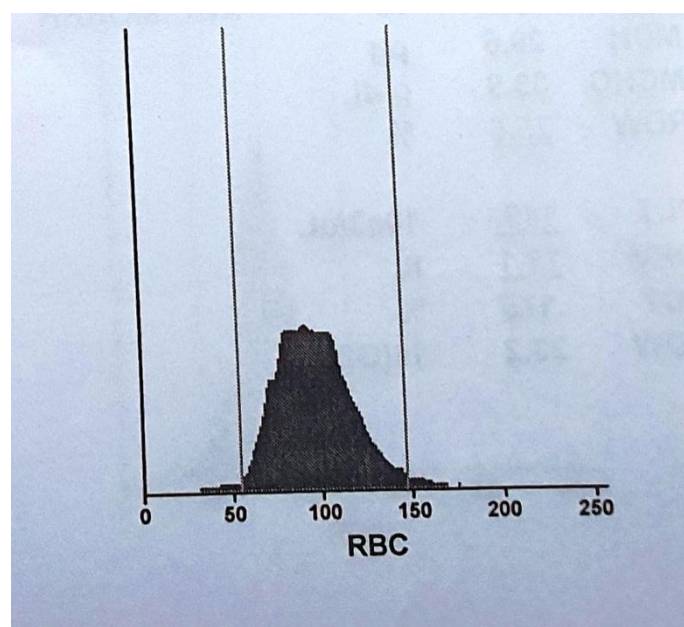
Bimodal peak



Broad base



Short peak



#### IV. Discussion

Red blood cell histogram are graphic representations of blood cells produced from thousands/millions of signals generated by the cells passing through the detector where they are differentiated by their size and frequency of occurrence in the population. Using the electrical impedance principle of counting cells, the cells are sized and counted by detecting and measuring changes in the electrical resistance when a particle passes through a small aperture. The number of pulses generated during a specific period of time is proportional to the number of particles or cells. The amplitude of the electrical pulse produced indicates the cells volume. Each pulse on the X-axis represents size in femtolitres(fl). The Y-axis represents the relative number of cells. Homogenous population of red blood cell give narrow distribution curve while if more anisopoikilocytosis, then curve will be broad<sup>7</sup>. The curve is said to be symmetric if both sides of the curve coincide when folded in half or are mirror images to one another<sup>4</sup>.

Out of the 159 cases studied females were 104 (65.4%) and males were 55 (34.5%). The female: male ratio is 1.8:1. Maximum number of anemia cases were noted in the age group 30 to 60 yrs. All the cases who had hemoglobin less than 12gm/dl were taken and categorized into normocytic, microcytic, macrocytic, dimorphic and pancytopenia.

In our study microcytic anemia was found to more predominant constituting to 95 (59.7%) cases next in frequency is normocytic anemia in 60 (37.7%) cases, dimorphic anemia in 18 ( 11.3%) cases, macrocytic anemia in 1(0.6%) case, pancytopenia in 2 cases(1.25%). This correlated well with other studies by sandhya et al<sup>6</sup>, Jitendra chavda et al<sup>7</sup>, and byna syam sundara rao et al<sup>8</sup>. For these 159 samples histograms showed a left shift for 79 cases (49.6%), short peak in 74 cases(46.5%), bimodal peak in 11 cases(6.9%), broad base and normal curve in 5 cases (3.1%), right shift is seen in 2 cases(1.25%). Other studies by Sandhya et al<sup>6</sup>, Jitendra chavda et al<sup>7</sup>, and Byna syam sundara rao et al<sup>8</sup> showed mostly broad base and left shift curves. Most of the anemic patients in our study were inpatients of the nephrology ward hence most of the cases were of normocytic normochromic anemia mostly seen in the older age group where the indices showed a decrease in red blood cell count with a normal MCV, MCH, MCHC.

Out of 95(59.7%) cases of microcytic hypochromic anemia, 68 (71.5%)cases showed left shift, 22 (23.1%) cases showed short peak, 3 (3.1%)cases showed broad peak, one case showed normal curve and another showed bimodal peak. In the microcytic hypochromic anemia, MCHC may be normal but MCV and MCH are decreased. Red blood cell population with low MCV will be shifted toward left.

Out of 60 (37.7%)cases of normocytic normochromic anemia, 44 (73.3%) cases showed short peak, 9(15%) cases showed left shift, 4 (6.6%) cases showed normal curve, rest three cases showed right shift, broad base and bimodal curve. In normocytic normochromic anemia, the red cell indices like MCV, MCH and MCHC were within the normal limits with some cases showing mild increase indices. The decrease in red blood cell count caused short peak in most of the histograms.

Out of 18 (11.3%) cases dimorphic anemia, 8 (44.5%) cases showed bimodal peak, 7(38.8%) cases showed short peak, 2cases showed left peak and one case showed broad base. In dimorphic anemia the histogram may have 2 or more red cell populations, whereas in dual populations, the histogram has two distinct

red cell populations. In dimorphic blood picture there may be dual population of microcytic & normocytic or normocytic & macrocytic red cells or admixture of small, normal and large cells of different sizes or admixture of patient and donor red cells. In our study in dimorphic anemia, a MCV, MCH and MCHC were normal and increased RDW due to marked anisopoikilocytosis. The dimorphic red blood cell showing bimodal curve along with some cases showing left and right shifting of curve. The reason for dimorphic population may be nutritional anemia, recent blood transfusion or response therapy to nutritional anemia<sup>4</sup>.

Pancytopenia is seen in two cases, one with short peak and the other with bimodal peak. Pancytopenia shows a decrease in cell counts of red blood cells, white blood cells and platelets. Macrocytic anemia is seen in one case with right shift. Macrocytic anemia due to variation in size and shape of the Red blood cells's, increased mean corpuscular volume, red cell distribution width, mean corpuscular hemoglobin were noted with normal mean corpuscular hemoglobin concentration. Right shift curve correlated well with increased mean corpuscular volume and Mean corpuscular hemoglobin.

## V. Conclusion

Anemia is not a disease, but a term indicating insufficient hemoglobin to deliver oxygen to the cells. It is always a secondary phenomenon. Anemia is usually caused by multiple mechanisms such as failure of erythropoiesis, decreased RBC survival, iron deficiency of chronic inflammation, impaired erythropoietin etc. Histogram can be used in differentiating various types of anemia<sup>10</sup>. Histogram changes correlated well with peripheral smear findings in majority of the cases.

Proper examination of peripheral blood smears along with correlation with diagrammatic representation of red blood cell histograms help in better understanding, interpretation and morphological typing of anemia. Histogram could be used as screening method and when combined with Peripheral blood smear findings, they act as useful supplement and by correlating findings of both methods we could diagnose majority of anemia.

The speed and the reliability of the modern analyzers allow technologists, time to evaluate abnormal blood films, consider diagnostic clues and correlate clinical findings to histograms and other hematologic parameters with greater confidence and efficiency, all of which produce high returns in terms of patient health care. It is a universal, economical and simple method to narrow down the differential diagnosis at early stages of patient evaluation.

Interpretation of histograms and scatter plots, in conjunction with the numerical data can be useful in the diagnosis and follow up of many hematological and non hematological conditions.

## References

- [1]. Bessman JD, Gilmer PR Jr, Gardner FH. Improved classification of anemias by MCV and RDW. *Am J clin pathol.* 1983; 80(3):322-6
- [2]. Fossat C, David M, Harle JR, Sainty D, Horschowski N, Verdout JJ, Mongin M et al. New parameters in erythrocyte counting value of histograms. *Archpathol Lab Med.* 1987;111(12):1150-54
- [3]. Gulati GL, Hyun BH; The Automated CBC. A current perspective. *Hematol Oncol Clin North Am.* 1994;8(4):593-603
- [4]. Constantino BT. The red cell histogram and the dimorphic red cell population. *Lab Medicine* 2011;42:300-8.
- [5]. Shirish M Kawthalkar, *Essentials of Clinical Pathology.* Jaypee; Automation in hematology; First edition; 2012: Page 319-326
- [6]. Sandhya I, Muhasin T. Study of RBC histogram in various anemias. *Journal of Evolution of Medical and Dental Sciences* 2014; Volume:3, Issue:74,; Page: 15521-15534
- [7]. Chavda J, Goswami P, Goswami A. RBC histogram as diagnostic tool in anemias. *IOSR Journal of Dental and Medical Sciences* .2015;14(10), 19-22
- [8]. Rao BSS, Vissa S, Rao NM, Grandhi B, Muramreddy V, Sirasala P. RBC Histogram as Supplementary Diagnostic Tool with Peripheral Smear Examination in Evaluating Anaemia. *Annals of Pathology and Laboratory Medicine.* 2017; 4(6):A668-672.
- [9]. Tahany Ali El Kerdany et al; Study of Automated Red Blood Cells Parameters in Correlation with Routine RBCs Morphology by Smear Review ; *The Egyptian Journal of Hospital Medicine (July 2017) Vol.68 (3), Page 1358-1363.*
- [10]. Shifa Maqsood et al; Study of RBC histograms in various anemias: A six months prospective study. *Perspectives in medical research; January – April 2019; vol 7; Issue 1.*

Dr. Vasundara Gardas. "Analysis of Red Cell Histograms." *IOSR Journal of Dental and Medical Sciences (IOSR-JDMS)*, vol. 18, no. 9, 2019, pp 01-05.