

## Atypical Cutaneous Manifestations in Adult Onset Still's Disease

Dr. Ramani Sneha Vanapalli, Dr. B.Gayatri Devi, Dr. K.V.T.Gopal,  
Dr.T.Narayana Rao.

Department of DVL, Maharajah Institute Of Medical Sciences, Vizianagaram, India.

Corresponding Author; Dr. Ramani Sneha Vanapalli

**Abstract:** Adult Onset Still's Disease (AOSD) is a rare systemic inflammatory disorder of unknown etiology characterized by high grade fever, skin rash, arthralgia and myalgia. We report a case of AOSD with atypical skin manifestations. A 19 year old female patient presented with fever, generalized skin eruption and severe joint pains since 20 days. On dermatological examination, multiple hyperpigmented papules coalescing to form plaques were present over perioral area, pinna, cheek, upper chest and extremities. Lesions were distributed irregularly in bizarre fashion and Koebner's phenomenon was present. Laboratory workup showed high TC-19600, high ESR-40mm/hr, high ferritin levels-250 ng/ml. ANA and RA factor were negative. Histopathology showed numerous individually necrotic keratinocytes scattered in upper epidermis with dense perivascular and interstitial infiltrate of lymphocytes and neutrophils in the upper dermis suggestive of AOSD. A diagnosis of AOSD should be kept in mind if a patient is in the age group of 15-25yrs, presents with high grade intermittent fever, polyarthrititis and skin rash of more than 2 weeks duration. The patient should be extensively evaluated to rule out other differentials of AOSD like acute or chronic infections, autoimmune disorders, vasculitis and malignant disorders.

**Key words:** AOSD.

Date of Submission: 10-01-2020

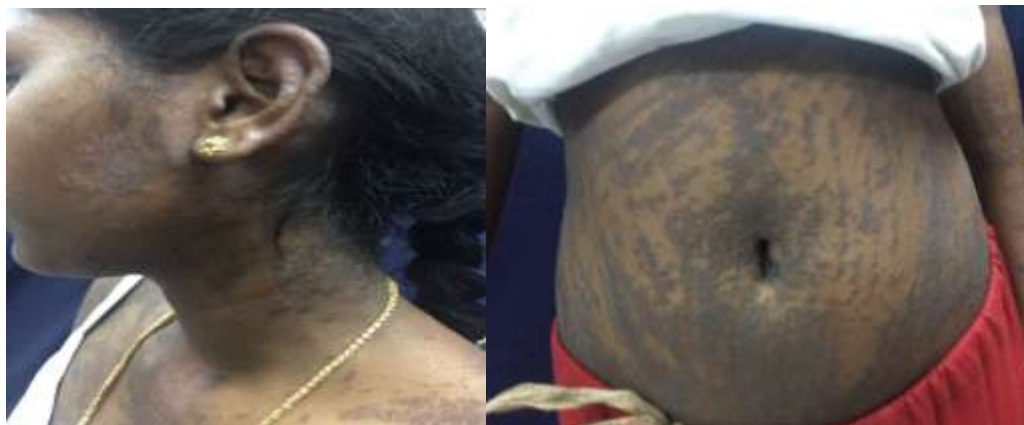Date of Acceptance: 27-01-2020

### I. Introduction:

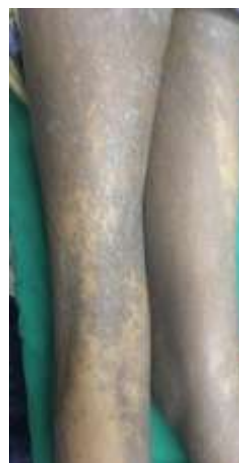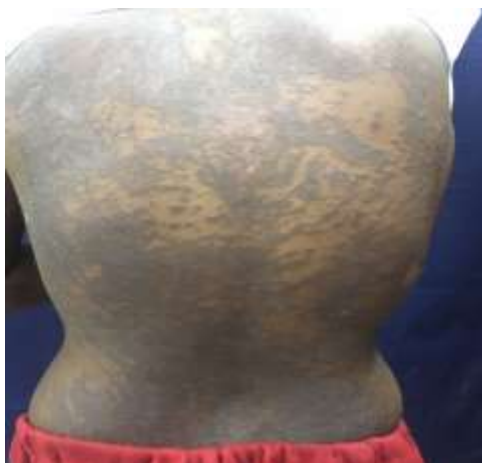- Adult Onset Still's Disease is a rare systemic inflammatory disorder of unknown etiology characterized by high grade fever, skin rash, arthralgia and myalgia.
- Typical skin rash in Still's disease is a fleeting maculopapular rash usually associated with fever spike.
- It affects young adults between 16-35yrs of age and is often diagnosed based on clinical features only.
- Atypical skin manifestations in AOSD are rare.

### Case Report:

- A 19 year old female patient presented with fever, generalized skin eruption and severe joint pains since 20 days.
- On examination, multiple hyperpigmented papules coalsing to form plaques present over perioral area, pinna, neck trunk and upper lower extremites and scalp.
- Well defined hyperpigmented plaques seen over the face, neck, upper chest areas.



Multiple violaceous hyperpigmented plaques with bizzare linear orientation (may be due to koebner's phenomenon) were present diffusely over abdomen.

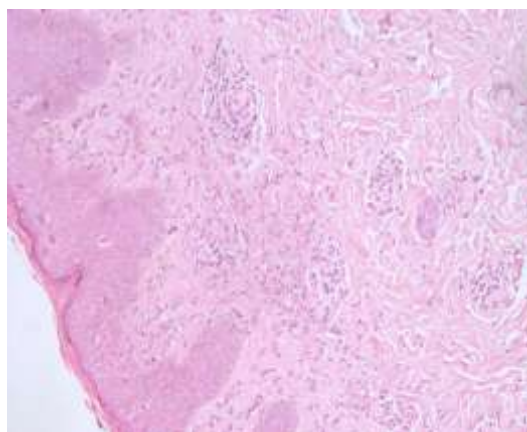


- Based on the clinical features, a differential diagnosis of Acute cutaneous LE, Drug induced lichenoid eruption, Urticariapigmentosa were considered.

**Investigations:**

- Laboratory workup showed high TC- 19600, high ESR-40mm/hr, high ferritin levels-250 ng/ml. ANA and RA factor were negative.

**SKIN BIOPSY:**Histopathology showed numerous individually necrotic keratinocytes scattered in upper epidermis with dense perivascular and interstitial infiltrate of lymphocytes and neutrophils in the upper dermis suggestive of AOSD.



**Treatment:**

- PREDNISOLONE 40 mg daily for 15 days followed by gradual tapering over 6 weeks.
- Cap Indomethacin 25 mg BD for 15 days.
- Tab pantopazole 40 mg for 15 days.
- Topical emollients .
- All the skin lesions resolved well in 3 to 4 weeks with faint post inflammatory hyperpigmentation. There is no recurrence. Patient is under follow up.

**II. Discussion:**

- Diagnosis of AOSD is made based on Yamaguchi's classification criteria. Major criteria include Fever >39°C intermittent for >1 week, Arthralgia >2 weeks, Typical rash, WBC > 10.000 (>80% granulocytes).
- Infections, malignancies and inflammatory diseases need to be excluded.
- The typical fleeting rash in Still's disease is commonly found on trunk and proximal extremities. Other clinical manifestations include sore throat, cardiopulmonary manifestations, splenomegaly, hepatomegaly and lymphadenopathy.
- Common laboratory abnormalities include high elevated ESR, leukocytosis (15000-30000), thrombocytosis (> 4 lakhs) and elevated ferritin levels.
- ANA and RF are negative.

### **III. Conclusion:**

A diagnosis of AOSD should be kept in mind if a patient is in the age group of 15-25yrs, presents with high grade intermittent fever, polyarthritis and skin rash of more than 2 weeks duration. The patient should be extensively evaluated to rule out other differentials of AOSD like acute or chronic infections, autoimmune disorders, vasculitis and malignant disorders.

### **References:**

- [1]. M. Yamaguchi, A. Ohta, T. Tsunematsu et al., "Preliminary criteria for classification of adult Still's disease," *Journal of Rheumatology*, vol. 19, no. 3, pp. 424-430, 1992.
- [2]. A. A. Fitzgerald, S. A. LeClercq, A. Yan, J. E. Homik, and C. A. Dinarello, "Rapid responses to anakinra in patients with refractory adult-onset Still's disease," *Arthritis and Rheumatism*, vol. 52, no. 6, pp. 1794-1803, 2005.
- [3]. P. Efthimiou, P. K. Paik, and L. Bielory, "Diagnosis and management of adult onset Still's disease," *Annals of the Rheumatic Diseases*, vol. 65, no. 5, pp. 564-572, 2006.
- [4]. S. Kobak, H. Yilmaz, A. Karaarslan, and M. Yalcin, "Leukocytoclasticvasculitis in a patient with ankylosing spondylitis," *Case Reports in Rheumatology*, vol. 2014, Article ID 653837, 3 pages, 2014.
- [5]. J. A. Carlson, "The histological assessment of cutaneous vasculitis," *Histopathology*, vol. 56, no. 1, pp. 3-23, 2010.

Dr. Ramani Sneha Vanapalli, et.al. "Atypical Cutaneous Manifestations in Adult Onset Still's Disease". *IOSR Journal of Dental and Medical Sciences (IOSR-JDMS)*, 19(1), 2020, pp. 64-66.