

## Cytological Diagnosis of Osteosarcoma in 4 Year Old Female-A Rare Case Report

Dr. Apoorva Nigam<sup>1</sup>, Dr. Shafak Aggarwal<sup>2</sup>, Dr Upasana<sup>3</sup>,  
Dr. Kanwardeep Kaur<sup>4</sup>

<sup>1,2,3,4</sup> (Department of Pathology, Govt. Medical College, Patiala)

Corresponding Author: Dr Shafak Aggarwal

---

**Abstract:** Osteosarcoma is defined as the primary malignant mesenchymal tumor. Bone tumors make up to 3-5% of childhood cancers and less than 1% of cancers in adults.<sup>1,2</sup> Of these osteosarcoma is the most commonly diagnosed primary malignant bone tumor. Individuals with localized osteosarcoma have an average 5 yr survival of about 80% but those with metastatic disease have much worse outcomes.<sup>3</sup> Its incidence is bimodally distributed by age with first peak in adolescence and second peak in the elderly.<sup>1,3,4</sup>

**Keywords:** Osteosarcoma, children, Fine Needle Aspiration

---

Date of Submission: 24-12-2019

Date of Acceptance: 07-01-2020

---

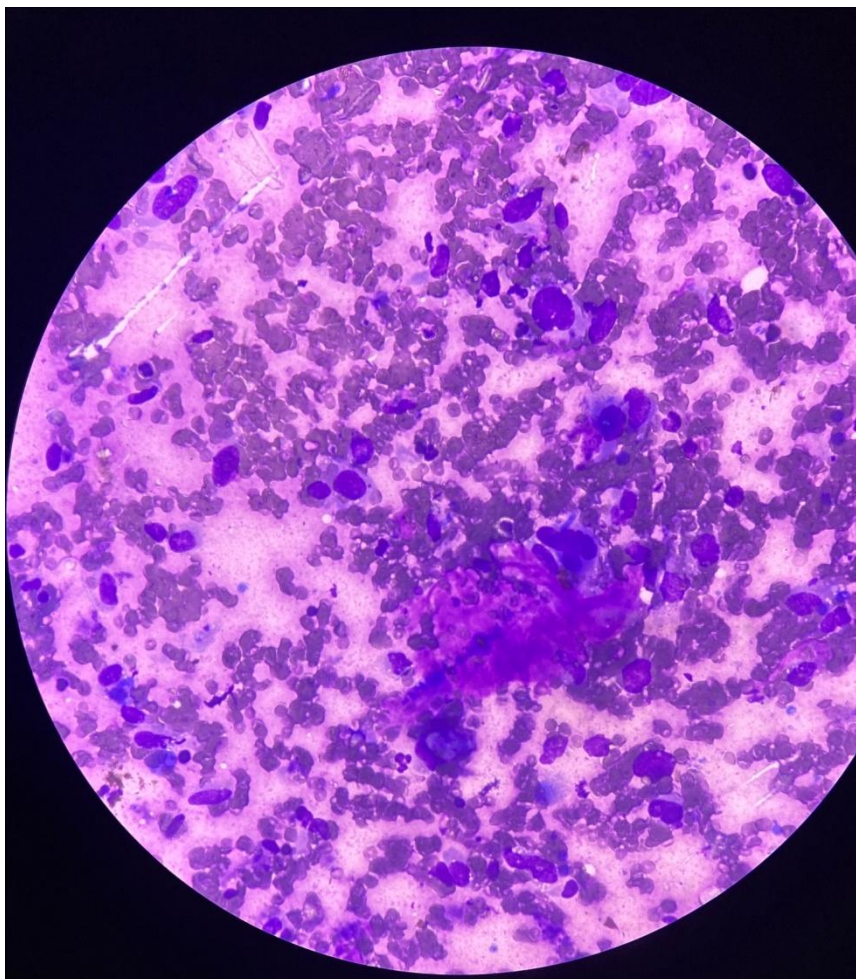
### I. Introduction

Osteosarcoma is the most common primary osseous malignancy. Most of the cases are found in the metaphysis of long bone<sup>5</sup>. Here we present a case of 4 year old female child who underwent fine needle aspiration cytology (FNAC) from a mass in left thigh.

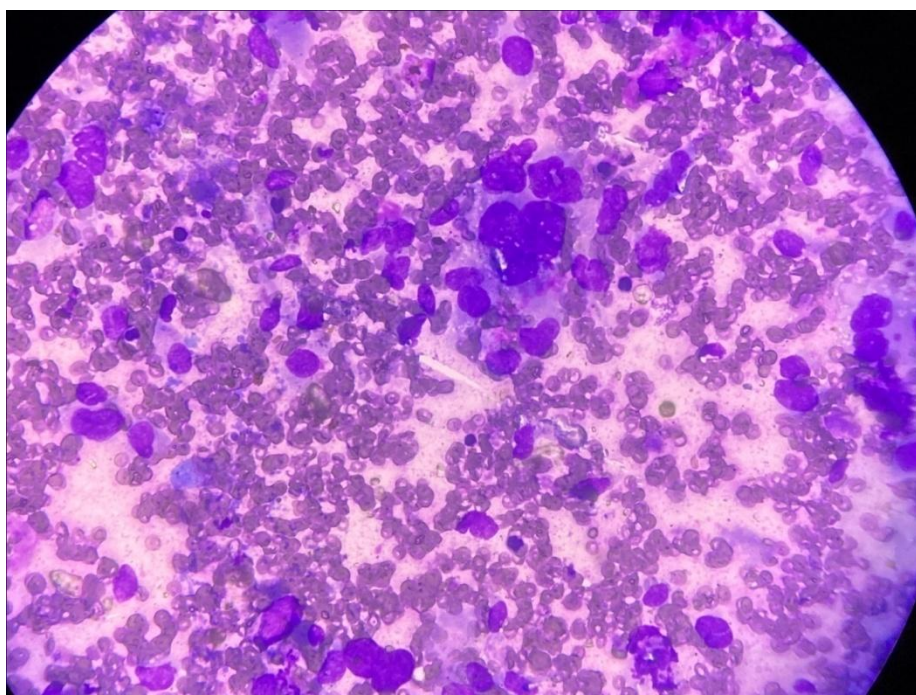
### II. Case Report

A 4 year old female patient presented to OPD facility of GMC Patiala with complaints of pain and swelling in lower left thigh. The swelling was diffuse and measured 5cm×4 cm. There was no history of trauma or prior radiation therapy. MRI scan of left knee showed evidence of large areas of altered marrow signal intensity involving distal femoral shaft with involved diaphysis and metaphysis with small extension into epiphysis. The bony cortices appeared indistinct and eroded at places. Associated soft tissue mass was also seen along the anteromedial aspect bulging into suprapatellar bursa and medial aspect of patellofemoral joint. The entire lesion was 50×37 mm in maximum axial dimensions with a length of about 11.5 cm. Fine needle aspiration cytology was done using a 22 gauge needle attached to 10 ml syringe on Cameco handle under aseptic precautions. Smears were air dried and stained with May-Grunwald-Giemsa (MGG).

The cytological smears were highly cellular and showed clusters and singly scattered tumor cells. The cells were round to oval and highly pleomorphic and had a high N/C ratio with irregular nuclear contour along with prominent nucleoli. Many bizarre and tumor giant cells were also noted [Figure 2]. On careful search, a focal area showing presence of pink/metachromatic osteoid like material was identified [Figure 1]. Based on these findings, a diagnosis of osteosarcoma was made.



**Figure 1:** Malignant cells embedded in osteoid matrix(MGG)



**Figure 2:** Malignant cells with prominent nucleoli along with tumor giant cell(MGG)

### III. Discussion

Osteosarcoma predominantly affects patients younger than 20 years and mainly occurs in the long bones of the extremities, the most common being the metaphyseal area around the knee. The Surveillance, Epidemiology, and End Results (SEER) program of the National Cancer Institute (NCI) provide the following osteosarcoma incidence data: 5 to 9 years, 2.4 cases per million per year; 10 to 14 years, 7.6 cases per million per year; and 15 to 19, 8.2 cases per million per year. Of note, osteosarcoma is extremely rare before 5 years of age with an estimated incidence of 4 cases per million per year.<sup>2,3</sup> They arise in several clinical settings, which include pre-existing bone abnormalities such as Paget's disease, fibrous dysplasia, giant cell tumor, multiple osteochondroma, bone infarct, chronic osteomyelitis, osteogenesis imperfecta, and a history of radiation exposure.<sup>6</sup> Our patient had no predisposing factor during gestational period and after birth and her family history was negative for malignant diseases. Males are affected more frequently (male: female ratio; 1.4:1), though the rate for girls up to approximately 13 years of age are roughly 30% higher than those for boys. In the 15–24-year-old age group, the rate of occurrence in males exceeds those in females by approximately 140%.<sup>7</sup> These are classified as primary (central or surface) and secondary osteosarcomas arising in preexisting conditions. The conventional plain radiograph is the best for probable diagnosis as it describes features like sun burst appearance, Codman's triangle, new bone formation in soft tissues along with permeative pattern of destruction of the bone and other characteristics for specific subtypes of osteosarcomas. Radiographs will show an ill-defined lesion arising at the metaphysis of bone, with osteoblastic and/or osteolytic areas, periosteal reaction, and a soft tissue mass. Magnetic resonance imaging (MRI) is warranted to evaluate the lesion's invasion into the soft tissue and neurovascular structures, level of bone marrow replacement, skip lesions, and extension into the bordering joint. Differential diagnosis of osteosarcoma include chondrosarcoma, rhabdomyosarcoma, Ewing sarcoma, bone metastasis and osteomyelitis. Due to young age of our patient initial diagnosis of Ewing Sarcoma was made however microscopic examination showed cellular stroma containing osteoid along with many pleomorphic and multinucleated tumor cells along with MRI findings confirmed the diagnosis of osteosarcoma.

### IV. Conclusion

Osteosarcoma is the most common type of bone cancer in children, typically occurring after the age of 10 years. It is extremely rare in children before the age of 5 years. To conclude, the diagnosis of osteosarcoma is challenging on cytology. The diagnosis rests primarily on the identification of osteoid production by the malignant cells. Correlation with radiological findings can aid in a definitive diagnosis.

### References

- [1]. Dorfman HA, Czerniak B. Bone Cancers. Cancer supplement. 1995;75:203–210.
- [2]. Mascarenhas L, Siegel S, Spector L, Arndt C, Femino D, Malogolowkin M. Malignant bone tumors: cancer in 15- to 29-year-olds in the United States. In: Bleyer A, O'Leary M, Barr R, Ries LAG, editors. Cancer Epidemiology in older adolescents and young adults 15 to 29 years of age, including SEER incidence and survival: 1975–2000. Bethesda, MD: National Cancer Institute; 2006. pp. 98–109. NIH Pub. No. 06-5767.
- [3]. Mirabello L, Troisi RJ, Savage S. Osteosarcoma incidence and survival rates from 1973 to 2004: Data from the Surveillance, Epidemiology, and End Results Program. Cancer. 2008 in press.
- [4]. Ji J, Hemminki K. Familial risk for histology-specific bone cancers: An updated study in Sweden. Eur J Cancer. 2006;42:2343–2349.
- [5]. Nakajima H, Sim FH, Bond JR, Unni KK. Small cell osteosarcoma of bone. Review of 72 cases. Cancer. 1997;79:2095–106.
- [6]. Khorate MM, Goel S, Singh MP, Ahmed J. Osteosarcoma of the mandible: A case report and review of the literature. J Cancer Sci Ther 2010;2:122-5.
- [7]. Clark JL, Unni KK, Dahlin DC, Devine KD. Osteosarcoma of the jaw. Cancer 1983;51:2311-6.

Dr Shafak Aggarwal.et.al. "Cytological Diagnosis of osteosarcoma in 4 year old female-A rare case report." *IOSR Journal of Dental and Medical Sciences (IOSR-JDMS)*, 19(1), 2020: pp. 15-17