

Ultrasound guided Fine needle aspiration cytology in diagnosing Primary neuritic leprosy cases at Sub-Himalayan region of West Bengal

Niladri Halder¹, Nibedita Halder², Mintu Saha³, Nihar Ranjan Halder⁴
Pronomita Ghosh⁵

¹Junior Resident, Department of Pathology, Dr. D. Y. Patil Medical College, Hospital and Research Centre, Dr. D. Y. Vidyapeeth, Pune.

²Prof, MGM Medical College, Kishanganj, Bihar & Consultant Microbiologist, "The Microbes Pathological laboratory", Siliguri

³Consultant Radiologist, "The Tenovus Diagnostic & Research Centre Pvt Ltd", Hakimpara, Siliguri

⁴Consultant Neurologist, "The Tenovus Diagnostic & Research Centre Pvt Ltd", Hakimpara, Siliguri

⁵Pronomita Ghosh, Senior Resident, Department of Obstetrics & Gynaecology, Ruby Hall Clinic, Pune

Abstract

Background: The present study was undertaken to assess the capacity of High Resolution Ultra Sonography and fine needle aspiration cytology of ulnar & popliteal nerves in the detection of pure neuritic leprosy.

Materials & Methods: From 15th April, 2016 upto 14th April 2019 800 suspected cases of pure neuritic leprosy attending Out Patient Department of "The Tenovus Diagnostic & Research Centre Pvt. Ltd", Hakimpara, Siliguri were screened by High Resolution Ultrasonography followed by USG guided Fine needle aspiration cytology (FNAC) on all ultrasonographically hypoechoic nerves. Cytological & Microbiological studies were performed at the 'The Microbes' Pathological laboratory, Ashrampara, Siliguri

Results: 608 (76%) cases showed diffusely hypoechoic nerves. Of all the 608 hypoechoic nerves subjected to USG guided FNAC 529 (87%) showed features of neuritis and 237 (39%) showed presence of Acid fast bacilli (AFB) in Ziehl-Neelsen (Z – N) stain. Presence of epithelioid cell granuloma and langhans giant cells were seen in 292 (48%) of the cases.

Conclusion: High resolution Ultrasonography and USG guided FNAC are effective new screening tool in the investigation of Pure Neuritic Leprosy cases.

Keywords: High resolution Ultrasonography (HRUS), Primary neuritic leprosy (PNL), Fine needle aspiration cytology (FNAC), Ziehl-Neelsen (Z – N), Ultrasonography (USG), Acid-fast bacilli (AFB)

Date of Submission: 15-12-2020

Date of Acceptance: 29-12-2020

I. Introduction

Leprosy, also called Hansen's disease, was the scourge of the ancient world. Despite the introduction of effective treatment, large number of patients remain untreated and there are more than 6 – 8 million cases of leprosy worldwide, 60% of them are in Asia.

This chronic granulomatous disease primarily involves Skin, Peripheral nerves and nasal mucosa. In certain situations nerve involvement is seen in the absence of skin lesions. In these circumstances slit skin smear examination comes negative and are referred to as Primary Neuritic leprosy (PNL). Then it may resemble other peripheral neuropathies and negative result in Ziehl-Neelsen stain (Z–N stain) of slit skin smear contributes to the delay in diagnosis. The most common presentation of PNL is a mononeuritis (Single nerve involvement) which occurs in about 60% of the cases¹. When more than one nerve is involved in an asymmetrical distribution it is known as mononeuritis multiplex, while symmetric involvement is called polyneuropathy or Symmetrical polyneuritis. Nerves in the upper limbs – ulnar, radial & cutaneous are involved more often and temperature with pain sensation are the first to be affected, but the patient may complain of sensory and / or motor impairment, numbness, parasthesia and neural pain. High resolution Ultra sonography (HRUS) of nerve has been shown to be a useful technique to detect these leprosy induced nerve damage^{2,3}.

II. Materials and Methods

A prospective ongoing study has been carried out over a period of three years since 15th April, 2016 upto 14th April 2019 on a total of eight hundred (800) cases of clinically suspected primary neuritic leprosy attending out patient Dept. of “The Tenovus Diagnostic & Research Centre Pvt, Ltd”, Hakimpara, Siliguri. All the cases were referred to Ultrasonography (USG) Dept of “Tenovus Diagnostic & Research Centre”, Hakimpara, Siliguri for HRUS. Common cases of neuritis like Diabetes & Vasculitis were excluded from the study. The patients belonged to Siliguri and the surrounding areas like Sikkim, Darjeeling, Mirik, Naxalbari, Coochbehar, Jalpaiguri. Suspected peripheral nerves in the extremities were scanned by HRUS – model no. Siemens XP 300 Premium edition using VF - 10 – 5 MHZ linear probe. Only ulnar nerves & lateral popliteal nerves were scanned according to the limbs involved.

USG was done in prone position with both hands in internal rotation & extension at elbow for ulnar nerve. Lateral popliteal nerves were screened in popliteal fossa in extension. USG criteria noted were thickness of nerves, echogenicity, nodularity, intra and peri-neural collections. The nerves on HRUS were mentioned as hypochoic when they showed more hypochoic echotexture in comparison with adjacent muscles. The nerves were mentioned as normal when the echogenicity of nerves was less than a tendon & more than a muscle. Only the hypochoic nerves were subjected to ultra sound guided Fine Needle Aspiration Cytology (FNAC). Aspiration was carried out by 22 gauge needle fitted on a 10 ml syringe inserted along the length of the nerve. Adequate aspirates were collected and processed. Cytological smears from the aspirates were stained and read for cellularity, their arrangement and presence of acid fast bacilli (AFB). All these tests were performed at “The Microbes pathological laboratory”, Ashrampara, Siliguri

The Socioeconomic and literacy data of patients were also noted simultaneously.

III. Results

HRUS of nerves was done in 800 cases, out of which independently of ulnar nerves, popliteal nerves and combinedly cases of both ulnar nerves & popliteal nerves were evaluated.

608 (76%) cases showed diffusely hypochoic echotexture of nerves image and 192 (24%) cases showed normal echotexture. 195 (32%) hypochoic nerves showed nodularity along the segment image & 55 (9%) showed nerve abscess. Highest numbers fell in 40 – 50 years of age group. 592 (74%) were from Non BPL (Below Poverty line) group. Male preponderance was noted. The average maximum thickness of nerves was more in hypochoic nerves as against normal nerves. Of all the 608 hypochoic nerves subjected to USG guided FNAC, 529 (87%) showed features of neuritis and 237 (38.9%) showed presence of AFB in Z-N stain. Smears revealed nerve fibres infiltrated by chronic inflammatory cells in all the hypochoic nerves, presence of epithelioid cell granulomas & langhans giant cells in 292 (48%)of the cases.

IV. Discussion

If skin patches and presence of AFB were the only criteria used for diagnosis of leprosy, it is obvious that all the cases of Primary neuritic leprosy (PNL) which constitute a good percentage of all leprosy patients would be missed. Hence retaining PNL as a distinct type of leprosy is important for leprosy programme. The fact that skin lesions are noted to occur in upto 20% of PNL over months and years of observation indicates that this is a form of leprosy with initial pronounced nerve trunk involvement followed by cutaneous manifestations in a good proportion of cases. In other words categorizing PNL as a distinct group and clinically diagnosing these cases early equates to identifying leprosy before the skin is involved. Such early identification of PNL and its treatment is of great benefit to the patient as it limits the extent and progression of nerve damage & resulting disability. The only limitation of this technique is that a negative aspirate does not rule out leprosy.

Development of new hardware & software in medical imaging like HRUS is attempting at imaging of many smaller structures like skin, nail bed, nerves etc. Solbiati et al⁴ presented with first paper on HRUS of recurrent laryngeal nerve. Fornage et al⁵ gave more detailed imaging of peripheral nerves in extremities. Last two decades showed increase emphasis on HRUS of nerves. Simultaneous comparison of HRUS with electrophysiological studies & Histopathological studies were also tried^{6,7}. One article suggests USG guided FNAC may be substituted for open nerve Biopsy⁸. Pathological changes in the nerves can be demonstrated by nerve enlargement & increased hypochoicogenicity. HRUS can pickup many types of nerve patterns. High Resolution Ultrasonography can also be incorporated as a bedside tool for Neuro muscle Ultrasound examination.

In the recent years FNAC of suspected nerves showed good pickup rate. In our study out of 800 clinically suspected cases of PNL 76% showed positive features on HRUS of which 87% were positive on cytological evaluation (USG guided FNAC done) establishing a good correlation.

As the WHO 2000 programme of global elimination of leprosy failed more concerns were raised.⁹ WHO 2005 programme did suggest various steps, which still showed various lacunae.¹⁰ Though the data published by WHO in successive years show reducing prevalence rates there is more to do in the field as the clinical screening of PNL cases may show wider inter-observer reliability. The cases of PNL are to be highly suspected in doubtful neuropathies & there is a need for acute awareness. Our study showed the presence of PNL more in non-BPL category and it may explain more people are out of the surveys conducted by health agencies. Practically there is problem to convince the patient who has PNL in absence of skin lesions. There is also growing concept of evidence based medicine which thus necessitates to have a more methodical approach & more tools to screen & diagnose PNL.

High Resolution Ultrasonography is of proven value in visualizing structured changes of major nerve trunks in all types of leprosy.¹¹ The increased blood flow and vascularity observed on ultrasound were correlated with oedema & vascularity cytologically showing that ultrasound could be non-invasive tool to recognize neuritis and to indicate the need for corticosteroid therapy to prevent permanent nerve damage associated with reactions.¹² FNAC is a safe, less invasive and briefer procedure as composed to nerve biopsy for the diagnosis of PNL

Table 1
Geographical distribution of all 800 Primary neuritic leprosy cases

Siliguri	280
Naxalbari	139
Coochbehar	58
Darjeeling	39
Jalpaiguri	62
Mirik	121
Sikkim	101
Total	800

Table 2
Distribution of Hypoechoic & normal ecotexture of nerves among with 800 patients

Hypoechoic echotexture of nerve image	608 (76%)
Normal echotexture of nerve image	192 (24%)

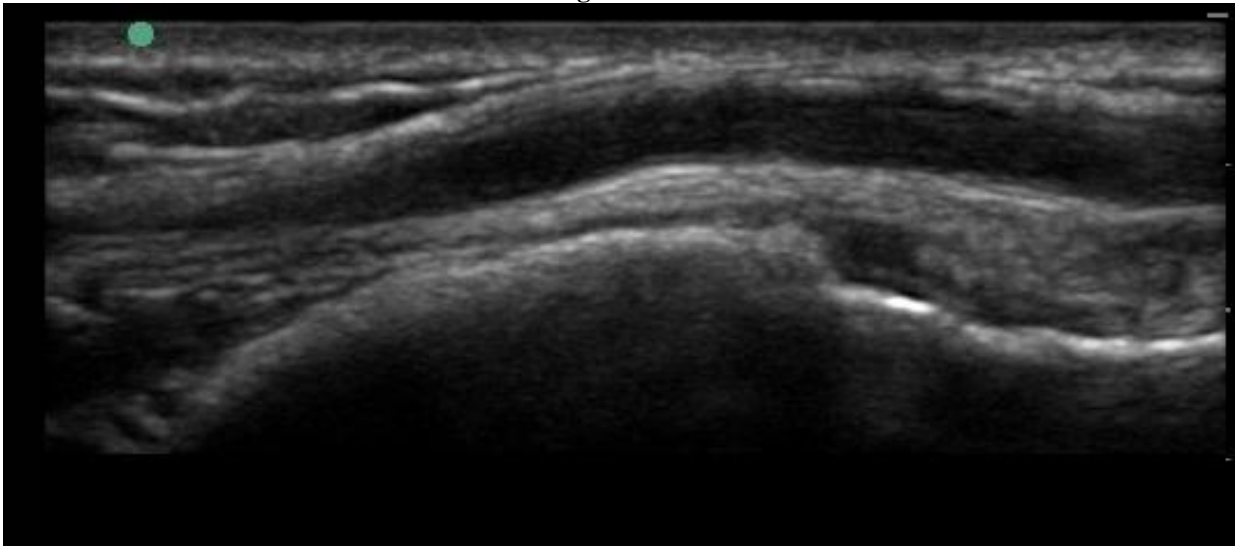
Table 3
Distribution of Different pathological changes among 608 hypoechoic nerves

Nodular changes along nerve image	195 (32%)
nerve abscess	55 (9%)
Features of Neuritis	529 (87%)
AFB	237 (38.9%)
Epithelioid cell granuloma & Langhans giant cells.	292 (48%)

Table 4
Socioeconomic status of all the 800 patients suspected primary neuritic leprosy cases

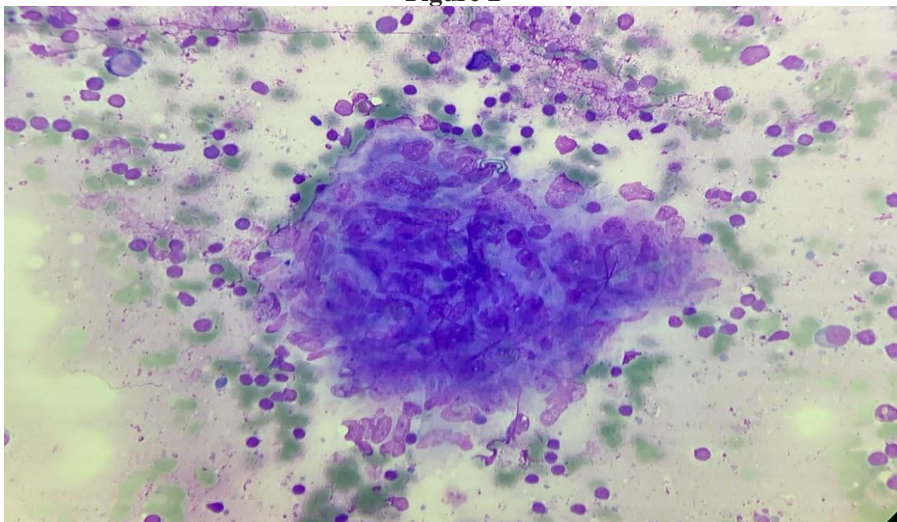
BPL card holder	208 (26%)
Non BPL card holder	592 (74%)
Total	800 (100%)

Figure 1



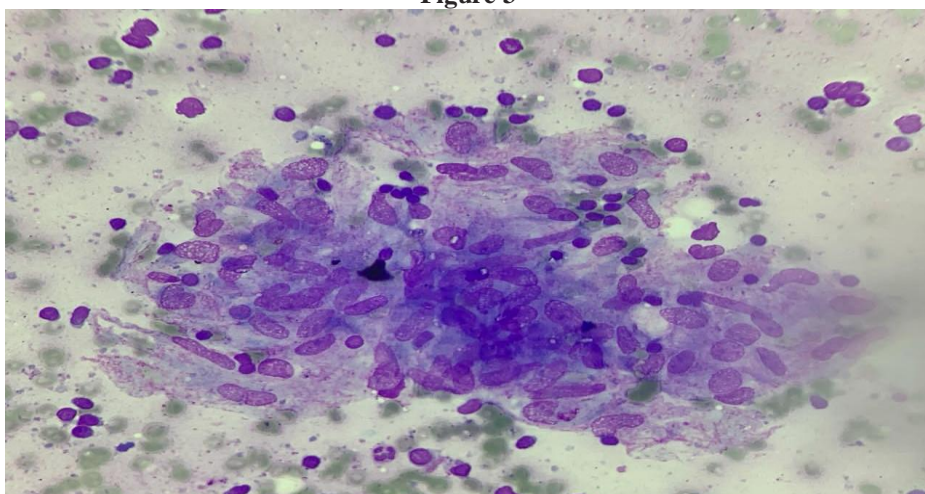
Ultrasonography & Colour doppler image of ulnar nerve showing thickened and hypoechoic texture

Figure 2



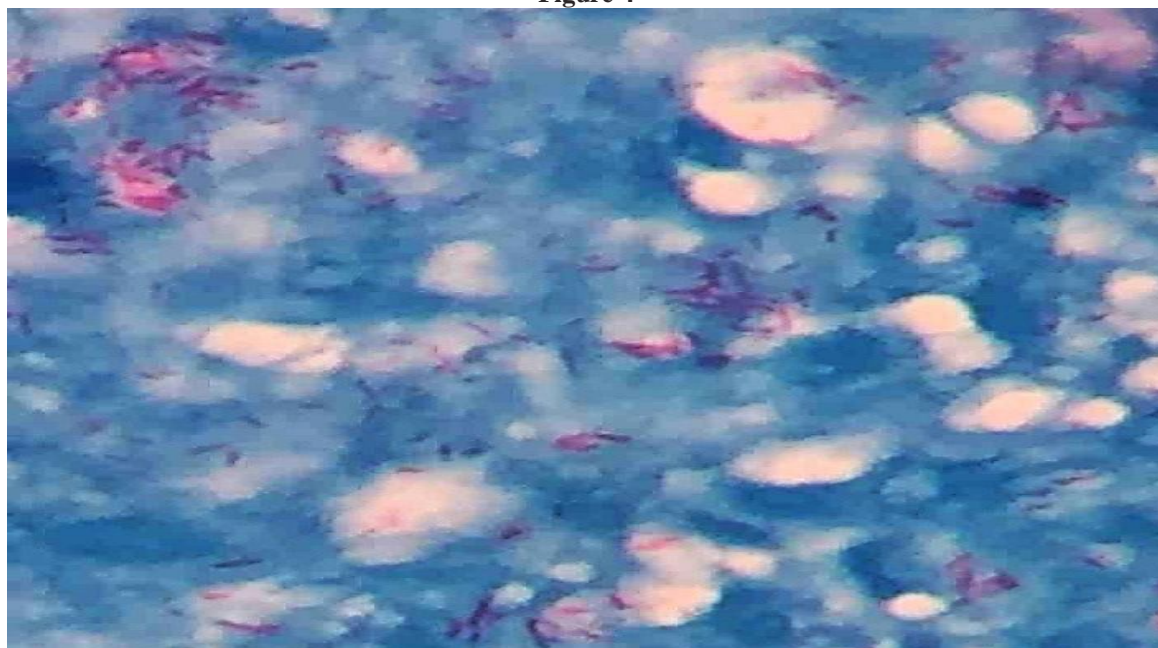
FNAC finding - chronic inflammatory changes of hypoechoic nerve (Low power)

Figure 3



FNAC finding - chronic inflammatory changes of hypoechoic nerve of same field (High power)

Figure 4



Z-N stain showing plenty of Acid fast bacilli in the aspirated sample by FNAC of hypoechoic nerve

V. Conclusion

Present study proves that ultrasound guided FNAC is an easy, less time consuming, safe, less invasive & less expensive procedure for the diagnosis of PNL cases in case of negative slit skin smear result. Thus, early identification of PNL cases is of great benefit to the patient initiating early treatment limiting extend of nerve damage and resulting disability.

References

- [1]. Bhusan Kr. Pure or primary neuritic leprosy. *Lepr Rev* 2016 87, 450 – 455
- [2]. Ramadon W, Mourad B, Fadel W, Ghoraba E. Clinical, electrophysiological and immunopathological study of peripheral nerves in Hansen's disease. *Lepr Rev* 2000; 72: 35 – 49
- [3]. Jardim MR, Antunes SL, Simons B et al Role of PGL-1 antibody detection in the diagnosis of pure neural leprosy.
- [4]. Solbiati L, depraal, belloti T, derchi I e, High resolution sonography of the recurrent laryngel nerve: Anatomic and pathological considerations. *AJR* 1985;145:989-993
- [5]. Fornage b d peripheral nerves of the extremity: imaging with us. *Radiology* 1988; 167:179-182
- [6]. Pannikar VK, Arunthathi S, Chacko CJ, Fritschi EP. A clinic-pathological study of primary neuritic leprosy. *Lepr India*, 1983; 55: 212 – 221.
- [7]. Mishra B, Mukherjee A, Girdhar A et al. Neuritic leprosy: further progression and significance. *Acta Leprol*, 1995; 9: 187 – 194.
- [8]. *Lepr Rev* 2001;72:171-8 Fine needle aspiration cytology (FNAC) of nerves in leprosy Vijaikumar M. D'Souza m, Kumar S, Badhe.
- [9]. Rao p n, lakshmi ts. final push of leprosy in India: what is being pushed ? *Indian journal of dermatol venereal leprol* 2005; 71:226-9
- [10]. Burnett MG, Zager EL. Pathophysiology of Peripheral nerve injury: A brief review. *Neurosurg Focus* 2004; 16:E1
- [11]. Peer S, Kovacs p, Harpf C, Bodner G. High resolution sonography of lower extremity peripheral nerves. Anatomic correlation and spectrum of disease. *J ultrasound Med* 2002; 21: 315 – 22
- [12]. Wilder-Smith EP, Van Braket WH. Nerve damage in leprosy and its management. *Nat Clin Pract Neuro* 2008; 4: 656-63

Niladri Haldar, et. al. "Ultrasound guided Fine needle aspiration cytology in diagnosing Primary neuritic leprosy cases at Sub-Himalayan region of West Bengal." *IOSR Journal of Dental and Medical Sciences (IOSR-JDMS)*, 19(12), 2020, pp. 23-27.