

Predicting factors in open globe injury

¹Dr. Rajesh Kumar Saini MS, DNB, MNAMS, FICO, FAICO, Assistant Professor

²Dr. Shashidhar Haryvashi MS, Assistant Professor

¹Dr. Priyanka Mehra MS, Medical Officer

¹Dr Avnish Jangid MS

¹Dr Brijesh Sanwaliya MS

¹JLN Medical College Ajmer Rajasthan India

²P D U Medical College, Churu, Rajasthan

Corresponding Author: Dr. Shashidhar Haryvashi MS, Assistant Professor, Department of Ophthalmology, P D U Medical College, Churu, Rajasthan, India.

Abstract

Aim: To identify the prognostic factors in open globe injuries.

Materials and Methods: Retrospective interventional study at JLN medical College, Ajmer and PDU medical College, Churu Rajasthan, India in year 2019, patients presented to casualty department of eye and undergone intervention with follow-up period of 1 to 3 months or till better recovery.

Results: Total 62 patients, 44 (71%) were males and 18 (21%) were females. Mean age was 24 years (with range: 2.5-62 years). Factors affecting final outcomes in ocular trauma are nature and mechanism of injury, presenting conditions, initial visual acuity, timing of presentation and timing of intervention, segmental involvement as anterior or posterior segment and zone of injury.

Conclusion: These predicting factors helps in counseling and explaining the prognosis and also the deciding the line of treatment.

Keywords: Ocular trauma, open globe injuries, predicting factors.

Date of Submission: 11-03-2020

Date of Acceptance: 25-03-2020

I. Introduction

Ocular trauma is one of the leading causes of ocular morbidity in children and young adults. [1] Open globe injury, defined as a full thickness wound of the eye wall, is a major but preventable cause of permanent visual impairment and blindness in the world. Ophthalmologists faces difficulty during management of ocular trauma, explaining the prognosis, counseling to victim and his relatives. Although advent of new modalities and the management of ocular injuries has changed with good outcomes.

Predictors of final visual acuity are initial visual acuity, mechanism or type of injury, zone of injury, uveal involvement, lens injury, hyphema, posterior segment (retinal detachment, uveal or retinal tissue prolapse, vitreous hemorrhage, endophthalmitis, etc), timing of surgery, and number of operative procedures, etc. [2-18]

In the present study is aimed at evaluating the factors affecting the final vision outcome in patients with open globe injuries at a tertiary referral eye care center in Central Rajasthan, India.

II. Material And Methods

Retrospective interventional study at JLN medical College Ajmer and PDU Medical College Churu Rajasthan, India from January 2019 to December 2019.

- **Inclusion criteria**

Patients attended the casualty department of eye and undergone intervention with follow-up period of 1 to 3 months or till better recovery.

- **Exclusion criteria**

Previous established eye diseases like glaucoma, congenital anomalies, and other non-traumatic causes.

Detailed ocular examination, i.e., initial visual acuity, adnexal, anterior segment examination by slitlamp biomicroscopy, intraocular pressure (IOP) measurement and fundus examination. USG scan was carried out to assess posterior segment status, particularly, retinal detachment, vitreous hemorrhage and to rule out retained intraocular foreign body (IOFB) in patients with hazy media. X-ray and or computed tomography (CT) scan of the orbit was done to rule out retained IOFB in all patients.

The factors studied were age and sex of the patient, initial visual acuity, mechanism and type of injury, timing of presentation and intervention, extent of wound in *zones, segment involvement, uveal prolapse, vitreous hemorrhage, presence or absence of retinal detachment, evidence of infection on or around the wound, presence or absence of hyphema and lens status, etc

*Zone of injury was defined according to the Ocular Trauma Classification Group: zone 1 (the whole cornea, including corneoscleral limbus), zone 2 (corneoscleral limbus to a point 5 mm posterior into the sclera), and zone 3 (posterior to the anterior 5 mm of the sclera).

III. Results

➤ **Age and sex**

Of the 62 patients, 44 (71%) were males and 18 (21%) were females. Mean age was 24 years (with range: 2.5-62 years).

➤ **Visual acuity (VA)**

Visual Acuity	Initial VA	Final VA
>6/18	18 (29.03%)	39 (62.90%)
6/18-6/60	14 (22.58%)	12 (19.35%)
<6/60-CF	14 (22.58%)	4 (6.45%)
PL+ PR +	12 (19.35%)	3 (4.84%)
NO PL	4 (6.45%)	4 (6.45%)
Total	62 (100%)	62 (100%)

Patients presented to casualty with good initial visual acuity shifted in good visual acuity recovery groups. I.e. patients with good initial visual acuity had good anatomic conditions and they had faster recovery.

➤ **Mechanism of injury**

Mechanism	Number of patients	%
Work/ household injury	28	45.16
Blunt	12	19.35
Sports	4	6.46
Projectile	6	9.67
Assault	10	16.13
Firecracker or blast	2	3.22
Total	62	100

Most of the ocular injuries occurred by work /household objects (45.16%), blunt objects (19.35%), and assault (16.13%). Patients of good initial visual acuity were in work/ household and blunt object injuries groups.

➤ **Mode of injury**

Anterior segment include cornea to lens (i.e. Corneo-scleral tear, Hyphema, Lens injury, Iridodialysis, lens injury)

Posterior segment include behind to posterior lens capsule to (I.e. Retinal detachment, Choroidal detachment, Vitreous hemorrhage, Endophthalmitis).

Corneal/corneo-sclera/scleral tear	62
Hyphema	16
Iridodialysis	4
Lens injury	25
Uveal tissue prolapse	28
Retinal detachment	5
Vitreous hemorrhage	9
Endophthalmitis	6
IOFB	5

Anterior segment involving patients were more and also visual recovery more in this group compared to posterior segment group.

Patients who had cataract without posterior segment involvement recovered with good outcomes after cataract surgery and IOL implantation.

Out of 5 intraocular foreign body (IOFB), 3 were in anterior segment, while 2 were in posterior segment which was managed with vitrectomy.

➤ **Zonal injury**

Zone 1	31	50.0%
Zone 2	20	32.25%
Zone 3	11	17.75%
Total	62	100.0%

▪ Zone 1 injury patients were more in numbers and also in good initial visual acuity groups; hence had good recovery.

▪ In terms of the zone of injury, 31 (50%) eyes had zone 1 injuries, 20 (32.25%) eyes had zone 2 injuries, and 11 (17.74%) eyes had zone 3 injuries.

➤ **Timing of presentation**

Most of reported to casualty within 24 hours 39 eyes (63.0%) eyes), remaining delayed reported days to week 23 eyes (37.0%).

Early presenting patients got early treatment or intervention. Also early and good recovery.

➤ **Numbers of surgery**

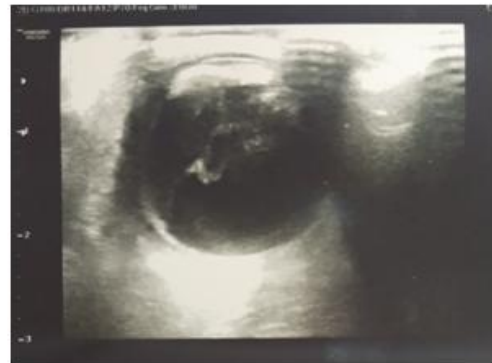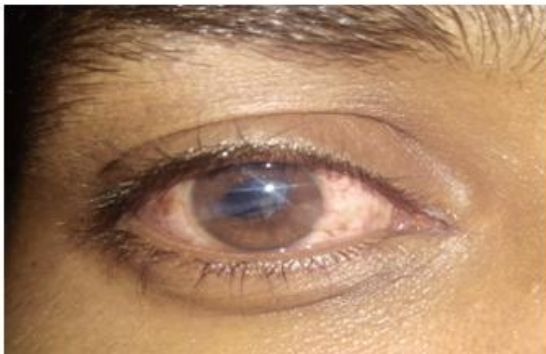Single step surgery	37	59.68%
Multistep surgery	25	40.32%

Out of all cases, 37 cases were managed with single step surgery while 25 cases with multistep surgical procedure. I.e. in form of tear repair, hyphema wash, iridodialysis repair, cataract surgery, secondary glaucoma surgery, pars plana surgery, silicone oil removal or secondary IOL implantation.

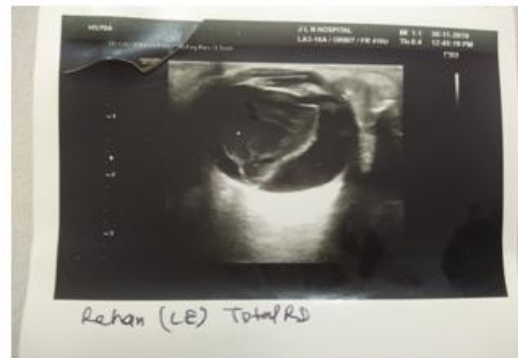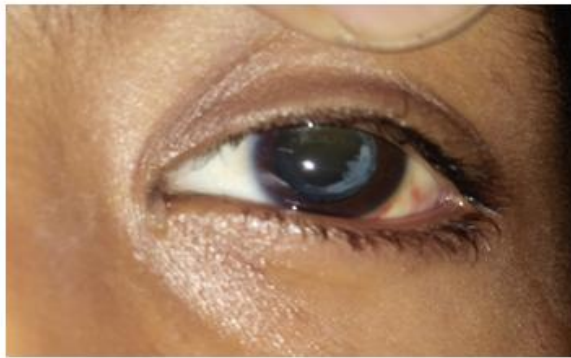
Faster (visual and anatomic) recovery recorded in single step than multistep surgeries.

In our study, 58 patients operated for tear, 21 eyes with traumatic cataract treated surgically with intraocular lens (IOL) implantation. Seven patients operated vitrectomy for vitreous hemorrhage, retinal detachment, endophthalmitis and or IOFB and three were needed evisceration.

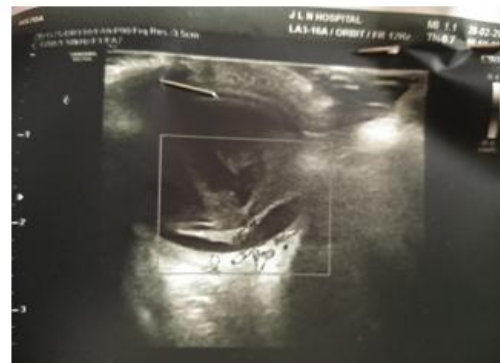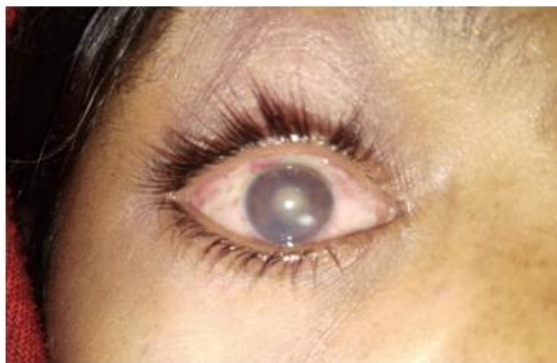Picture 1 and 2: Repaired corneal tear with anterior vitreous degeneration in B-scan.



Picture 3 and 4: Self sealed corneal tear with pseudophakic retinal detachment in B scan.



Picture 5 and 6: Penetrating cornea with endophthalmitis and vitreous membranes in B scan.



IV. Discussion

- Ocular trauma was more prevalent in children and young adults with male predominance; similar to other studies. [1,13,14]
- Initial visual acuity indirectly shows anatomic condition of globe during presentation, so it helps in explaining visual prognosis.[2-12]
- Type or mechanism of injury reflect the intensity of trauma and tissue injury indirectly, so it affect the prognosis. [2,3,5,10,11,12]
- Higher the zones of injury lower will be the visual gain. Extent of wound and size of open-globe injury as larger poorer the prognosis. Our study consistent with these findings.[2-11]
- Lens damage alone does not affect the final outcome much more because cataract extraction with IOL implantation associated with good prognosis. [2,3,5,10-12]
- Hyphema may invariably affect outcomes. [10,12]
- Posterior segment injuries (vitreous hemorrhage, retinal detachment, IOFB) are more visually devastating than anterior segment injury. Even adequate and timely treatment left the patients with permanent vision impairment after resolution. [2,3,5,10,12]
- Time lag between injury and surgery also adversely affects the final visual outcome. Issac et al [5] early intervention stands with more chances of better visual outcome compare to delayed where chances of substantial damage, inflammation and secondary infection more. Final visual acuity was significantly poor in eyes where the primary repair was delayed beyond 24 hours.

In our study most of patients were belonging to work /house hold or blunt object injuries, zone 1 injuries, less with posterior segment involvements and reported to casualty within 24 hours had good visual prognosis.

V. Conclusion

Predictors of final visual acuity in open globe injuries are -

- ❖ Initial visual acuity
- ❖ Type or mechanism of injury
- ❖ Zones of injury and; size and extent of tear
- ❖ Timing of presentation and timing of intervention
- ❖ Segmental involvement (anterior segment and/or posterior segment with additional involvements)

References

- [1]. Parver LM. Eye trauma: The neglected disorder (editorial). *Arch Ophthalmol* 1986;104:1452. Back to cited text no. 1
- [2]. Rupesh Agrawal1, Girish Rao2, Rishikesh Naigaonkar2, Xiaoling Ou1, Satish Desai2. Prognostic factors for vision outcome after surgical repair of open globe injuries. *Indian journal of Ophthalmology*. Year : 2011 | Volume : 59 | Issue : 6 | Page : 465-470
- [3]. De Juan EJ, Sternberg PJ, Michels RG. Penetrating ocular injuries: Types of injuries and visual results. *Ophthalmology* 1983;90:1318-22. Back to cited text no. 3
- [4]. Issac DL, Ghanem VC, Nascimento MA. Prognostic factors in open globe injuries. *Ophthalmologica* 2003;217:431-5. Back to cited text no. 5
- [5]. Pieramici DJ, Mathew W, MacCumber, Humayun MU. Open globe injury: Update on types of injuries and visual results. *Ophthalmology* 1996;103:1798-803. Back to cited text no. 8
- [6]. Leonardo D, Ghanem VC. Prognostic factors in open globe injuries. *Ophthalmologica* 2003;217:431-5. Back to cited text no. 10
- [7]. Rofail M, Lee GA, Rourke P. Prognostic factors for open globe injury. *Clin Exp Ophthalmol* 2006;34:783-6. Back to cited text no. 13
- [8]. Schmidt GW, Broman AT, Hindman HB, Grant MP. Vision survival after open globe injury predicted by classification and regression tree analysis. *Ophthalmology* 2008;115:202-9. Back to cited text no. 14
- [9]. Rahman I, Maino A, Devadason D, Leatherbarrow B. Open globe injuries: factors predictive of poor outcome. *Eye* 2006;20:1336-41. Back to cited text no. 15
- [10]. Rao LG, Ninan A, Rao KA. Descriptive study on ocular survival, visual outcome and prognostic factors in open globe injuries. *Indian J Ophthalmol* 2010;58:321-3. Back to cited text no. 19
- [11]. [PUBMED] Medknow Journal
- [12]. Gupta A, Srinivasan R, Babu KR, Setia S. Comparison of the clinical presentation and visual outcome in open globe injuries in adults and children over 30 months. *Eur J Ophthalmol* 2010;20:590-5. Back to cited text no. 20
- [13]. Shah M, Shah S, Khandekar R. Ocular injuries and visual status before and after their management in the tribal areas of western India: A historical cohort study. *Graefes Arch Clin Exp Ophthalmol* 2008;246:191-7. Back to cited text no. 21
- [14]. Dulal S, Ale JB, Sapkota YD. Profile of pediatric ocular trauma in mid western hilly region of Nepal. *Nepal J Ophthalmol* 2012;4:134-7. Back to cited text no. 7
- [15]. Al-Bdour MD, Azab MA. Childhood eye injuries in North Jordan. *Int Ophthalmol* 1998;22:269-73. Back to cited text no. 9

Dr. Shashidhar Harvyashi, etal. "Predicting factors in open globe injury." *IOSR Journal of Dental and Medical Sciences (IOSR-JDMS)*, 19(3), 2020, pp. 40-44.