

Pseudoexfoliation syndrome in cataract surgery: retrospective study about 84 cases

I. Chabbar¹, L. Serghini¹, A. Berraho¹

1 : Ophthalmology B, Specialty Hospital, Ibn-Sina University Hospital, Rabat, Morocco

*Corresponding Author: I. Chabbar

Summary:

Purpose: The purpose of this study is to analyze the epidemiological and clinical features of pseudoexfoliation syndrome and to determine cataract surgery complications in eyes with pseudoexfoliation syndrome.

Methods: we conducted a retrospective study concerning 84 cases among 790 patients scheduled for cataract surgery between September 2018 and December 2019.

Results: we found a prevalence of 10.63% which increases with age, a relative male predominance with a significant association with high intraocular pressure and poor pupillary dilation. Phacoemulsification is the surgical technique most used and peroperative complications are dominated by zonular rupture and capsular rupture with vitreous outcome.

Discussion: Pseudoexfoliation syndrome is defined as degenerative fibrilopathy related to age and whose etiopathogenesis is still unknown. The diagnosis of pseudoexfoliation syndrome is of paramount importance as this disease is a major risk factor for complications during cataract surgery because of the increased weakness of the zonular apparatus and limited pupil dilation.

Conclusion: Pseudoexfoliation syndrome should always be investigated in the preoperative assessment of cataract, especially in elderly patients with poor pupillary dilation.

Keywords: Pseudoexfoliation syndrome, cataractsurgery, complications

Date of Submission: 16-04-2020

Date of Acceptance: 01-05-2020

I. Introduction

Pseudoexfoliation syndrome has been discovered since 1917 by a young ophthalmologist describing white flaky deposits around the pupil and the anterior lens capsule [1]. It is defined as a degenerative systemic fibrilopathy related to age whose etiopathogenesis is still unknown. It is a multiorgan disease due to multifactorial disorder of the elastic fiber structure with abnormal deposition of pseudoexfoliative fibrillar material in several organs: liver, lung, meninges, heart, kidneys, and especially the anterior segment of eyes [2]. The diagnosis of pseudoexfoliation syndrome is clinical by objectifying whitish deposits on the anterior surface of the lens forming a roundel image. Among patients with pseudoexfoliation syndrome, 25% develop ocular hypertonia or chronic open angle glaucoma [3]. This syndrome leads to changes in ocular tissues and exposes to various complications: poor dilation, zonular fragility, phacodonesis, lens subluxation, endothelial damage, intraoperative zonular disinsertion, endothelial decompensation, postoperative inflammation, postoperative hypertonia, subluxation of the posterior chamber implant and secondary cataract [4].

The purpose of this study is to analyse the epidemiological and clinical features of pseudoexfoliation syndrome and to determine cataract surgery complications in eyes with pseudoexfoliation syndrome.

II. Methods

A retrospective study was conducted on 84 cases with pseudoexfoliation syndrome among 790 patients scheduled for cataract surgery between September 2018 and December 2019. All patients were examined with slit lamp before and after pharmacologic mydriasis. The diagnosis of pseudoexfoliation syndrome was clinical, defined by the deposition of white dandruff-like material, called pseudo-exfoliative material on the anterior capsule of the crystalline lens after dilation. We analyzed Demographic parameters (age, sex, medical and ophthalmologic history), ophthalmological examination features (visual acuity, pupil dilation, uni / bilateral, intraocular pressure) before surgery, and surgical complications of patients with pseudoexfoliation syndrome scheduled for cataract surgery by phacoemulsification or extracapsular extraction.

III. Results

Pseudoexfoliation syndrome in cataract surgery: retrospective study about 84 cases

Among the 790 patients operated for cataract, pseudoexfoliation syndrome is reported in 84 cases. The average age is 69 years. The sex ratio was 1.33, with 48 male and 36 female cases. 43 cases were diabetic and 52 cases were hypertensive.

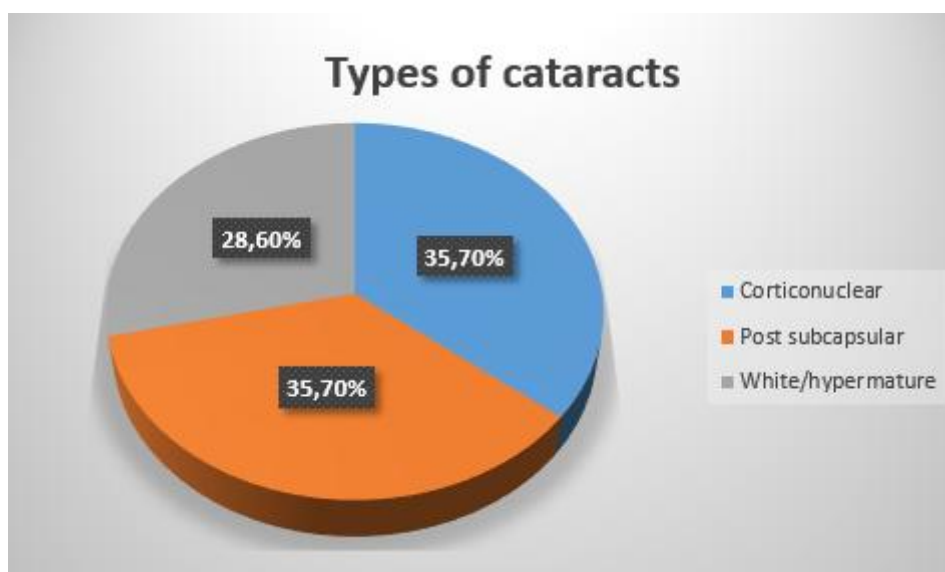
pseudoexfoliation syndrome prevalence	Average Age	Sex	Comorbidity
10,63%	69 years	male predominance (57,15%)	43 Diabetic (51.2%) 52 Hypertensive (61.9%)

There was a unilateral forms predominance with 50 cases compared to bilateral forms 34 and a right laterality was recorded. Regarding the average preoperative visual acuity, it was CLD 3m.

The average intraocular pressure, except glaucoma, was significantly higher in eyes with pseudoexfoliation syndrome to 17.4 mmHg, this elevation is due to trabecular blockage by exfoliative material and trabecular cell dysfunction. Poor pupillary dilation was observed in 30 cases.

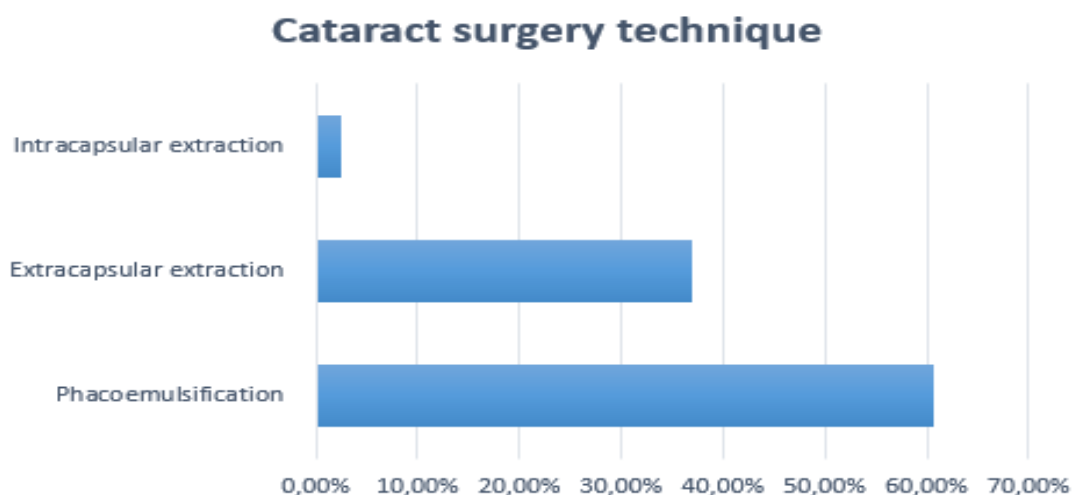
Ophthalmological examination features				
Preoperative visual acuity	Poor pupillary dilation	Average IOP	Phacodonesis	Subluxed cataract
counting fingers 3m	30 cases (35,7%)	17.4 mmHg	6 cases (7,14%)	2 cases (2,4%)

Corticonuclear and posterior subcapsular cataracts were predominant, followed by white cataracts. 2 cases of lens subluxation and 6 cases of phacodonesis was noted.



The phacoemulsification was performed in 51 eyes, extracapsular extraction in 31 eyes with posterior chamber intraocular lens, and intracapsular extraction in both cases of lens subluxation.

The iris retractors were used in 8 cases; otherwise the injection of viscoelastic devices or the intracameral adrenaline use were sufficient.



Surgical complications were represented by zonular rupture and capsular rupture with vitreous outcome, whereas postoperative complications are dominated by corneal edema and implant dislocation.

Complications	
peroperative	postoperative
Zonular desinsertion 5,95% Capsular rupture with vitreous issue 11,90%	Corneal edema 47,60% Implant dislocation 3,57%

IV. Discussion

Pseudoexfoliation syndrome is currently defined as an age-related disorder. The prevalence is increasing significantly beyond the age of 60. The studies carried out around the world show great variations; in South Africa the prevalence is estimated between 6% and 7.7% [5], in Tunisia it is 11% [6] and in Morocco a prevalence of 9.8% was reported in 2006 [7], lower than the value calculated in our series which is 10,63%. In our study, the average age of patients was 69 years with male predominance 57,15%. Several studies have found similar results, however, female cases are more affected in the Scandinavian countries and in Australia [8]. In our study, 34 cases are bilateral. according to the literature, pseudoexfoliation syndrome is a bilateral lesion, but with asymmetrical presentation and a long interval of bilateralization estimated at 10 years [9]. The clinical pseudoexfoliation syndrome is characterized by poorer visual acuity, higher IOP, poorer pupil dilation and more pigmented trabeculum [10]. Secondary open-angle glaucoma is a common complication [9,10]. In pseudoexfoliation syndrome cases, a significant association was shown with cardiovascular pathologies [11]. In our study, 43 cases were diabetic and 52 cases were hypertensive. Corticonuclear and posterior subcapsular cataracts represent the predominant type followed by white cataracts, these results do not agree with the literature where nuclear cataracts predominate [10]; this is probably due to the long consultation delay of our patients.

Poor pupillary dilation is commonly associated to pseudoexfoliation syndrome and exposes to preoperative difficulties. In fact, despite modern techniques of cataract surgery, pseudoexfoliation syndrome is considered as a risk factor for cataract surgery and represents a challenge for surgeons because of zonular weakness and limited pupil dilation. The risk of capsular rupture with vitreous loss and zonular rupture is very important [12]. A planned approach to cataract surgery using advanced techniques of phacoemulsification, specific ophthalmic viscoelastic devices, iris retractors and capsule support devices significantly reduces the risk of complications during surgery. Postoperative surveillance is required to monitor and treat postoperative intraocular pressure, anterior chamber inflammation and IOL decentration [12].

V. Conclusion

Our study presents epidemiological, clinical and therapeutic characteristics of 84 eyes with pseudoexfoliation syndrome scheduled for cataract surgery. This syndrome should be routinely investigated in the preoperative assessment of cataract and should be suspected in the presence of poor pupillary dilation. It

represents is a risk factor for open-angle primary glaucoma and it exposes to peroperative complications during cataract surgery, regardless of the technique used.

Conflict of Interest: The authors do not declare any conflict of interest.

References:

- [1]. Tarkkanen A., Kivelä T. John G. Lindberg and the discovery of exfoliation syndrome. *Acta Ophthalmol Scand.* 2002 ; 80:151-4.
- [2]. Ritch R. Exfoliation syndrome: more than meets the eye. *Acta Ophthalmol Scand.* 2002; 80:465-7.
- [3]. Ritch R, Schlotzer-Schrehardt U. Exfoliation syndrome. *Surv Ophthalmol*, 2001;45:265-315.
- [4]. Streho M, Rohart C, Chaine G Le syndrome de pseudo-exfoliation capsulaire dans la chirurgie de la cataracte. étude rétrospective de 37 cas *J Fr. Ophtalmol.*, 2008; 31, 1, 11-15 *J Fr. Ophtalmol.*, 2008 ; 31, 1, 11-15
- [5]. Rotchford A.P, Kirwan J.F, et coll, Exfoliation syndrome in black South Africans. *Arch Ophthalmol.* 2003 ;121:863-70.
- [6]. Ayed S, Ghorbel M, Nacef L. The exfoliation syndrome in Tunisia. *Tunis Med* 1990 ; 68: 19-22
- [7]. Benatiya Andaloussi I, Tahri H et coll. Le syndrome pseudo-exfoliatif Chez les patients marocains Programmes pour chirurgie de La cataracte, *Bull. Soc. belge Ophtalmol.*, 300, 57-64, 2006
- [8]. Buhrmann R, quigley H et Coll, Prevalence of glaucoma in a rural East African population. *Invest Ophthalmol vis Sci* 2000; 41: 40-48.
- [9]. Puska PM. unilateral exfoliation syndrome: conversion to bilateral exfoliation and to glaucoma: a prospective 10-year follow-up study. *J Glaucoma*, 2002;11: 517-24
- [10]. Schlotzer-Schrehardt u, Naumann GO. Ocular and systemic pseudoexfoliation syndrome. *Am J Ophthalmol*, 2006 ; 141:921-37.
- [11]. Holló G. Exfoliation syndrome and systemic cardiovascular diseases. *J Glaucoma.* 2014 ;23(8 Suppl 1):S9-11.
- [12]. Fontana, L., Coassin, M., Iovieno, A., Moramarco, A., & Cimino, L. Cataract surgery in patients with pseudoex-foliation syndrome: current updates. *Clinical Ophthalmology* 2017;11 1377–1383

I. Chabbar,etal. "Pseudoexfoliation syndrome in cataract surgery: retrospective study about 84 cases." *IOSR Journal of Dental and Medical Sciences (IOSR-JDMS)*, 19(4), 2020, pp. 25-28.