

## Quality of Life (QoL) and Patient Satisfaction during Extended Bracing Treatment – A Case Study

Devanshi M Dalal<sup>1</sup>, Dr. Mayank R Chikani<sup>2</sup> and Dr. Mahesh K Dalal<sup>3</sup>

<sup>1</sup>(B.Optom, Pursuing M.Optom., Nagar School of Optometry, Gujarat University, Ahmedabad, India)

<sup>2</sup>(B.D.S., Consultant, Hari Om Dental Clinic, Ahmedabad, India)

<sup>3</sup>(M.Sc.,Ph.D.,DIBM, Consultant in Chemical Processing and Industrial Management, Ph.D. Guide, Shri J.J.T.University, India)

### Abstract:

**Background:** Orthodontic treatment in teenagers is very common due to various advantages and enhanced life quality post treatment. In recent time various investigative tools are also commonly available to monitor effectiveness of ongoing treatment. However on extension of treatment duration due to some reasons, Quality of Life is severely impacted. The present case study discuss a case where orthodontic treatment was initiated at the age of 17 years. However, during the course of the treatment it was revealed that a milky tooth is retained. It was to be removed by laser treatment thus extending the duration of treatment. Finally a zirconia bridging was applied to successfully conclude the treatment.

**Materials and Methods:** Orthodontic treatment was initiated with OPG and x-ray. During the course of treatment, CBCT and X-ray were used. At the end of treatment Zirconia bridging was applied.

**Results:** Zirconia bridging was applied to successfully conclude extended duration orthodontic treatment. However Quality of Life was impacted adversely during extension of treatment. Patient satisfaction was achieved at the end of treatment.

**Conclusion:** Bracing treatment was successfully carried out involving longer duration then expected at the start. Successful treatment was achieved with bridging. However extended treatment duration affected QoL by impacting ocular, dental, psychological, hygiene and budgetary factors.

**Key Word:** Impacted Canine; Quality of Life; CBCT; Orthodontic Treatment; Bracing; Ocular Hazards.

Date of Submission: 04-04-2020

Date of Acceptance: 20-04-2020

### I. Introduction

Orthodontic treatment in school children has become popular worldwide owing to advancement in dental science. Braces can straighten teeth, line up jaws to give better bite and close gap in smile. However if tooth correction orthodontic treatment goes on for longer duration for any reasons, it affects quality of life.

Orthodontic treatment is not only necessary for cosmetic purpose. "Orthodontic treatment for prominent upper front teeth (class II Malocclusion) in children and adolescents" were studied by Klaus Bsl Batista et al and found that providing early orthodontic treatment for children with prominent upper front teeth is more effective for reducing the incidence of incisal trauma.<sup>1</sup>

Among the factor influencing bracing treatment a study by Salvatore Settineri et, al "Dental Aesthetics perception and eating behavior in Adolescence" showed increase in knowledge of psychological aspect involved in orthodontic treatment compliance may have positive effect on patient and practitioner relationship. This influences patient satisfaction along with dental health.<sup>2</sup>

Diang Jing et.al in their study "Effect of fixed orthodontic treatment on oral microbia and salivary proteins" found that S.mutans bacteria in patients with conventional braces increased significantly in late period of treatment and spot lesions may occur after long-term orthodontic treatment.<sup>3</sup>

Effects of dental treatment on the quality of life (QoL) and activities of daily living is interesting study. Effects of dental treatment on the quality of life and activities of daily living in institutionalized elderly in Japan was studied by Mariko Naito et al. Impairment of oral health has a negative impact on the quality of life of the elderly. Activities of daily living (ADL) are known to be an important determinant of their QoL. Findings showed that dental treatments increased the oral health-related QoL and the expression function in the ADL.<sup>4</sup>

Despite its relatively recent emergence over the past few decades, oral health-related quality of life (OHRQoL) has important implications for the clinical practice of dentistry and dental research. OHRQoL is an integral part of general health and well-being and is recognized by the WHO as an important segment of the Global Oral Health Program (WHO, 2003).<sup>5</sup>

Research papers mentioned above suggests various aspects of orthodontic treatment in relation to quality of life and patient satisfaction. However, there is no mention of QoL and patient satisfaction in case of extension of duration of treatment by any reasons. Studying QoL in student for elongated period of bracing treatment will be interesting to explore.

The present paper discuss such case study and co relation with ophthalmic/ optometric causes

## **II. Material And Methods**

**Study Design:** case study

**Study Location:** Ahmedabad, India

**Study Duration:** April 2015 to November 2019.

### **Procedure methodology**

Orthodontic treatment was initiated at the age of 17 years in the year 2015 with investigation by OPG and x-ray. During the course of treatment, retained tooth was found using CBCT. CBCT investigation was done in 2016 which revealed retained tooth and in 2019 post removal of retained tooth. Treatment was to be altered and extended from earlier duration and course foreseen. At the end Zirconia bridging was applied to successfully conclude the treatment.

## **III. Case Study**

A patient of 17 year (F) initiates orthodontic treatment with bracing required to be followed for couple of years. However, CBCT during treatment reveals that an impacted canine is not fully developed and needs to be laser operated to straighten. The procedure required repetition thrice and finally removal of teeth. A bridge was placed to finally complete treatment successfully after almost 5 years. Longer duration of treatment involved other issues like headache, changing myopic condition, lack of nutrition due to reduced food intake caused by braces related discomfort etc.

Case study involves a typical situation when after 3 years bracing treatment it was revealed that a milky tooth is retained. It was surgically removed and bracing was to be applied in place of implant. Thus bracing treatment went on for nearly 5 years instead of usual duration of 2 to 3 years.

Consulted an optometrist as:

c/o Frontal headache , increasing in evening , relieved with paracetamol/sleep ,Associated complaint eyestrain.

Past ocular history h/o glasses x 11 years

BE Visual acuity (with glasses) 6/6

Current glass prescription OD -4.25Ds OS -4.50 Ds BE vn 6/6 nearN6 @ 40 cm

Monocular estimation Method Retinoscopy : +0.50Ds

Cover test Distance Ortho for distance and near OM BE Full, Free, Painless

Anterior and posterior segment – BE WNL

BE Funus- WNL

Complaints were suggestive of accommodation or convergence anomalies but non strabismic binocular vision evaluation revealed accommodation and convergence parameters within normal limits.

Since No evidence of ocular pathology, optometrist adviced to continue with same glasses, review after six months. Refer to physician for systemic evaluation Physician Review – blood reports reveal decreased vitamin B12 level.

Physician review suggested that due to improper intake of food and lack of nutrients lead to complaint.

Dental review:

Figures shows CBCT in year 2016 and 2019. CBCT in 2016 shows impacted canine in upper right canine region which was difficult to diagnose in traditional OPG.

CBCT in 2019 taken after canine removal showed excessive tilting of neighboring teeth due to prolonged bracing treatment. Bone loss is diagnosed in neighboring premolar due to excessive tilting. Thus due to insufficient space and bone loss of tooth, implant cannot be preferred.

Fig. 1 and 2 (below) shows CBCT of 2016 at third year of treatment.

Fig. 3 and 4 (below) shows CBCT after 4 years of bracing treatment in 2019.

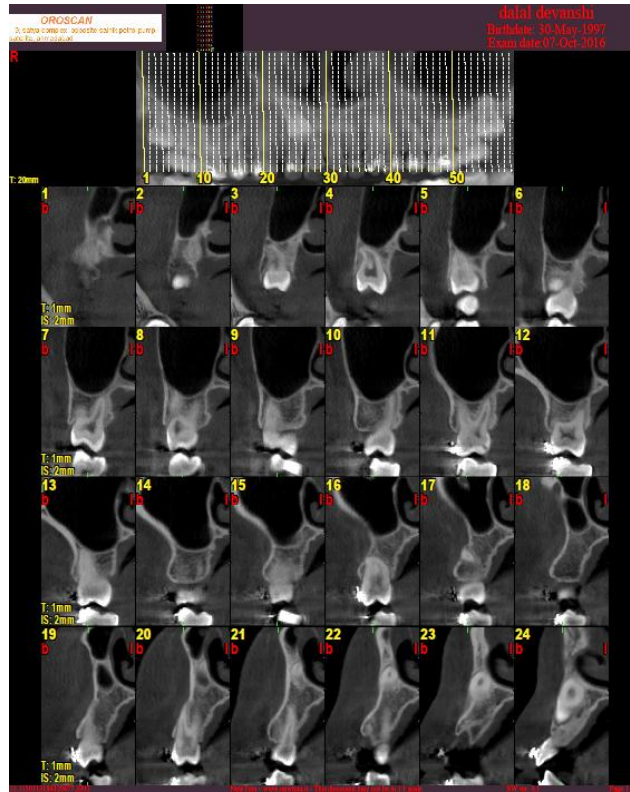


Figure 1

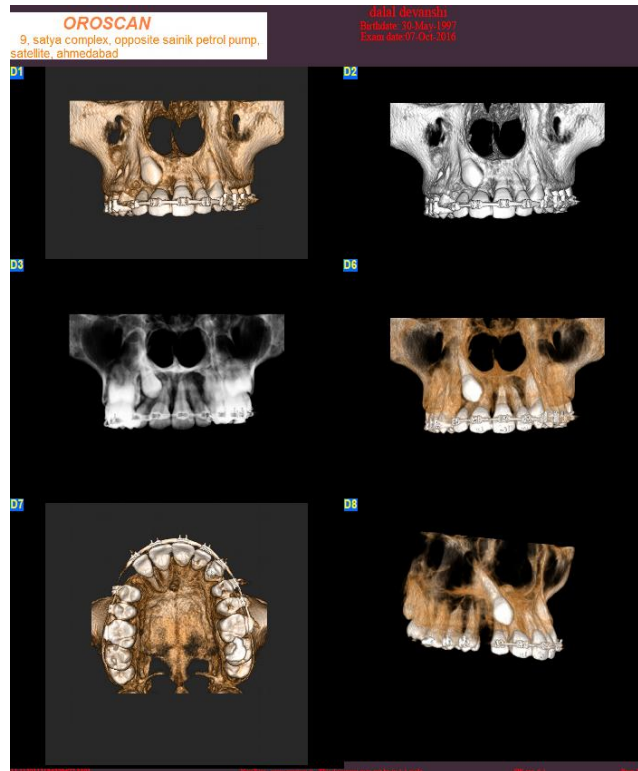


Figure 2

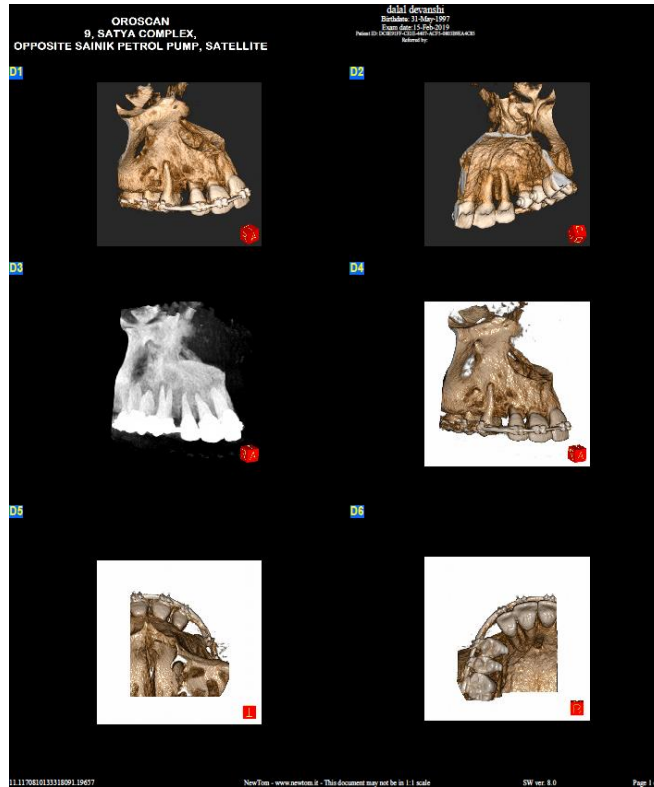


Figure 3

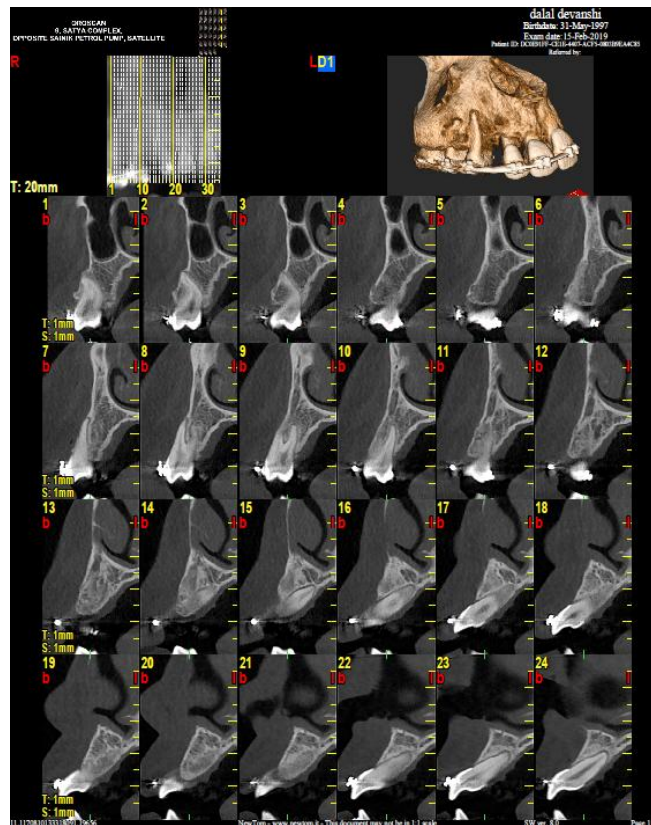


Figure 4

#### IV. Discussion

Mix of normal and retained teeth in dentition period leads to crowding in teeth. Present case discusses an elongated treatment duration resulted by late investigation of retained teeth due to lack of appropriate

investigative imaging techniques at start of treatment. Only OPG was commonly available tool in the centre of treatment at beginning of treatment and CBCT was uncommon.

3 D imaging in dental treatment by dental cone beam computed tomography (CBCT) is very handy tool during dental treatment to review treatment progress as and when required. However, it has become popular lately. In present case after couple of years of treatment, CBCT revealed that retained milky tooth is not falling in natural way. Lack of erupting forces and proper mastication might have withhold it partially and it was to be removed using laser techniques. Availability of better braces, scanning techniques, dental bridge materials and revolution in treatment in present day have resulted in reduction of pain to bear by patient. However, when treatment extend for longer duration, it affects quality of life. Possibility of future side effects can be eliminated by timely diagnosis.

**Dental Complications:** Complication due to missing canine, Bone resorption and lack of strength resulting in tilting of neighbouring teeth due to excessive force of longer duration braces. Implant is usual preference in case of gap in teeth but due to above reasons bridging was preferred over an implant. Gingivitis is common in longer duration oral treatment. Internal inflammation, altered food taste, psychological factors due to extended treatment, teenage to adulthood transformation, lack of proper food intake, improper digestion and increasing budget with time also plays havoc for patient. Oral hygiene is not properly maintained due to longer duration of bracing which leads to tooth decay at a later stage. Cosmetic aspects are to be taken care of in canine frontal gap hence zirconia is to be used in bridge increasing cost. Budgetary aspects also involves cost incurred on compulsory use of anti sensitive toothpaste, proper food, costly bridge material necessary to be chosen and longer duration of treatment. Psychology is also an important factor in prolonged treatment. It may lead to ignorance of initial symptoms of tooth decay like sensitivity and regular follow-up for dental checkup may be ignored leading to complications in root canal treatment. Even drop out rate or second/third opinion of dentist can occur due to psychological impact.

From the optometrist point of view

- The dental chair is the site of numerous potential ocular hazards. Ocular injuries may occur from mechanical trauma, chemical trauma, microbial infection or electromagnetic radiation damage. Although not all injuries can cause blindness, it may cause a low vision. These injuries can be prevented by proper use of protection.<sup>6</sup>

- It is said that eye is an window to systemic disease. There are many diseases in which ocular signs appear first before symptoms of disease are manifested. Vittorio et.al in their study “ The eye as a window to systemic infectious diseases: old enemies, new imagining” found that thorough ophthalmological evaluation with multimodal imaging approach can be beneficial in systemic pathologies.<sup>7</sup> It is found that variety of systemic diseases can adversely affect both static and dynamic aspects of accommodation. Anemia is one the common conditions in children as well as adults causing accommodative insufficiency<sup>8</sup>.

## V. Conclusion

Bracing treatment was successfully carried out but involving longer duration then forseen at start of treatment due to revelation of retained tooth during treatment not investigated by commonly available scanning (OPG) in the treatment centre at start of the treatment. Popularization of CBCT during treatment revealed retained teeth and treatment was to be suitably altered. Timely diagnosis of retained tooth saved from future side effects of impacted canine. However, longer duration treatment was at the cost of comfort, convenience and at higher cost. Patient satisfaction is achieved at the end of the treatment after affecting quality of life adversely during extended treatment duration. Ocular factor is also important apart from dental, psychological, budget, hygiene etc. factors in such case.

## Acknowledgement

Dr. Shayoni Patel is acknowledged for the regular discussions and guidance during course of the treatment. Dr. Aloe Gupta is acknowledged for optometry related guidance. Dr. Varun Shah is acknowledged for dental treatment related guidance. Dr. S.C.Modi is acknowledged for guidance as Physician. Dr. Suresh Ludhwani is acknowledged for CBCT and images.

## References

- [1]. Klaus Bsl Batista et.al,Orthodontic treatment for prominent upper front teeth (class II Malocclusion) in children and adolescents:Cochrane Database Syst Rev, 2018, PMID: 29534303.
- [2]. Salvatore Settineri et, al ,Dental Aesthetics perception and eating behavior in Adolescence: Int J Adolesc Med Health, 27 (3),311-7: PMID:25720040, DOI:10.1515/ijamh-2014-0031.
- [3]. Diang Jing et.al :Effect of fixed orthodontic treatment on oral microbia and salivary proteins: Exp. Ther Med. 17 (5),4237-4243, PMID: 30988796:DOI: 10.3892/etm.2019.7401.
- [4]. Mariko Naito wt.al :Effects of dental treatment on the quality of life and activities of daily living in institutionalized elderly in Japan: Arch Gerontol Geriatr,50(1),65-8: PMID: 19261341, DOI: 10.1016/j.archger.2009.01.013.

*Quality of Life (QoL) and Patient Satisfaction during Extended Bracing Treatment – A Case Study*

---

- [5]. L Sischo et.al, Oral Health-related quality of life: what ,why , how, and future implications, J Dent Res, 90 (11), 1264-70: PMID : 21422477, DOI: 10.1177/002203451139918.
- [6]. Donald G. Pitts et.al, Environmental vision interactions of the eye vision and environment ,pg 373-374.
- [7]. Vittorio Pirani et.al, The eye as a window to systemic infectious diseases: old anemies, new imaging, J Clin Med, 8(9), PMID: 31492008, DOI: 10.3390/jcm8091392.
- [8]. William J. Benjamin, Borish's clinical refraction, second edition, pg 116.

Devanshi M Dalal. "Quality of Life (QoL) and Patient Satisfaction during Extended Bracing Treatment – A Case Study." *IOSR Journal of Dental and Medical Sciences (IOSR-JDMS)*, 19(4), 2020, pp. 20-25.