

Management of Crown Dilaceration Using Natural Tooth Pontic: A Case Report

Saumil Mogre, Ishika Garg, Tanu Rajain, Ritu Namdev

¹(MDS, Department of Pedodontics and Preventive Dentistry, Post Graduate Institute of Dental Sciences, Rohtak, Haryana, India)

²(Post Graduate Trainee 2nd year, Department of Pedodontics and Preventive Dentistry, Post Graduate Institute of Dental Sciences, Rohtak, Haryana, India)

³(Post Graduate Trainee 2nd year, Department of Pedodontics and Preventive Dentistry, Post Graduate Institute of Dental Sciences, Rohtak, Haryana, India)

⁴(Senior Professor & Head, Department of Pedodontics and Preventive Dentistry, Post Graduate Institute of Dental Sciences, Rohtak, Haryana, India)

Abstract: Dilaceration of permanent teeth usually is a consequence of traumatic injuries to the primary teeth. Although it may appear anywhere along the long axis of the tooth, i.e., crown, cemento-enamel junction, or root, most often the root is involved. Crown dilacerations, however, is a rare condition representing 3% of the total injuries. The presence of such teeth in the aesthetic zone is often distressing for the patient, socially and psychologically, thereby seeking early intervention. This article describes the immediate replacement of a dilacerated permanent mandibular left central incisor using a fiber-composite resin splint (FRC-Ribbon) with the natural tooth crown as pontic following surgical extraction of the dilacerated tooth.

Key Words: Dilaceration, Natural Tooth Pontic, FRC-Ribbon.

Date of Submission: 20-05-2020

Date of Acceptance: 06-06-2020

I. Introduction

The term “dilaceration” was first coined by Tomes in 1848, who defined the phenomenon as the forcible separation of the cap of the developed dentin from the pulp in which the development of the dentin is still progressing.¹ Dilaceration is an abnormal angulation or bend in the root and less frequently, the crown of a tooth.² It is a rare disturbance in traumatised permanent teeth, which constitutes about 3% of the injuries to developing teeth. It usually occurs as a result of trauma to the deciduous predecessors and results in non axial displacement of the already formed hard tissue portion of the developing crown.³

Dilaceration usually involves the maxillary incisors and less frequently, the mandibular incisors, since the maxillary incisors are in close contact with their primary predecessors and are prone to injury. Crown dilaceration of the permanent maxillary incisors usually presents with palatal angulation, while that of the permanent mandibular incisors usually presents with a labial angulation.⁴

This ectopic eruption of the affected tooth seems to have a definite effect on the function and aesthetics. A malformed tooth in the aesthetic zone can be psychologically and socially damaging to the patient.⁵ The restoration of aesthetics is often a diagnostic, management and prognostic challenge to the clinician.

Suggested treatment options include extraction of the affected permanent tooth followed by replacement of a single tooth by adhesive splint using a natural tooth pontic, denture tooth, or composite resin tooth pontic embedded in reinforced composite fiber, wire, and metal or nylon mesh.⁶

The present case report describes aesthetic and restorative treatment of a permanent mandibular left central incisor with crown-root dilaceration using a fiber-composite resin splint with the natural tooth crown as pontic following surgical extraction of the concerned tooth.

II. Case Report

A 12 year old male autistic patient reported to the Department of Pediatric Dentistry, at Post Graduate Institute of Dental Sciences, Rohtak with the chief complaint of impingement of lower lip due to malformed lower left front tooth and wanted extraction of the same. Intra-oral examination revealed angulation with respect to crown portion of lower left permanent central incisor in labial direction suggestive of dilaceration (Figure 1 (a) and (b): Pre-operative view showing dilacerated crown of left mandibular central incisor). The past dental history of the patient revealed excessive gagging and vomiting during radiographic procedure in the previous

appointment. As a result radiographic image of the concerned tooth could not be obtained and the treatment was proceeded relying solely on the basis of clinical examination.

Considering the parent's concern about aesthetics and age of the patient, extraction of the dilacerated incisor was planned followed by fabrication of a Fiber Reinforced Composite (FRC-RIBBOND) using the same tooth. The tooth was extracted and placed in saline. On observation, crown appeared to be severely dilacerated. (Figure 2 (a) and (b): Dilacerated tooth after extraction). The root of the extracted tooth was resected at the cemento-enamel junction using a straight fissure bur. Pulpal remnants were extirpated, the pulp chamber was irrigated with saline, and the access was sealed with composite resin. (Figures 3: Access cavity prepared on the crown, Figure 4: Sealing of the access cavity with composite resin).

A horizontal groove was made in the middle third of the lingual aspect of the crown to a depth of nearly two mm in order to accommodate the thickness and width of FRC. The adequate length of the Ribbond fiber was measured using a dental floss. Lingual surface of the extracted and adjacent teeth were etched with 37% phosphoric acid for 15 seconds, and then thoroughly cleaned and dried. The fiber was soaked in bonding agent and adapted onto the lingual surface of the extracted tooth ensuring adequate fit into the groove and was light cured from multiple directions for 20 seconds. ((Figure 5 (a) and (b): Final prepared crown with attached Ribbond fiber). The Ribbond fiber adapted on the extracted crown was then positioned in its space and adapted to the adjacent teeth.

After confirming the correct position, the remaining fiber was coated with composite and light cured. (Figure 6 (a) and (b): Immediate post operative view). Subsequently, the occlusion was checked and finishing and polishing was performed. The final position of the tooth was confirmed radiographically. The patient was motivated to maintain good oral hygiene and regular follow ups. One year follow up revealed satisfactory functional and aesthetic results. (Figure 7: Post operative view after one year follow up).

III. Discussion

Dilaceration is a relatively rare condition. Crown dilacerations of permanent teeth is usually a consequence of intrusive luxation or avulsion of their primary predecessors. The level of dilaceration usually depends on the stage of development of affected tooth at the time of injury.⁵

The case report here presented with a severe dilaceration of crown portion of lower left permanent mandibular central incisor. Recovery of function and aesthetics deemed early treatment necessary.

The affected dilacerated tooth was extracted followed by using the natural tooth crown as pontic with fiber composite resin splint. Biologic restoration provides several advantages such as desirable aesthetics, optimum pontic shape, size and alignment. Besides, it provides better gingival health, greater patient-parent satisfaction and tolerance to the effects of tooth loss.⁷

The natural tooth pontic (NTP) technique is commonly opted for and highly appreciated by the patients for being a single visit technique, not involving any waiting period and temporization. Moreover, preparation of the neighbouring teeth can be avoided and it is highly cost-effective. Another major advantage of retaining the patient's natural crown is that the patient can better tolerate the effect of tooth loss psychologically.

In certain clinical scenarios, using an intact natural tooth which is in good clinical condition as pontic could offer benefits such as excellent color, shape, and size match, positive psychological value, minimal cost, and minimum chair side time with no laboratory procedure involved.

Natural tooth pontic (NTP) suitably modified and bonded to adjacent teeth enables proper healing in the area without compromising the anterior aesthetic demands of the patient.

Ribbond was selected in this case, as it is an ultrahigh molecular weight polyethylene fiber having virtually no memory; hence, it adapts to the contours of the teeth and dental arch. It is translucent, practically colorless and disappears within the composite or acrylic without show thereby offering excellent aesthetics. Key factors that influence the physical properties of fiber reinforced structures are fiber loading within the restoration and efficacy of the bond at the fiber resin interface, fiber orientation and fiber position in the restoration.⁸ Care should be taken to prevent exposing the moist Ribbond (with unfilled resin) to light as it would lead to initial polymerization, which would interfere with its manipulation and bond strength.⁹

Overall, the technique is practical, economically feasible, requires limited laboratory support and materials, and can be accomplished in a single appointment.

IV. Conclusion

Dilacerations, though rare, pose as a diagnostic, clinical and prognostic challenge to the clinician. The management of permanent crown dilacerations using natural tooth crown as pontic by attaching it to the adjacent teeth with acid-etch bonded resin presents effective method for managing dilacerations. This technique provides a practical and aesthetic immediate fixed tooth replacement that requires minimum materials and time.

References

- [1]. Walia PS, Rohilla AK, Choudhary S, Kaur R. Review of Dilaceration of Maxillary Central Incisor: A Multidisciplinary Challenge. *Int J Clin Pediatr Dent* 2016;9(1):90-98.
- [2]. Nabavizadeh MR., Sedigh Shamsi M., Moazami F., Abbaszadegan A. Prevalence of Root Dilaceration in Adult Patients Referred to Shiraz Dental School (2005-2010). *J Dent Shiraz Univ Med Sci.*, Dec. 2013;14(4):160-64.
- [3]. Allwani V, Pawar M, Pawar A, Abrar S, Ambhore S. Permanent Maxillary Central Incisor with Dilacerated Crown and Root and C-Shaped Root Canal. *J Clin Diagn Res.* July 2017;11(7):ZD03–ZD05.
- [4]. Prabhakar AR, Reddy VV, Bassappa N. Duplication and dilaceration of a crown with hypercementosis of the root following trauma: a case report. *Quint Int* 1998;29:655-57.
- [5]. Achary RC, Ravi GR. A Novel approach of Esthetic Management and preserving Vitality of Dilacerated Permanent Maxillary Lateral Incisor. *Int J Clin Pediatr Dent* 2016;9(2):152-55.
- [6]. Tayab T, Vizhi K, Srinivasan I. (2011). Space maintainer using fiber-reinforced composite and natural tooth -a noninvasive technique. *Dent Traumatol*, 27,159-62.
- [7]. Kumar A, Rana M, Hooda A, Dutta S, Goel M, Dahiya A, Kumar V. Crown dilaceration and root resorption of a permanent mandibular central incisor following injury to predecessor. *Int J Adv In Case Reports* 2015;2(13):808-10.
- [8]. Ganesh M, Tandon S. Versatility of Ribbond in contemporary dental practice trends biomater. *Artif Organs* 2006;20:53-8.
- [9]. Eminkahyagil N, Erkut S. An innovative approach to chairside provisional replacement of an extracted anterior tooth: use of fibre-reinforced ribbon-composites and a natural tooth. *J Prosthodont* 2006;15:316-20.

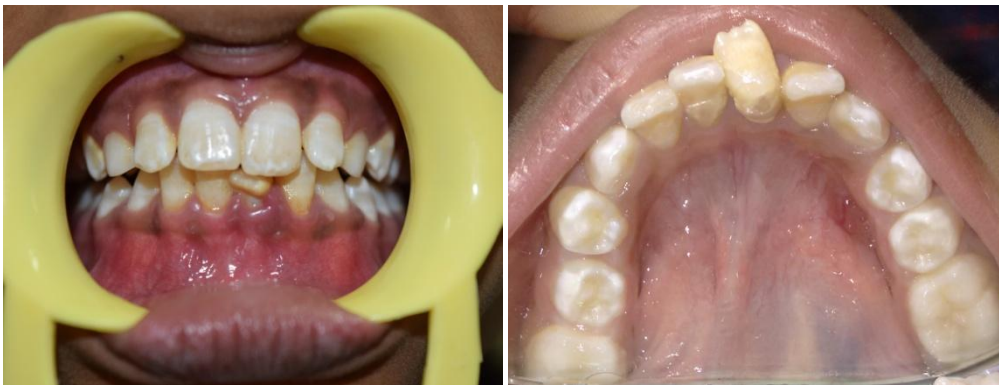

Figure 1 (a) and (b): Pre-operative view showing dilacerated crown of left mandibular central incisor.

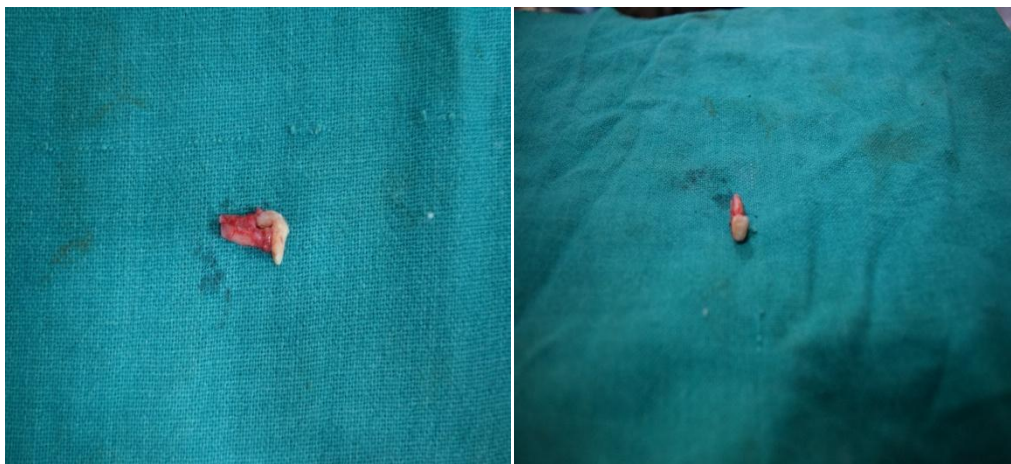

Figure 2 (a) and (b): Dilacerated tooth after extraction.

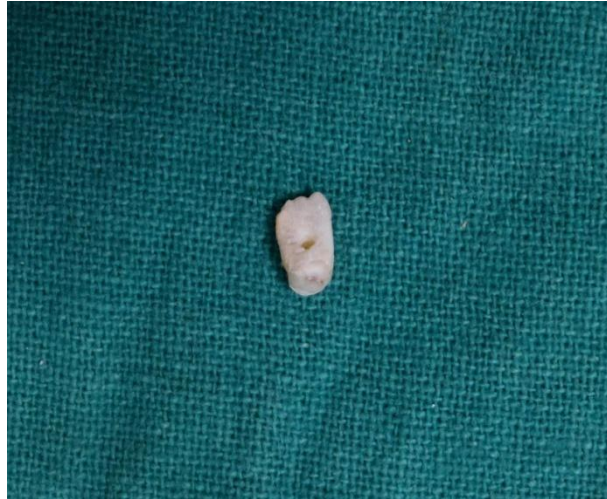

Figure 3: Access cavity prepared on the crown.

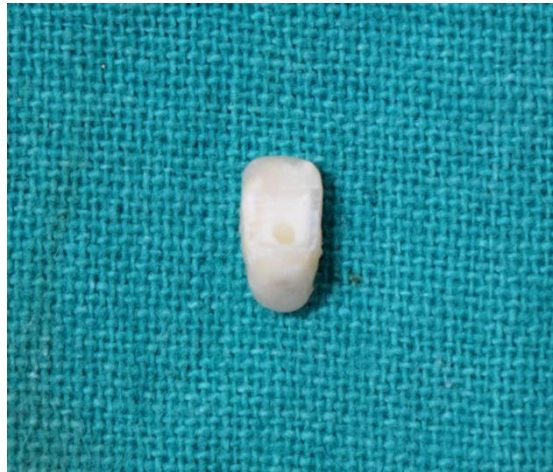


Figure 4: Sealing of the access cavity with composite resin.

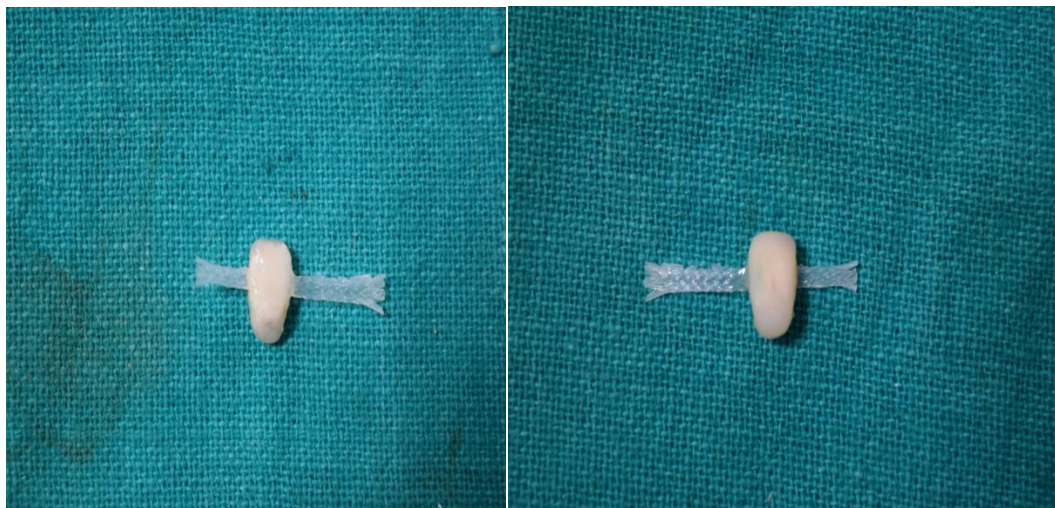


Figure 5 (a) and (b): Final prepared crown with attached Ribbond fiber.

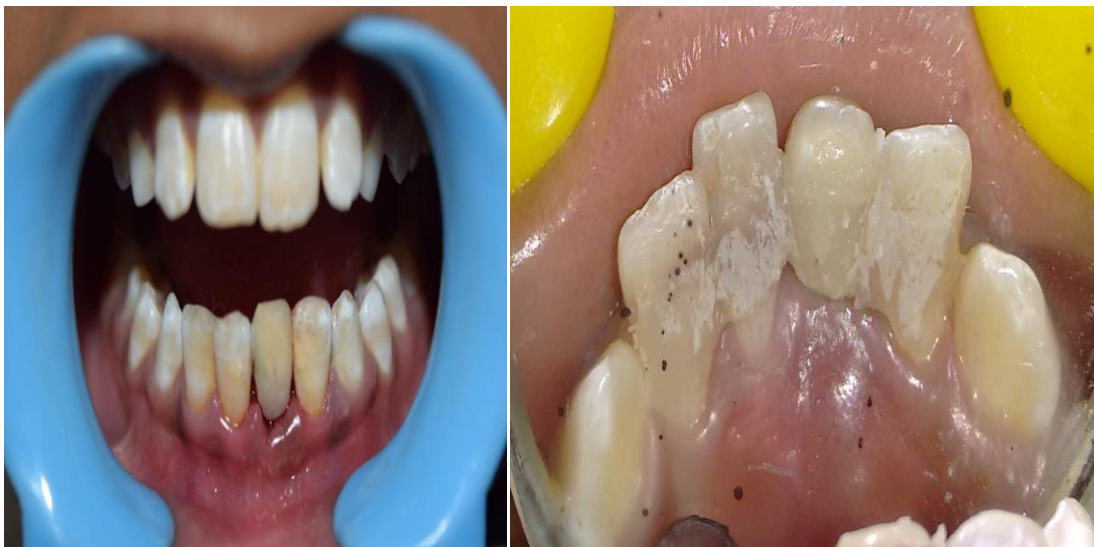

Figure 6 (a) and (b): Immediate post operative view.

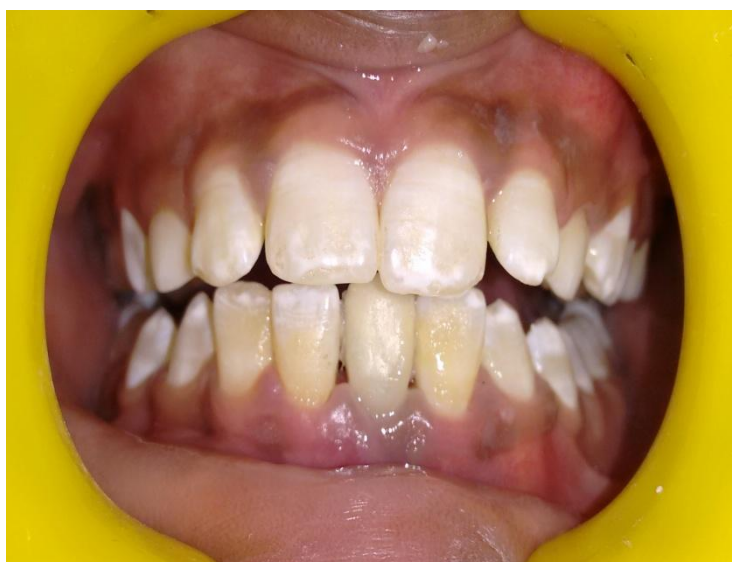

Figure 7: Post operative view after 1 year follow up.

Saumil Mogre, et. al. "Management of Crown Dilaceration Using Natural Tooth Pontic: A Case Report." *IOSR Journal of Dental and Medical Sciences (IOSR-JDMS)*, 19(6), 2020, pp. 28-32.